

Original Research Article

A clinical study of undescended testes

Nawaz A. Shariff^{1*}, Ashraf M. S. Ahmad²

¹Department of General Surgery, Sri Devaraj Urs Academy of Higher Education and Research, Tamaka, Kolar, Karnataka, India

²Department of General Surgery, Yenepoya Medial College, Derelekatte, Mangalore, Karnataka, India

Received: 11 October 2019

Revised: 20 November 2019

Accepted: 03 December 2019

*Correspondence:

Dr. Nawaz A. Shariff,

E-mail: drnawaz08.ns@gmail.com

Copyright: © the author(s), publisher and licensee Medip Academy. This is an open-access article distributed under the terms of the Creative Commons Attribution Non-Commercial License, which permits unrestricted non-commercial use, distribution, and reproduction in any medium, provided the original work is properly cited.

ABSTRACT

Background: The aim of the present study was to study the clinical presentation of undescended testis (UDT) as regards to age, position, side and study the management on UDT.

Methods: Total 41 patients, 50 UDT cases were studied prospectively. Patients below the age of 15 years with history of absent testes in the scrotum were included in the study and patients with retractile testes were excluded. Patients were subjected for ultrasonography (USG) scrotum. Palpable UDT and those were located on USG were subjected for open or laparoscopic assisted orchiopexy or 2 stage Stephen-Flower orchidopexy or orchidectomy.

Results: 41.4% patients were between age group of 1 to 5 yrs. 43.9% patients were having right sided UDT. 76% testes were palpable only. 21.9% were having bilateral UDT. 48% testes were present in inguinal canal. In 80% patient's orchiopexy was done. One patient (2.4%) had postoperative wound infection.

Conclusions: In our study the maximum number of cases were recorded between 1 to 5 years of age. Right sided UDT were common presentation. Maximum UDT were palpable. We also concluded that USG remains the specific non-invasive modality of diagnosis and localization. Almost half of them were present in the inguinal canal. Orchidopexy is the most common technique for placement of UDT in the scrotum. There were low complications and high success rate in treating UDT. We concluded that there is need of coordinated campaign between surgeons, pediatricians, general practitioners and community workers for timely intervention of UDT and advice for early approach for treatment.

Keywords: UDT, Orchiopexy, USG

INTRODUCTION

Since ancient times, it has been recognized that the testes need to be fully descended in the scrotum for normal functioning. indeed, the testes derives the name from the Latin word "witness", following the custom in the roman times to hold the testis when taking an oath. Hence, one of the primary concerns of paediatric surgeon and urologist has been the development of surgical procedures to place an undescended testis (UDT) into the scrotum. With the advent of paediatric surgery as an independent speciality, surgeons have taken a greater

interest in the surgery of children and its outcome. This has led to rapid change in attitudes to long term outcomes: not that long ago success of surgery was measured by such crude criteria as cosmetic result or survival, which could be determined immediately. However, now the profession and the community require and expect much higher standard, such that now the yardstick for success in the management of UDT is normal fertility and a low risk of malignancy in adult life. Community attitudes and information about long term outcomes are about accumulating at a rapid rate, as evidence by the fact that standard texts only 25 year ago

did not contain any significant information about long term malignancy risks.

Cryptorchidism is a condition in which one testis or both testes fail to descend into the scrotum before birth. Up to 30% of preterm infants can present with an UDT, but it also occurs in approximately 3% of full-term infants. Some UDT eventually descend by 1 year of age, but they are unlikely to descend after this time. UDT is one of the most common congenital abnormalities of the genitourinary system in young boys. Approximately 1-2% of boys at the age of 1 year have a UDT, the disorder being unilateral in about 90% of cases and bilateral in about 10%, depending on the clinical series. About 20% of UDTs are non-palpable. The testis can be located in the abdomen in some boys, but it might have been pushed into the upper inguinal canal: this disorder is termed 'peeping testis'. In about half of the cases of non-palpable testis (NPT), a testis is located in the abdominal cavity; the remainder are atrophic, either secondary to an antenatal torsion *in utero* or agenesis.

The UDT is associated with histologic and morphologic changes as early as 6 months of age; atrophy of Leydig cells, decrease in tubular diameter, and impaired spermatogenesis can occur by 2 years of age. An UDT has had its descent halted somewhere along the path of normal descent and is most commonly located in the inguinal canal.

Ectopic testes have had an aberrant path of descent; these can be found in perineal, femoral canal, and suprapubic regions. For a unilateral palpable testis in the inguinal canal, standard dartos pouch orchidopexy is performed. The recommended timing for this procedure is 6 months to 1 year of age. When an UDT is not palpable in the inguinal canal, a diagnostic laparoscopy is useful. If the testicular vessels are seen exiting the internal ring, an open inguinal orchidopexy is performed. For an intra-abdominal testis, a two-stage Fowler-Stephens orchidopexy can be considered, in which testicular vessels are ligated as a first stage to allow collateral circulation to develop for 6 months before orchidopexy is performed as a second stage of the procedure. However, single-stage laparoscopic orchidopexy is also an ideal option for intraabdominal testes.

Despite 15 years of international research on the topic, there are no guidelines on the management of boys with NPT. The management of boys with this disorder is still controversial, and in this study we also aim to summarize how best to manage NPT.

Several diagnostic modalities have been advocated for the assessment and diagnosis of NPT, such as CT or MRI, but only ultrasonography (USG) and laparoscopy have been adopted into routine practice. Although USG is simple, non-invasive and readily available in every district hospital, its use as a test to ascertain the presence or absence of an intra-abdominal testis is extremely

controversial because intestinal loops full of gas represent a barrier for ultrasound.

The objective of a clinical study of UDT conducted in our hospital were to study the clinical presentation of UDT as regards to age, position, side and study the management on UDT.

METHODS

A prospective study was conducted to study the clinical presentation of UDT with regards to age, position and side, and management of UDT. Patients admitted during the period of October 2015 to October 2017 with UDT in age group below 15 years in surgery department of Yenepoya Medical College at Mangalore were included in the study. Children with retractile testes were excluded. Analysis of results based on prevalence, sample size of 41 cases is decided with sample proportion of 0.7. Ethical clearance was obtained from ethical committee of Yenepoya University.

After detailed history and complete general and systemic examination and local examination of genitalia and scrotum, diagnosis of UDT was done. After detailed clinical examination patients were subjected for USG of scrotum and inguinal canal to know the location and size of testes. Along with USG of scrotum patient were subjected to various routine investigations like haemogram, liver function test, kidney function tests blood sugar, urine analysis to know the condition of patient and feasibility of surgery.

Patients having palpable unilateral UDT were subjected to orchiopey directly, patients having impalpable unilateral or bilateral testes were thoroughly examined by described clinical method of palpation and evaluated by USG to locate the testes and if the testes located in inguinal canal, orchiopey was done. In patients where testes was not located by USG. If testes were not located under anaesthesia patients were subjected for diagnostic laparoscopy and appropriate surgical procedure was done.

RESULTS

Total 41 patients, 50 UDT cases were studied prospectively. In this study maximum number of cases were in the age group 1 to 5 years i.e., 17 (41.4%), then followed by 5 to 10 years were eleven (26.8%), 10 to 15 years were seven (17%) and less than 1 year were 6 (14.6%) (Table 1). Among 41 cases, 18 (43.9 %) cases presented as right sided UDT, 14 cases (34.1%) cases presented as left side UDT and 9 case (21.9%) as bilateral UDT (Figure 1).

Out of 41 patients, 32 (78.1%) patients presented as absence of testes in scrotum, 3 (7.3%) patients presented as pain in inguinal region, 6 (14.6%) patients presented as swelling in inguinal region at the time of admission

(Figure 2). Maximum cases presented as palpable testes i.e., 38 (76%) and non-palpable testes were 12 (24%) (Table 2).

Table 1: Age distribution in patients of undescended testes (n=41).

Age (in years)	No. of patients	%
Less than 1	6	14.6
1-5	17	41.4
5-10	11	26.8
10-15	7	17

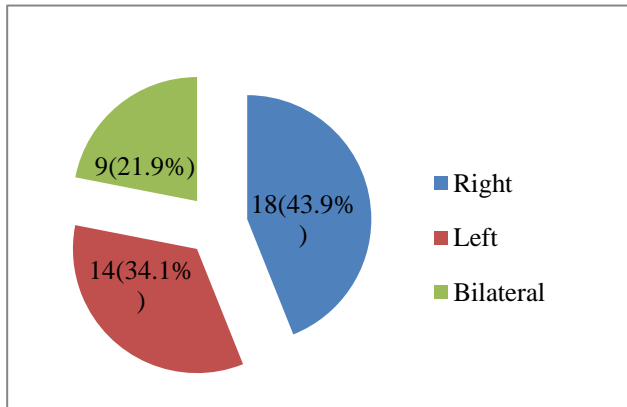


Figure 1: Side of UDT.

Table 2: Presentation on local examination.

Presentation	No. of testes	%
Palpable	38	76
Non palpable	12	24
Total	50	100

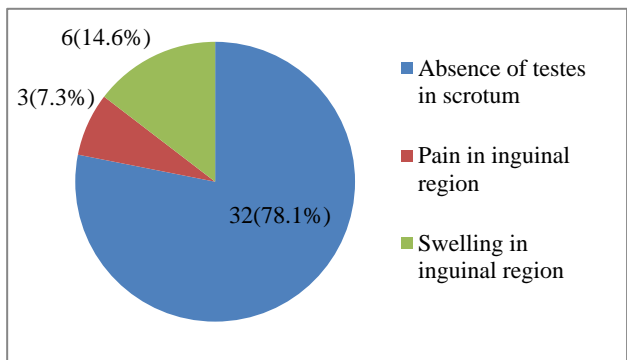


Figure 2: Chief complaints.

Out of 50 UDT, 24 (48%) were located in Inguinal canal, ten (20%) were located at superficial ring, 10 (20%) were at deep ring and six (12%) were intra-abdominal (Figure 3). Out of fifty UDT that were included in present study, 40 (80%) were subjected to orchidopexy, 4 (8%) underwent laparoscopic orchidopexy, five (10%) underwent laparoscopic 2 stage Stephen-Flower orchidopexy and one (2%) underwent orchidectomy (Table 3).

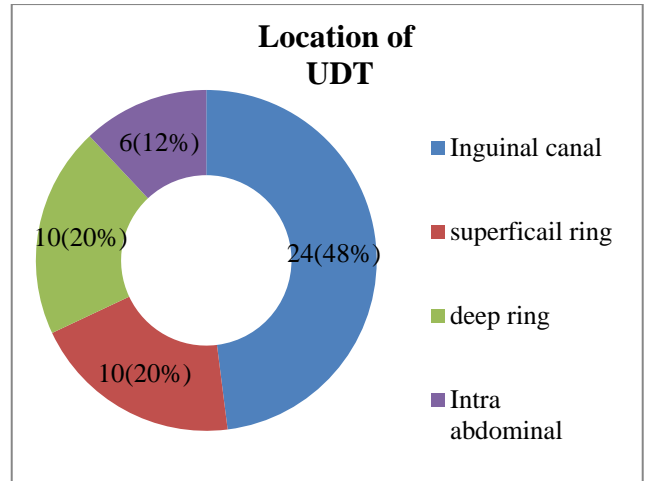


Figure 3: Ultrasound findings.

Table 3: Surgical procedure for UDT.

Surgery	No	%
Orchidopexy	40	80
Laparoscopic 2 stage Stephen-Flower orchidopexy	5	10
Laparoscopic orchidopexy	4	8
Orchidectomy	1	2
Total	50	100

Out of 50 UDT, 15 testes (30%) are at inguinal canal, 4 (8%) are at posterior abdominal wall, 12 (24%) are at deep ring, 17 (34%) are at superficial inguinal pouch and two (4%) are intraperitoneal (Figure 4). Out of 41 patients, seizure disorders were found in 2 cases. Hypospadias is mental retardation, cleft lip, developmental delay and inguinal hernia was found in 1 case each (Table 4). Out of 41 patients, 1 (2.4%) had wound infection.

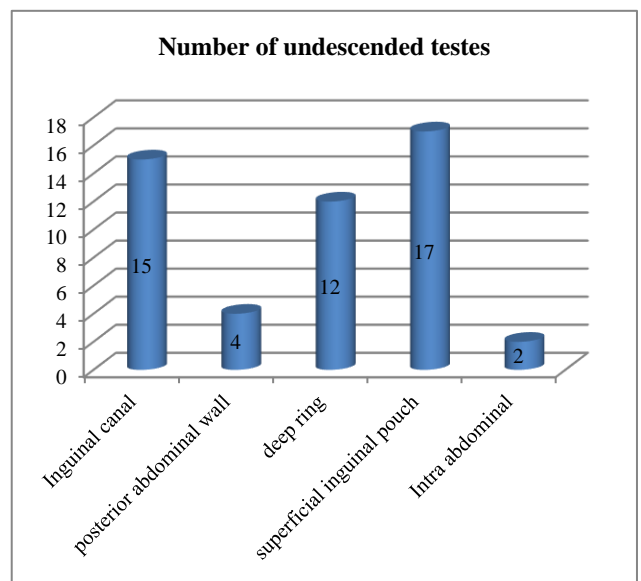


Figure 4: Intraoperative finding.

Table 4: Anomalies.

Anomalies	No. of patients	%
Hypospadiasis	1	2.4
Mentally retard	1	2.4
Seizure disorder	2	4.8
Cleft lip	1	2.4
Developmental delay	1	2.4
Inguinal hernia	1	2.4

DISCUSSION

In the present study maximum number of cases were in the age group 1 to 5 years i.e., seventeen (41.4%), then followed by 5 to 10 years were eleven (26.8%), 10 to 15 years were seven (17 %) and less than 1 year were six (14.6 %). Agrawal et al. did a study, in which 72% patients were between age group of 5 to 15 yrs.¹ Jadhav et al conducted a study among 34 cases, no patients presented between 0 to 6 months of age, sixteen (47.5%) cases between 6 months to 2 years of age, eleven (32.5%) between 2 to 5 years of age, seven (20%) cases between 5 to 15 years of age.² Kokorowski et al did a study among 28,204 children who underwent orchidopexy at PHIS Hospitals. Only 5031 patients (18%) underwent orchidopexy by the age of 1 year; only 12,165 (43%) underwent orchidopexy by the age of 2 years.³ In Shiryazd et al study the mean age at referral was 5.34 years. Only 44 (30.8%) cases were operated on before the age of 18 months. The most common reasons of delay in treatment were absence of early diagnose (42.5%), parent's unawareness of surgery necessity and its complications associated (33.7%) and parent's disregard (23.5%).⁴ Khalid et al in his study found that the mean age at orchidopexy in cohort was approximately four and half years old.⁵ Sinha et al did a retrospective review of 298 testes to assess delayed diagnosis for UDT and found mean age at referral was 57 months only 24% of cases were operated below 2 years.⁶

In the present study among 41 cases, 18 (43.9%) cases presented as right sided UDT, 14 cases (34.1%) cases presented as left side UDT and 9 case (21.9%) as bilateral UDT. In Agrawal et al study 48.8% patients were having right sided UDT.¹ In Jadhav et al study among 34 cases, 17 (50%) cases of right sided UDT, 11 (32.5%) cases of left sided UDT and 6 (17.5%) cases of bilateral UDT.²

In the present study out of 41 patients, 32 (78.1%) patients presented as absence of testes in scrotum, 3 (7.3%) patients presented as pain in inguinal region, 6 (14.6%) patients presented as swelling in inguinal region at the time of admission.

In the present study among 41 patients, maximum cases presented as palpable testes i.e., 38 (76%) and non-palpable testes were 12 (24%). In Agrawal et al study 89.8% testes were palpable.¹ Jadhav et al study among 34 cases, 21 (62%) patients presented with palpable testis

whereas 13 (38%) patients presented with impalpable testes.²

In the present study out of 50 UD, 24 (48%) were located in Inguinal canal, 10 (20%) were located at superficial ring, 10 (20%) were at deep ring and 6 (12%) were intra-abdominal, USG located testis in 41 patients i.e., 100% sensitivity and specificity. In Agrawal et al study 10.2% UDT were not located on USG.¹ In Vijayaraghavan study among 191 patients the testis was canalicular in position in 53, abdominal in 76, ascending in 5, ectopic in 8, and moving in 5 cases. There were three instances of tumor in the NPT and one case of torsion. The testes were atrophic in 36 instances. The testis was not visualized by USG in 10 instances.⁷ Jadhav et al conducted a study among 34 cases, USG located testis in 34 patients i.e., 100% sensitivity and specificity.² In Johansen et al among 113 detectable testicles 47 were assessed retractile and 66 truly undescended of which 60 were operated.⁸

In the present study out of 50 UDT, that were included in present study, 40 (80%) were subjected to orchidopexy, 4 (8%) underwent laproscopic orchidopexy, 5 (10%) underwent laparoscopic 2 stage Stephen-Flower orchidopexy and 1 (2%) underwent orchidectomy. In Agrawal et al study, 81.63% patients orchiopey was done.¹ In Docimo's study a total of 64 articles pertaining to 8,425 undescended testicles was reviewed and found to contain evaluable data. Success was defined as scrotal position and lack of atrophy. Success rates by anatomical testicular position were 74% for abdominal, 82% for peeping and 87% for canalicular testis and 92% for those located beyond the external ring. Success rates by procedure were 89% for inguinal, 67% for Fowler-Stephens, 77% for staged Fowler-Stephens, 81% for transabdominal, 73% for 2nd stage and microvascular orchiopey. In conclusion, the significant failure rate for proximal testis suggests that efforts to improve orchiopey showed continue.⁹ Jadhav et al conducted a study among 34 cases, subdartos pouch orchidopexy was performed in all the patients.² In Agarwal et al study in total, 17 testes of 13 patients had undergone laparoscopic staged Fowler-Stephen orchiopey. The decision to perform a staged Fowler-Stephen orchiopey was based on the distance of the testis from the deep inguinal ring on laparoscopy. Study was concluded that in cases of high intra-abdominal testes, the staged Fowler-Stephen procedure should be the procedure of choice. This procedure yields a high success rate. Transaction of vessels by bipolar diathermy is a very safe, cost-effective method.⁵

In this present study out of 50 UDT fifteen testes (30%) are at Inguinal canal, four (8%) are at posterior abdominal wall, 12 (24%) are at deep ring, seventeen (34%) are at superficial inguinal pouch and 2 (4%) are intraperitoneal. Jadhav et al study showed, 16 (47%) testes were at inguinal canal, 10 (29.5%) were at superficial ring, and 8 (23.5%) at deep ring.²

In this present study out of 41 patients, seizure disorders were found in 2 cases. Hypospadias is mental retardation, cleft lip, developmental delay and inguinal hernia was found in 1 case each.

In this present study out of 41 patients, 1 (2.4%) had wound infection. Agrawal et al in his study found 3 patients (6.93%) were having postoperative wound infection. Jadhav et al in his study found that post operatively three patients (9%) presented with surgical site infection.^{1,2}

CONCLUSION

In our study the maximum number of cases were recorded between 1 to 5 years of age. Right sided UDT is common presentation. Most patients presented with absence of testes in scrotum. Maximum UDT were palpable. We also concluded that USG remains the specific non-invasive modality of diagnosis and localisation. Almost half of them were present in the inguinal canal. Orchidopexy is the most common technique for placement of UDT in the scrotum. There were low complications and high success rate in treating UDT. In the present study we concluded that there is need of coordinated campaign between surgeons, pediatricians, general practitioners and community Workers for timely intervention of UDT and advice for early approach for treatment.

Funding: No funding sources

Conflict of interest: None declared

Ethical approval: The study was approved by the Institutional Ethics Committee

REFERENCES

1. Agrawal MK, Ramteke HB, Wagh DD. Study and management of undescended testes. IJBAR. 2013;04(11):530.
2. Jadhav S, Kumar P. Role of ultrasonography and orchidopexy in undescended testis in semi urban setting of a developing country. Internet J Urol. 2013;11(1):1-6.
3. Kokorowski PJ, Routh JC, Graham DA, Nelson CP. Variations in timing of surgery among boys who underwent orchidopexy for cryptorchidism. Pediatrics. 2010;126(3):e576-82.
4. Shiryazdi SM, Modir A, Benrazavi S, Moosavi N, Kermani-Alghoraishi M, Ghahramani R. Causes of delay in proper treatment of patients with undescended testis. Iran J Reprod Med. 2011;9(1):37-40.
5. Neel KF. Orchidopexy for undescended testis among Saudi children: is it conducted at the optimal age?. Curr Pediatr Res. 2010;14(1):39-41.
6. Sinha CK, Vinay S, Kulkarni R, Nour S. Delayed diagnosis for undescended testes. Indian Pediatr. 2008;45(6):503-4.
7. Vijayaraghavan SB. Sonographic localization of nonpalpable testis: Tracking the cord technique. Indian J Radiol Imag. 2011;21(2):134-41.
8. Bjerklund Johansen TE, Larmo A. Ultrasound in the evaluation of retractile and truly undescended testes. Scand J Urol Nephrol. 1988;22(4):245-50.
9. Docimo SG. The results of surgical therapy for cryptorchidism: a literature review and analysis. J Urol. 1995;154(3):1148-52.

Cite this article as: Shariff NA, Ahmad AMS. A clinical study of undescended testes. Int Surg J 2020;7:489-93.