

## Original Research Article

# Patterns and surgical outcome of neonatal small bowel obstruction: a single center experience from Ujjain, India

Nitin Agarwal<sup>1\*</sup>, Deepika Agarwal<sup>2</sup>, Deepali Pathak<sup>3</sup>, Ashish Pathak<sup>3</sup>

<sup>1</sup>Department of Paediatric Surgery, <sup>2</sup>Department of Anaesthesia, <sup>3</sup>Department of Paediatrics, R. D. Gardi Medical College, Ujjain, Madhya Pradesh, India

**Received:** 10 October 2019

**Revised:** 17 November 2019

**Accepted:** 18 November 2019

**\*Correspondence:**

Dr. Nitin Agarwal,

E-mail: [drnitinagrawal73@gmail.com](mailto:drnitinagrawal73@gmail.com)

**Copyright:** © the author(s), publisher and licensee Medip Academy. This is an open-access article distributed under the terms of the Creative Commons Attribution Non-Commercial License, which permits unrestricted non-commercial use, distribution, and reproduction in any medium, provided the original work is properly cited.

### ABSTRACT

**Background:** Neonatal small bowel obstruction is the most commonly encountered paediatric surgical emergency worldwide and in India. The objective of this study was to study the prevalence and spectrum of neonatal small bowel obstruction.

**Methods:** A retrospective chart review of all neonates aged between 1-28 days that underwent surgery for small intestinal obstruction between January 2017 to January 2019 at Department of Paediatric Surgery, R.D. Gardi Medical College, Ujjain, MP. A predesigned questionnaire was used to collect demographic, clinical and outcome related information. Exploratory laparotomy and type of surgical intervention was done as per the cause.

**Results:** A total of 52 neonates (M: F ratio 1.74: 1) were included in the study. The most common clinical features were vomiting (92%), bilious vomiting (85%) and abdominal fullness (75%) and laboratory feature was leucocytosis (42%) and thrombocytopenia (31%). Most (66%) neonates presented between 2-7 days and belonged to rural areas (65%). The two most common final diagnosis were malrotation (56%) and intestinal atresia (23%). Associated anomalies were seen in 29% [vertebral defects, anal atresia, cardiac defects, tracheo-esophageal fistula, renal anomalies, and limb abnormalities association (8%) and congenital heart disease (8%)]. The mean ( $\pm$ SD) duration to reach full feeds and duration of neonatal intensive care unit stay was  $6.2\pm 1.3$  and  $14.1 (\pm 5)$  days, respectively. Complications were seen in 20% cases, most common being early bowel obstruction. A total of 6 (11.5%) neonates died in the post-operative period, 83% because of sepsis.

**Conclusions:** Small bowel obstruction is common neonatal surgical emergency. Most common cause is malrotation and intestinal atresia. Neonatal sepsis is the most common underlying cause of death post-operatively.

**Keywords:** Small bowel obstruction, Neonatal surgical emergency, Clinical features, Malrotation, Intestinal obstruction, Ujjain

### INTRODUCTION

According to Global Burden of Disease estimates for 2018 based on World Health Organization data an estimated 3,03,000 new-borns die within 4 weeks of life worldwide due to congenital anomalies.<sup>1</sup> The problem is likely to be underestimated by at least four times in low-middle-income countries due to lack of data from these

resource poor settings.<sup>1,2</sup> In high income countries the prognosis for even very complex congenital anomalies is improving, with a success rate of up-to 90%.<sup>3</sup> Improvements in prenatal diagnosis and availability of specialized paediatric surgery centres has improved the care of congenital anomalies in India.<sup>4</sup> However, performing surgery in neonates is still a challenge in low income countries including India.<sup>5</sup> Although many

studies have been conducted in the past on the neonatal surgeries, but the clinical studies on this problem are scanty in Indian literature. The incidence of neonatal surgical emergencies varies between 1 to 4 per 100 births.<sup>6</sup> Intestinal obstruction (both small and large bowel) is the most common surgical emergency in first 28 days of life i.e., the neonatal period.<sup>1,2,6</sup> The incidence of neonatal intestinal obstruction is about 1 in 1500 live births.<sup>6</sup> Of the intestinal obstruction upper intestinal or small bowel obstruction have not been frequently studied. Therefore, the objective of this retrospective clinical chart review was to study the prevalence and spectrum of small bowel surgical congenital anomalies presenting as intestinal obstruction in the Ujjain region, their clinical features at presentation, short term complications, mortality rate and the immediate cause of death.

## METHODS

This cross-sectional analytical study was done by retrospective analysis of medical records of the neonates presenting with the clinical diagnosis of intestinal obstruction at Paediatric Surgical Unit and Neonatal Intensive Care Unit (NICU) of R.D. Gardi Medical College (RDGMC) between January 2017 to January 2019. Data was collected using a predesigned questionnaire by abstracting information from each case sheet of the neonates who were admitted and operated for intestinal obstruction. The questionnaire included information on age of admission to the SU/NICU, gestational age, male to female ratio, prenatal diagnosis if any, clinical features at presentation, short-term complications, mortality rate and the immediate cause of death, complications and co-morbidities diagnosed during the hospitalization and final diagnosis and outcome. Final diagnosis was established either clinically by the operating surgeon (intraoperatively) or by the histopathological reports attached to the case records.

### *Inclusion criteria*

All neonates aged between 1 day to 28 days of age with clinical diagnosis of small intestinal obstruction admitted between January 2017 to January 2019 who underwent surgery at Department of Paediatric Surgery, RDGMC, Ujjain, MP. In this study only initial surgical procedure and its outcome were included.

### *Exclusion criteria*

Exclusion criteria were neonates in whom a definitive diagnosis of cause of obstruction was not reached with investigation or operative findings; neonates who died or absconded before a diagnosis of cause of intestinal obstruction was reached; neonates who were inoperable due to septic shock, pneumonia, very low birth weight and extreme prematurity; parents or caregivers who refused operative intervention and all large bowel causes of intestinal obstruction.

## *Initial stabilization and surgical procedures*

All neonates were put on intravenous fluids, antibiotics as per institutional policy and nasogastric decompression was done. Fluid resuscitation was done as required. First, dehydration and electrolyte imbalance if present were corrected. The following investigations were done in all neonates which are septic screen (complete blood count, peripheral smear for band cells, C-reactive protein, and micro erythrocyte sedimentation rate and blood culture), abdominal X-ray, and ultrasound. Contrast studies were done as required. Exploratory laparotomy was done in all the cases and type of surgical intervention was carried as per the cause.<sup>2,3,6</sup> For duodenal and ileal atresia, duodenoplasty and enteroplasty was done.<sup>2,3,6</sup> Resection and anastomosis were done in jejunoileal atresia, and Ladd's procedure in malrotation of the gut.<sup>2,3,6</sup> Hypertrophic pyloric stenosis (HPS) was treated by pyloromyotomy.<sup>3,7</sup> In postoperative period, patients were managed by nasogastric aspiration, fluids and antibiotics when needed. Neonates were discharged between 10-14 days post-operatively after full feeds were achieved. Diagnosis was confirmed by histopathological sampling done during operative procedure.

## *Data analysis*

The descriptive analysis presented in the manuscript was performed using Stata (version 12.0, Stata Corp., College Station, TX, USA).

## RESULTS

A total of 52 neonates satisfying the inclusion criteria were admitted during the study period. Of which, 63% (n=33) were boys and 37% (n=19) were girls, giving a male to female sex ratio of 1.74:1. Most (55%, n=30) were term babies and the remaining preterm. The mean ( $\pm$ SD) gestational age was 36.4 $\pm$ 1.2 weeks. A suggestive anti-natal diagnosis based on ultrasonography was present in 58% (30/52) cases. A high proportion (66%) of new-born were out-born. The clinical and laboratory features at presentation is shown in (Table 1).

The age at presentation, gender, whether residing in rural or urban area, diagnosis, associated co-morbidities, the outcome of surgery and cause of death are presented in Table 2.

Figure 1 presents the etiological spectrum of small bowel intestinal obstruction according to gender of the neonates.

Post-operatively neonates were kept in NICU for monitoring. Babies were started feeds orally after there were no bilious aspirates and they had passed stools. The mean ( $\pm$ SD) duration to reach full feeds was 6.2 $\pm$ 1.3 days. The mean ( $\pm$ SD) duration of stay in NICU was 14.1 ( $\pm$ 5) days.

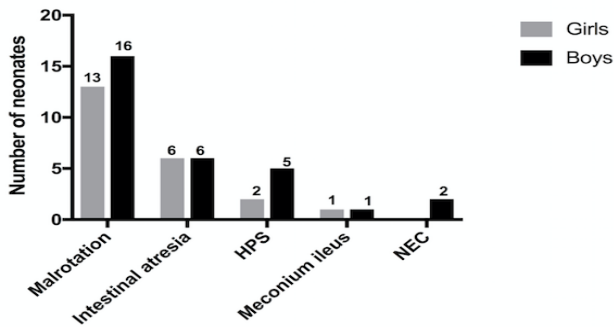
**Table 1: Clinical presentation and laboratory features of neonates with small bowel obstruction (n=52) at RDGMC, Ujjain.**

Signs, symptoms	N (%)
<b>Vomiting</b>	48 (92)
<b>Bilious vomiting</b>	44 (85)
<b>Epigastric fullness</b>	39 (75)
<b>Visible bowel loops</b>	17 (33)
<b>Dehydration</b>	14 (28)
<b>Maternal polyhydramnios</b>	14 (28)
<b>Shock</b>	12 (23)
<b>Failure to pass meconium in first 24 hours</b>	12 (23)
<b>Periumbilical erythema</b>	6 (12)
<b>Laboratory features</b>	
Leucocytosis	22 (42)
Thrombocytopenia	16 (31)
Leukopenia	15 (29)
Hyperkalaemia	8 (15)
Physiological hyperbilirubinemia	8 (15)

**Table 2: Demographic factors, diagnosis, associated co-morbidities, the outcome of surgery and cause of death in neonates with small bowel obstruction (n=52) at RDGMC, Ujjain.**

Variables	N (%)
<b>Age at presentation</b>	
Day 1	7 (13)
Day 2-3	15 (29)
Day >3-7	19 (37)
Day >7-28	11 (21)
<b>Gender</b>	
Boys	33 (63)
Girls	19 (37)
<b>Residence</b>	
Rural	34 (65)
Urban	18 (35)
<b>Diagnosis</b>	
Malrotation	29 (56)
Intestinal atresia	12 (23)
HPS	7 (13)
Meconium ileus	2 (4)
NEC	2 (4)
<b>Associated anomalies</b>	
No	37 (71)
Yes	15 (29)
<b>VACTERL association</b>	4 (8)
<b>Congenital heart disease</b>	4 (8)
<b>Abdominal wall defects</b>	3 (6)
<b>Tracheoesophageal fistula</b>	2 (4)
<b>Hypospadias</b>	2 (4)
<b>Final outcome</b>	
Discharged	43 (83)
Deaths	9 (17)
<b>Immediate causes of death</b>	6 (11.5)
Sepsis/DIC	5 (83)
Surgical complications	1 (17)

HPS: Hypertrophic pyloric stenosis, VACTERL: Vertebral defects, anal atresia, cardiac defects, tracheoesophageal fistula, renal anomalies, and limb abnormalities, DIC: Disseminated intravascular coagulation.



**Figure 1: Etiological spectrum of small bowel intestinal obstruction according to gender of the neonates (n=52) at RDGMC, Ujjain.**

Post-operative complications are presented in (Table 3). A total of 6 (11.5%) neonates died in the post-operative period, with most common (83%) cause of death being sepsis. One neonate died of surgical complications.

**Table 3: Post-operative complications in neonates with small bowel obstruction at RDGMC, Ujjain (n=20).**

Variable	N (%)
Early bowel obstruction	12 (60)
Wound complications	3 (15)
Repeat laparotomy	3 (15)
Anastomotic leak	1 (5)
Ischemia in the pull-through segment	1 (5)

## DISCUSSION

The most common presentation of neonatal small bowel obstruction in our study was vomiting or bilious vomiting, which along with abdominal distension is the most common clinical picture of bowel obstruction in neonates.<sup>2,6,8,9</sup> Although, none of these clinical features are pathognomic of intestinal obstruction, when considered together they are should alarm the health care workers to consider intestinal obstruction and such babies should be evaluated or referred if facilities for evaluation are not available. Other clinical features seen in our study were visible bowel loops, evidence of dehydration and maternal polyhydramnios.<sup>2,6,8,9</sup> Duodenal and jejunal atresia are associated with maternal polyhydramnios in about one-fourth of cases.<sup>6,10,11</sup> About 30% of the anomalies were identified in antenatal ultrasound, because of which the lesions could be anticipated and a management plan was developed for the treatment of neonate. The most common laboratory feature was leucocytosis, thrombocytopenia and leukopenia, which together reflect high frequency of sepsis in the neonates included in the study. Hyperkalemia and prolonged jaundice are known clinical findings in neonates with intestinal obstruction.<sup>6,9,12</sup>

Most neonates presented late. This could be due to high proportion of extra-mural neonates in the study and

mainly due to delay in referral. The delay in referral is despite the presence of common sign and symptoms of feed intolerance and bilious vomiting. Red flags for neonates with vomiting and abdominal distension need to be reinforced among the health care workers in the study area. An accurate history and physical examination corroborated by simple radiological studies usually leads to a correct diagnosis.<sup>2,3,6,8</sup> Most often, a plain abdominal radiograph is all that is necessary to make a diagnosis, since gas pattern is distinctive and often will give a clue to the site of obstruction.<sup>2,3,6,8</sup> Early diagnosis and treatment leads to better outcome.<sup>3,6</sup> Failure to recognize neonatal bowel obstruction can result in aspiration of vomit, sepsis, midgut infarction or enterocolitis.<sup>3,6</sup> Delay in carrying out surgery may result in the loss of large amounts of bowel.<sup>3,6</sup>

Common aetiologies for bowel obstruction are intestinal atresia, meconium ileus, Hirschsprung disease and malrotation of gut with or without volvulus.<sup>2,3,6,11</sup> In the present study we included neonates with small bowel obstruction only. Small bowel obstruction in a neonate is a common surgical emergency.<sup>2,3,6,11</sup> In Indian studies the most common cause is variable with one study reporting duodenal atresia as the commonest cause while other study from Rohtak report malrotation as more common.<sup>14</sup> Our findings are similar to that of Rohtak study.<sup>13,14</sup> HPS usually presents a bit later in infancy, but neonatal cases are known.<sup>7,15</sup> Vertebral defects, anal atresia, cardiac defects, tracheoesophageal fistula, renal anomalies, and limb abnormalities (VACTERL) anomalies are known in neonates with intestinal obstruction and contribute to increased morbidity and mortality in these neonates.<sup>9,11,13,14</sup> The complications observed in our study (Table 3) are comparable to other international studies and Indian studies.<sup>9,11-14</sup>

A comparatively higher mortality rates are observed from studies reported from low-middle income countries.<sup>5</sup> Some causes for this high mortality are prematurity, late presentation, associated congenital anomalies, complications of surgery as well as lack of intensive care facilities.<sup>5</sup> Mortality was low in our study because of availability of neonatal intensive care services.

## CONCLUSION

Small bowel obstruction is common neonatal surgical emergency. Most common cause identified in the present study are malrotation and intestinal atresia. Common anomalies like VACTERL anomalies and congenital heart diseases should be looked for before surgery. Neonatal sepsis is the most common underlying cause of death post-operatively.

*Funding: No funding sources*

*Conflict of interest: None declared*

*Ethical approval: The study was approved by the Institutional Ethics Committee*

## REFERENCES

1. Boyle B, Addor MC, Arriola L, Barisic I, Bianchi F, Csaky-Szunyogh M, et al. Estimating Global Burden of Disease due to congenital anomaly: an analysis of European data. *Arch Dis Child Fetal Neonatal Ed.* 2018;103(1):F22-8.
2. Juang D, Snyder CL. Neonatal bowel obstruction. *Surg Clin North Am.* 2012;92(3):685-711.
3. Farmer D, Sitkin N, Lofberg K, Lofberg K, Donkor P, Ozgediz D. Surgical Interventions for congenital anomalies. *Essential Surgery: Disease Control Priorities.* 2015;3(1):1-45.
4. Gupta DK, Charles AR, Srinivas M. Pediatric surgery in India- a specialty come of age?. *Pediatr Surg Int.* 2002;18(8):649-52.
5. Sitkin NA, Ozgediz D, Donkor P, Farmer DL. Congenital anomalies in low- and middle-income countries: the unborn child of global surgery. *World J Surg.* 2015;39(1):36-40.
6. Maqbool ABC, Lecouras CA. Intestinal atresia, stenosis and malrotation. In: Kliegman R, Stanton B, St. Geme JW, Schor NF, Behrman RE, Nelson WE, eds. In: *Nelson Textbook of Pediatrics.* 21st ed. Philadelphia, PA: Elsevier; 2019: 1950-1954.
7. Peters B, Oomen MW, Bakx R, Benninga, M. A. Advances in infantile hypertrophic pyloric stenosis. *Expert Rev Gastroenterol Hepatol.* 2014;8(5):533-41.
8. Muratore CS, Tracy TF. Neonatal Bowel Obstruction. In: Bland KI, Büchler MW, Csendes A, Sarr MG, Garden OJ, Wong J, eds. *Gen Surg.* London: Springer; 2009.
9. Sholadoye TT, Mshelbwala PM, Ameh EA. Presentation and outcome of treatment of jejunoileal atresia in Nigeria. *Afr J Paediatr Surg.* 2018;15(2):84-7.
10. Adams SD, Stanton MP. Malrotation and intestinal atresias. *Early Hum Dev.* 2014;90(12):921-5.
11. Correa C, Mallarino C, Pena R, Rincon LC, Gracia G, Zarante I. Congenital malformations of pediatric surgical interest: prevalence, risk factors, and prenatal diagnosis between 2005 and 2012 in the capital city of a developing country. Bogota, Colombia. *J Pediatr Surg.* 2014;49(7):1099-103.
12. Dalla Vecchia LK, Grosfeld JL, West KW, Rescorla FJ, Scherer LR, Engum SA. Intestinal atresia and stenosis: a 25-year experience with 277 cases. *Arch Surg.* 1998;133(5):490-6.
13. Rattan KN, Singh J, Dalal P. Neonatal duodenal obstruction: a 15-year experience. *J Neonatal Surg.* 2016;5(2):13.
14. Verma A, Rattan KN, Yadav R. Neonatal Intestinal Obstruction: A 15 Year Experience in a Tertiary Care Hospital. *J Clin Diagn Res.* 2016;10(2):SC10-3.
15. Vinycomb TI, Laslett K, Gwini SM, Teague W, Nataraja RM. Presentation and outcomes in hypertrophic pyloric stenosis: an 11-year review. *J Paediatr Child Health.* 2019;55(10):1183-7.

**Cite this article as:** Agarwal N, Agarwal D, Pathak D, Pathak A. Patterns and surgical outcome of neonatal small bowel obstruction: a single center experience from Ujjain, India. *Int Surg J* 2019;6:4471-5.