

Original Research Article

Role of flap fixation during modified radical mastectomy in locally advanced breast carcinoma patients: a randomised control study

Raghavendra R. T.*, Sushanto Neogi

Department of General Surgery, Lok Nayak Hospital, Maulana Azad Medical College, New Delhi, India

Received: 06 October 2019

Revised: 17 November 2019

Accepted: 18 November 2019

***Correspondence:**

Dr. Raghavendra R. T.,

E-mail: raghavendra.rt27@gmail.com

Copyright: © the author(s), publisher and licensee Medip Academy. This is an open-access article distributed under the terms of the Creative Commons Attribution Non-Commercial License, which permits unrestricted non-commercial use, distribution, and reproduction in any medium, provided the original work is properly cited.

ABSTRACT

Background: Treatment of locally advanced breast carcinoma (LABC) patients involves multimodal approach. Modified radical mastectomy (MRM) is preferred in them. Seroma and prolonged drainage are most common post-op complications. This study was conducted to evaluate the effect Flap fixation technique in reducing drain output and seroma in patients with LABC.

Methods: 30 stage III breast cancer patients undergoing MRM were included. Prior to skin closure patients were randomised into: test (15) and control group (15). In Test group, skin flaps were sutured to chest wall with vicryl 3-0 at 3 cm intervals and skin was closed with nylon. In conventional group, only skin was closed with nylon sutures. In both the groups conventional closed suction drains were placed. Total drain output, clinically significant seroma, post-operative complications were compared between the two groups.

Results: Total drain output in test group (4445 ml) was lesser compared to control group (4801 ml) but not statistically significant ($p=0.548$), however the percentage reduction of drain output on day 2 was significantly higher in test group (42%) as compared to control group (31.8%) ($p=0.04$). The clinically significant Seroma formation rates were similar in both groups but the volume of seroma aspirated was significantly lower in test group ($p<0.05$).

Conclusions: The flap fixation technique group had better approximation of skin flaps and chest wall, as evident with reduction of drain output, significant reduction in drain output on post op day 2 and reduction of seroma volume.

Keywords: Flap fixation technique, Modified radical mastectomy, Seroma

INTRODUCTION

Breast is the most common site for neoplasm and leading cause of cancer related death in women across the world.¹ Locally advanced breast cancer (LABC) patients constitute 10-20% of the newly diagnosed cases, but in India it is as high as 30-60%.² They are grouped under Stage III in current AJCC classification. Treatment involves multimodal approach, involving neo adjuvant systemic therapy, surgery and radiotherapy. MRM is preferred in most of this patients.³ Seroma is the most common complication post MRM and can be identified as subcutaneous collection of serous fluid under pectoral

flaps or axillary space. Seroma increase chances of surgical site infection (SSI), delay in wound healing, wound dehiscence, discomfort due to repeated aspiration, repeated visits to hospital to deal with seroma and its sequelae.⁴

Any technique effective in obliterating dead space and promote flap adherence by draining the fluid as and when formed would be ideal for prevention of these complication.⁵ Currently suction drain is used as standard procedure; drain is removed once the drain output reduces to less than 50 ml/day for two consecutive days. Sometimes this can prolong duration of drainage and

increases the risk of SSI, by retrograde spread and causing delay in initiation of adjuvant therapy.⁶ So various techniques such as adhesive glue, external compression, suction drains, flap fixation (quilting) etc have been tried for obliterating dead space.

The aim of this study was to evaluate the effect of flap fixation technique on drain output and seroma formation after MRM in LABC patients in comparison with conventional technique.

METHODS

30 biopsy proven LABC patients planned for Modified Radical Mastectomy (MRM) in department of General Surgery, Lok Nayak Hospital, New Delhi, were included in this study. The study was conducted between September 2017 to December 2018. Patients with previous history of chest wall irradiation and Breast surgery to same side were excluded from this study. Written informed consent was obtained and standard MRM procedure was performed. All surgeries were done by a single surgeon using scalpel to develop skin flaps, sharp dissection for axilla and selective cauterisation of bleeding vessel. After placement of suction drain tube beneath pectoral and axillary skin flaps, prior to closure, patients were randomised into test (15 patients) and control group (15 patients). The randomisation was done using computer generated random numbers and allocation into two groups was done by sealed envelope technique.

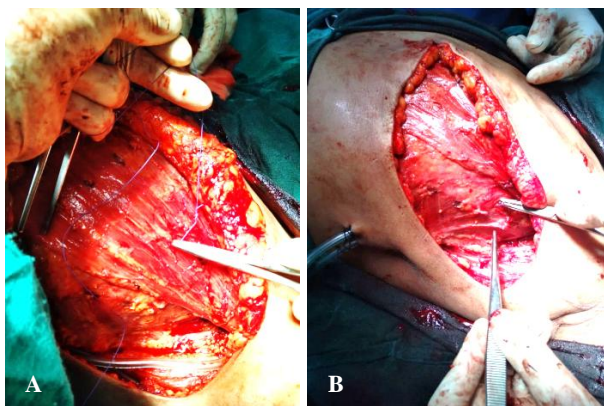


Figure 1 (A and B): Depicting fixation of skin flap to chest wall and axillary skin flap to chest wall.

In test group, the subcutaneous tissue of skin flap was anchored to chest wall with polyglactin (vicryl) 3-0 sutures 3cm apart and skin was closed with interrupted nylon sutures. In control group, skin was closed with nylon suture only.²²

The drain output was measured daily using measuring cylinder and drains were removed once the drain output was less than 50 ml/day. During follow up for 3 months, Seroma was detected clinically, as collection under skin flaps. Only symptomatic seromas were therapeutically aspirated under aseptic precaution. Other complications

such as SSI, flap necrosis were noted and other complication in both groups were also noted and managed according to clinical situation.

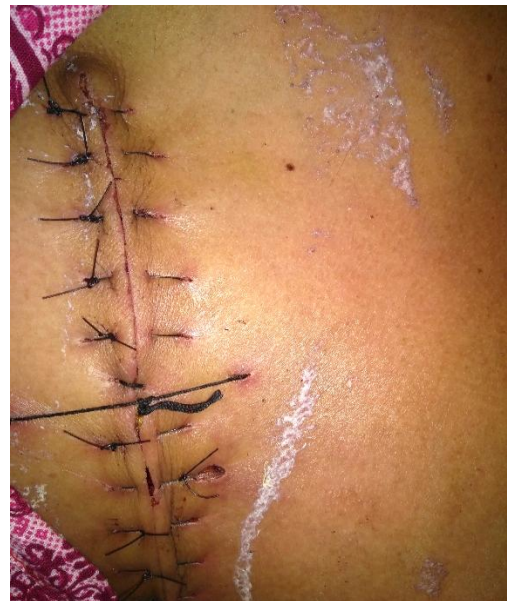

Figure 2: Depicting post skin closure, with tension sutures (removed after 48 hours) in place for approximation of skin flaps.

Statistical analysis: The total drain output, Seroma volume aspirated between two groups were compared using t test.

Incidence of seroma was compared using Chi square test, and Pearson correlation coefficient was used to correlate between other quantitative parameters with drain output. p<0.05 was considered statistically significant.

RESULTS

Both groups were comparable in terms of patient age, BMI, comorbidity. The same is depicted in Table 1. 25 out of 30 patients received neo adjuvant chemotherapy (NACT), 10 and 15 in control and test group respectively. The p value being 0.424, both groups were matched. Histology of tumor on corecut biopsy in all patients was infiltrating ductal carcinoma (Grade II).

Table 1: Summarising patient characteristics.

	Control	Test	p value
Age (years)	44.73±12.04	47.2±29.16	0.533
BMI(kg/m²)	23.12±3.29	24.21±3.05	0.355
Co-morbidity			
Yes	12	12	1.00
No	3	3	

The operating time in test group exceeded by an average of 22 mins excess as compared to control group (test-114.2 mins v/s control 92 mins) which was statistically

significant (p<0.001). The time for flap fixation, accounts for the extra time. The total lymph node extracted (p=0.31) and number of positive lymph nodes (p=0.28) were similar between 2 groups, with mean of 10.33 and 2.73 respectively (Table 2).

Table 2: Total number of lymph nodes and positive lymph nodes in study group.

	Control	Test	P value
No of positive lymph node			0.289
Mean±SD	2.13±3.02	2.73±2.74	
Total number of lymph node			0.31
Mean±SD	11.33±2.47	10.33±2.82	

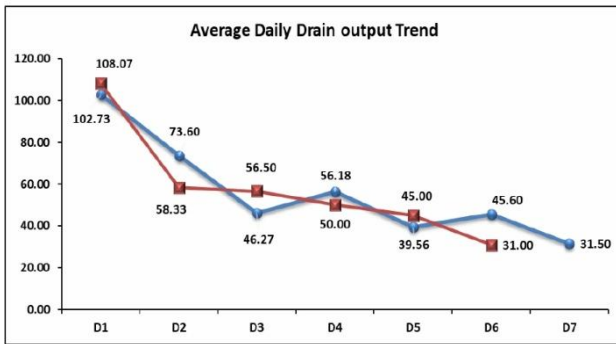


Figure 3: Depicting average daily drain output trend.

Table 3: Correlation between total drain output and lymph node extracted.

		Total drain output
Test		
No of positive lymph node	Correlation Coefficient	-0.045
	P value	0.8724
Total number of lymph node	Correlation Coefficient	-0.238
	P value	0.392
Control		
No of positive lymph node	Correlation Coefficient	0.096
	P value	0.7341
Total number of lymph node	Correlation Coefficient	-0.034
	P value	0.9053

Table 4: Summarising operative and post-operative results.

	Test	Control	P value
1) Operating time (in minutes)	114.27±13.35	92.533±9.03	<0.0001
2) Duration of stay (in days)	98	99	0.806
3) Drain output (ml)			
a) Total drain output	4445(295±145.55)	4801(320.6±249.64)	0.548
b) Drain output per day	50.42±20.5	48.33±39.9	0.856
c) Drain output for first 2 days	166.4	176.33	0.078
d) Reduction in drain output from D1 to D2	42.8%	31.89%	0.04
4) Duration of drain removal	5.8 days	6.4 days	0.474
5) Seroma			
a) Yes	3	3	1.000
b) No	12	12	
c) Volume of seroma aspirated (ml)	142±17.67	350±91.21	<0.05

Continued.

The total drain output among the test group was lesser compared to control group (test=4445 ml v/s control 4809 ml), but the difference was not statistically significant (p=0.54). The mean drain output and drain output per day were on similar trend as total drain output, as depicted by Table 4. The daily drain output analysis suggests a significant percentage drain output reduction on post op day 2 in test (42.8%) as compared to control group (31.89%) with p<0.05 (Figure 3). The correlation of lymph node harvested during surgery with drain output suggested no significant correlation, as depicted in Table 3. Though drains were removed earlier in test group, there was no significant difference in their removal between two groups (test 5.8 v/s control 6.4 days).

During 3 months follow up seroma rates between the two groups were same, 3 in each group. But there was significant reduction in volume of seroma aspirated and number of aspirations in test group (142.5 ml, 2) compared to control group (350 ml, 5) with p<0.05.

Surgical site infection (SSI) was documented in 4 patients, 3 (20%) in test and 1 (6.67%) in control group. There was no significant difference in SSI between two groups (p=0.598). SSI was managed with antibiotics and only one patient required debridement. There was no significant difference in flap necrosis rates, 2 (13.33%) in control and 1 (16.67%) in test group, all were partial thickness necrosis.

	Test	Control	P value
6) Flap necrosis			
a) Yes	1	2	1.000
b) No	14	13	
7) SSI			
a) Yes	3	1	0.598
b) No	12	14	

Bold values are significant.

DISCUSSION

Post MRM prolonged excessive drainage and seroma are one of the major post-operative concern causing delay in initiation of adjuvant therapy and prolonged hospital stay. The incidence of seroma is estimated to be around 15-81%.⁷ Definition of seroma varies in literature, it is described as symptomatic fluctuant swelling on examination requiring aspiration in some, while some have defined it using Ultrasonography (USG). But in a study by Jeffrey et al, USG detected higher rates of seroma and its resolution took longer duration compared to physical examination alone.^{8,9} In our study only symptomatic collection under skin flaps or axilla on physical examination were considered, and therapeutically aspirated in symptomatic patients.

Currently, there is limited understanding of seroma pathophysiology. Various factors leading to seroma were evaluated in many studies and found that age, obesity, neoadjuvant therapy was not associated with seroma formation.¹⁰ In a systemic review by Van bemmel et al,

also suggested no association between tumor size, lymph node status and neo adjuvant therapy on seroma.¹¹

But according to Petrek et al, most important factor for prolonged drainage was total number extracted and extent of lymph node involvement.¹² But in our study, no association between positive lymph nodes or number of lymph nodes with drain output was noted.

Tissue dissection techniques have long been implicated in increasing drainage volume and seroma formation. Electrocautery for breast dissection was beneficial in reducing incision time, reducing blood loss and transfusion requirements, but was also found to increase seroma compared to scalpel and harmonic dissection (Table 5).¹³⁻¹⁶ In this study this factor was taken care by the use of scalpel for raising skin flaps and sharp dissection for axilla, haemostasis by selective cauterisation of bleeding vessel and this resulted in lower total drain output and early drain removal in both the group compared to other previous studies suggesting its increased efficacy over widely used electrocautery.²²

Table 5: Depicting various studies reporting incidence of electrocautery, scalpel and harmonic group.

Name	Type of study	Incidence in electrocautery group (%)	Incidence in scalpel group (%)	Incidence in harmonic group (%)	Year
Porter et al ¹³	RCT	38	13	NA	1998
Keogh et al ¹⁴	RCT	38	10	NA	1998
Deo et al ¹⁵	Comparative	22	NA	16	2000
Galatius et al ¹⁶	Comparative	NA	69	67	2003

A large raw surface is created following extensive dissection in MRM resulting in continuous oozing of lymph and blood.¹⁷ Gonzalez et al and Hashemi et al evaluated type of surgery and found that BCS was found to have significantly lower seroma rates compared to MRM.^{18,19}

An ideal wound closure, therefore should limit spillage of lymph, fix flap to chest wall by obliterating dead space and allow rapid removal of fluid. Suction drains are used commonly, can prevent sealing of lymphatics thus prolonging drainage and increase hospital stay.^{20,21}

Several studies have proposed suturing of skin flap to chest wall is one of the effective methods in obliterating dead space.²² But these studies have varied in placement of sutures in fixing the flaps. RCT by Purushottam et al,

suggested that in 375 patients, early discharge was observed in skin flap suturing, with no drain group compared to conventional group, with no significant surgical or psychological morbidity.²³ An RCT by Coveney et al, showed significantly less drainage in fixation group.²⁴

By axillary flap fixation, axillary drain can be avoided in patients undergoing breast conserving surgery and conventional axillary lymphadenectomy.²³ Tacking anterior edge of upper Latissimus dorsi muscle and posterior lateral edge of pectoralis muscle to chest wall below the level of axillary vein was found to be effective in obliterating deep axillary cavity.²⁰ Buttress suturing of axillary skin to serratus anterior muscle was found to be effective in reducing seroma by obliterating axillary space.²⁵ In a RCT by Sakkary et al, the flap fixation technique was effective in reducing drain output and

seroma incidence both clinically and ultrasonographically.²²

In our study the overall seroma rate was 20%, 3 in each group, which is within the range of incidence mentioned in literature 15-81%.⁷ Volume of seroma aspirated were significantly less in test group compared to control ($p < 0.05$). This study, evaluated the effectiveness of flap fixation technique in patients with LABC, while in prior studies, study population was predominantly Early breast cancer.^{22,24} The other complication rates were on par with standard rates.

The flap fixation technique was effective in reducing drain output in test group, but was not statistically significant. The reduction in drain output at 48 hrs was significant in test group compared to control group (42% v/s 31.9%, $p = 0.04$). Possible explanation could be better approximation of skin flaps to chest wall resulting in better haemostasis of oozing raw surface by flap fixation technique. The operative time was increased by an average of 22 minutes.

CONCLUSION

Flap fixation technique was effective in obliterating dead space post MRM, as evident by significant reduction in seroma volume. This technique was effective in reducing the total drain output and better haemostasis by approximation of flaps as evident with significant drain output reduction at 48 hours.

Funding: No funding sources

Conflict of interest: None declared

Ethical approval: The study was approved by the Institutional Ethics Committee

REFERENCES

- Sasco A J. Epidemiology of Breast Cancer: An Environmental Disease. *Apmis*. 2001;109:321-32.
- Rustogi A, Budrukkar A, Dinshaw K, Jalali R. Management of locally advanced breast cancer: evolution and current practice. *J Cancer Res Therap*. 2005;1(1):21.
- Franceschini G, Terribile D, Magno S, Fabbri C, d'alba PF. Update in the treatment of locally advanced breast cancer: a multidisciplinary approach. *Eur Rev Med Pharmacol Sci*. 2007;11:283-9.
- William, Stehbens E. Post-mastectomy serous drainage and seroma: probable pathogenesis and prevention. *ANZ J Surg*. 2003;73:877-80.
- Pogson CJ, Adwani A, Ebbs SR. Seroma following breast cancer surgery. *Eur J Surg Oncol*. 2003;29(9):711-7.
- Classe JM, Dupre PF, François T, Robard S, Theard JL, Dravet F. Axillary padding as an alternative to closed suction drain for ambulatory axillary lymphadenectomy: a prospective cohort of 207 patients with early breast cancer. *Arch Surg*. 2002;137:169-73.
- Woodworth PA, McBoyle MF, Helmer SD, Beamer RL. Seroma formation after breast cancer surgery: incidence and predicting factors. *Am Surg*. 2000;66:444-50.
- Kuroi K, Shimozuma K, Taguchi T, Imai H, Yamashiro H, Ohsumi S, Saito S. Pathophysiology of seroma in breast cancer. *Breast Cancer*. 2005;12(4):288-93.
- Jeffrey SS, Goodson WH, Ikeda DM, Birdwell RL, Bogetz MS. Axillary lymphadenectomy for breast cancer without axillary drainage. *Arch Surg*. 1995;130(8):909-13.
- Agrawal A, Ayantunde AA, Cheung KL. Concepts of seroma formation and prevention in breast cancer surgery. *ANZ J Surg*. 2006;76(12):1088-95.
- A.J.M. van Bommel, C.J.H. van de Velde, R.F. Schmitz, G.J. Liefers. Prevention of seroma formation after axillary dissection in breast cancer: A systematic review. *Eur J Surg Onco*. 2011;37:829-35.
- Petrek J, Peters M, Nori S, Knauer C, Kinne D, Rogatko A. Axillary lymphadenectomy. A prospective, randomized trial of 13 factors influencing drainage, including early or delayed arm mobilization. *Arch Surg*. 1990;125:378-82.
- Porter KA, O'Connor S, Rimm E, Lopez M. Electrocautery as a factor in seroma formation following mastectomy. *Am J Surg*. 1998;176:8-11.
- Keogh GW, Doughty JC, McArdle CS, Cooke TG. Seroma formation related to electrocautery in breast surgery: a prospective randomized trial. *The Breast*. 1998;7(1):39-41.
- Deo SV, Shukla NK. Modified radical mastectomy using harmonic scalpel. *J Surg Oncol*. 2000;204:7.
- Galatius H, Okholm M, Hoffmann J. Mastectomy using ultrasonic dissection: effect on seroma formation. *Breast*. 2003;12(5):338-41.
- Budd DC, Cochran RC, Sturtz DL, Fouty Jr WJ. Surgical morbidity after mastectomy operations. *Am J Surg*. 1978;135(2):218-20.
- Gonzalez EA, Saltzstein EC, Riedner CS, Nelson BK. Seroma formation following breast cancer surgery. *Breast J*. 2003;9:385-8.
- Hashemi E, Kaviani A, Najafi M, Ebrahimi M, Hooshmand H, Montazeri A. Seroma formation after surgery for breast cancer. *World J Surg Oncol*. 2004;2:44.
- Aitken DR, Minton JP. Complications associated with mastectomy. *Surg Clin North Am*. 1983;63(6):1331-52.
- Kopelman D, Klemm O, Bahous H, Klein R, Krausz M, Hashmonai M. Postoperative suction drainage of the axilla: for how long? Prospective randomised trial. *Eur J Surg*. 1999;165(2):117-20.
- Sakkary MA. The value of mastectomy flap fixation in reducing fluid drainage and seroma formation in breast cancer patients. *World J Surg Oncol*. 2012;10(1):8.

23. Purushottam AD, Latchie MC, Young S, George D. Randomized Control Trial of no wound Drains and early discharge in the treatment of women with breast cancer. *Br J Surg.* 2002;89:286-92.
24. Coveney EC, O'Dwyer PJ, Geraghty JG, O'Higgins NJ. Effect of closing dead space on seroma formation after mastectomy--a prospective randomized clinical trial. *Eur J Surg Oncol.* 1993;19(2):143-6.
25. Schuijtvlot M, Sahu AK, Cawthorn SJ. A prospective audit of the use of a buttress suture to reduce seroma formation following axillary node dissection without drains. *The Breast.* 2002;11(1):94-6.

Cite this article as: Raghavendra RT, Neogi S. Role of flap fixation during modified radical mastectomy in locally advanced breast carcinoma patients: a randomised control study. *Int Surg J* 2019;6:4465-70.