

## Original Research Article

# Loop ileostomy versus transverse colostomy as a covering stoma after anterior resection for rectal cancer

Saied Hosny Bendary<sup>1</sup>, Abd Elfatah T. El Sheikh<sup>1</sup>, Mahmoud Kamal Ramadan<sup>2\*</sup>

<sup>1</sup>Department of Surgical Oncology, Faculty of Medicine, Al Azhar University, Cairo, Egypt

<sup>2</sup>Department of Surgical Oncology, Damanhur general Hospital, Al Beheira, Egypt

**Received:** 05 October 2019

**Accepted:** 25 October 2019

### \*Correspondence:

Dr. Mahmoud Kamal Ramadan,

E-mail: [mahmoudkamalramadan92@gmail.com](mailto:mahmoudkamalramadan92@gmail.com)

**Copyright:** © the author(s), publisher and licensee Medip Academy. This is an open-access article distributed under the terms of the Creative Commons Attribution Non-Commercial License, which permits unrestricted non-commercial use, distribution, and reproduction in any medium, provided the original work is properly cited.

## ABSTRACT

**Background:** Most colorectal cancer occurs due to lifestyle and increase age with only a minority of cases associated with underlying genetic disorders and environmental factors enables us to move in the direction of a complete assessment of disease risk. The objective of the present study was to compare between two different types of diverting stoma (loop ileostomy and transverse colostomy) as regard immediate and remote complications in patient with rectal cancer treated by restorative resection.

**Methods:** A prospective randomized comparative clinical study was conducted on 50 patients who underwent anterior resection and low anterior resection for rectal cancer divided into two groups: Group I consisted of 25 patients who underwent by loop ileostomy. Group II consisted of 25 patients who underwent by loop transverse colostomy. All patients attended to surgical oncology unit of Sayed Galal hospital, Al Azhar University, Cairo, Egypt during the period from October 2018 to October 2019. Full history, routine, physical examination, routine and imaging investigations were done.

**Results:** 80% and 84% of loop ileostomy and transverse colostomy patients had anterior resection, respectively with no statistically significant differences between the two studied groups regarding anterior resection. Patient who treated by loop ileostomy had deceased time of closure ( $5.2 \pm 0.25$  weeks) and stay in hospital ( $5.16 \pm 1.65$  and  $3.29 \pm 0.55$  days) than those treated by transverse colostomy ( $9.6 \pm 0.37$  weeks) and ( $7.44 \pm 2.58$  and  $6.03 \pm 1.97$  days) respectively.

**Conclusions:** Egyptians have unique tumor characters and behavior, and different compliance with treatment regimens. Multicenter prospective studies, as well as evolving Egyptian treatment guidelines are needed to address this.

**Keywords:** Complication, Colorectal cancer, Loop ileostomy, Rectal cancer, Restorative resection, Transverse colostomy

## INTRODUCTION

Colorectal cancer (CRC) is the third most common cancer worldwide after lung and breast cancers with two-thirds of all CRCs occurring in the more developed regions of the world. CRC affects men and women of all racial and ethnic groups and is the most often found in those aged 50 years or older. Colonoscopy plays a central

role in the detection and prevention of CRC.<sup>1</sup> Most CRC occurs due to lifestyle and increase age with only a minority of cases associated with underlying genetic disorders and environmental factors enables us to move in the direction of a complete assessment of disease risk. It typically starts in the lining of the bowel and if left untreated, can grow into the muscle layers underneath and then through the bowel wall.<sup>2</sup>

Complications are usually classified according to onset to early or late and in relation to surgical procedure after construction take down. This policy should also be adopted in the emergency. Accurate preoperative stoma siting is setting, where the incidence of complications is possibly higher.<sup>3</sup> Anastomotic leakage is one of the most important surgical complications of colorectal surgery. It has been of great concern because of high occurrence of morbidity and mortality, which affect long-term survival. The use of a protective stoma should be considered in relation to specific conditions involving. The operation colorectal carcinoma or other situations such as; when the patient's initial condition is poor. After neoadjuvant radio-chemotherapy, after total meso rectal excision, or with long-duration operation.<sup>4</sup>

The proximal diversion, by means of either a colostomy or an ileostomy, minimizes the consequences of anastomotic leakage, by preventing fecal flow through the anastomosis. The defunctioning loop stoma decreases the rate of anastomotic leakage.<sup>5</sup> Colostomy, ever since it was first constructed successfully in 1776 has always been associated with a significant complication rate. The morbidity rate and the mortality rate directly related to colostomy is about 1%. The majority of complications after colostomy are related to its site and type, size of the opening in the abdominal wall and control of infection. The most common complications retraction and stenosis of the stoma, followed by skin irritation, excoriation, infection and prolapse. The complication rate is higher in emergency cases than elective cases in the elderly and children than in the adults, and more in end colostomy than loop colostomy.<sup>6</sup>

The most common complications reported in ileostomy are peristomal skin irritation and erythema followed by laparotomy wound infection and peristomal skin infection, abscess formation and fistula formation. Peristomal irritation peristomal skin erythema as the most common complication in 42%. Skin excoriation in 18% cases skin erythema in 12% followed by prolapsed (6%) and retraction (4%). Apart from these peristomal complications, the systemic complications like electrolyte disturbances, gaping of the main wound and fecal fistula.<sup>7</sup> The aim of the study was to compare between two different types of diverting stoma (loop ileostomy and transverse colostomy) as regard immediate and remote complications in patient with rectal cancer treated by restorative resection.

## METHODS

A prospective randomized comparative clinical study was conducted on 50 patients who underwent anterior resection and low anterior resection for rectal cancer. All patients attended to surgical oncology unit of Sayed Galal Hospital, Al Azhar University, Cairo, Egypt, during the period from October 2018 to October 2019. All the studied patients divided into two groups which are as follows.

Group I consisted of 25 patients who underwent loop ileostomy; Group II consisted of 25 patients who underwent loop transverse colostomy.

### *Ethical consideration*

All participants were volunteers. All of them signed a written informed consent that explains the aim of study before the study initiation. Approval will be obtained from ethical committee in Sayed Galal hospital, Al Azhar University, Faculty of Medicine from the surgical oncology unit.

### *Inclusion criteria*

Patients with proven histopathology of rectal carcinoma and patients planned to be treated by covering stoma (loop ileostomy or transverse colostomy).

### *Exclusion criteria*

Patients with advanced disease or those with metastatic disease and patients unfit for major surgery or with major co-morbidities, obstructed and perforated tumors and patients with permanent colostomy or ileostomy.

All patients who fulfill the eligibility criteria were subjected to history taking with emphasis on name age, gender, indications, type of stoma, and type of surgery. General examination to exclude any medical disease with special attention to blood pressure, pulse and temperature. Abdominal examination which included digital rectal examination (PR) and vaginal examination (PV) in female. Vital signs which included pulse, blood pressure, temperature, and respiratory rate were recorded in every patient. Colonoscopic examination and biopsy; routine laboratory investigations which included the following investigation as complete blood count, kidney function tests, liver function tests and blood glucose levels (fasting and postprandial). Electro-cardiogram and echocardiography for imaging investigations as plain chest-X-ray to exclude metastasis, and as a part of patient general evaluation; pelvic abdominal ultrasound is the study of choice for primary evaluation of abdominopelvic lesion; pelvic abdominal CT with oral and IV contrast to assess for any sites of disease recurrence prior to reversal; flexible sigmoidoscopy to assess the anastomosis endoscopically to ensure that this has healed. Barium enema and per stoma contrast study to assess the anastomosis radiologically to ensure that there are no leaks and to ensure that this has healed and magnetic resonance imaging rectal protocol and colonoscopy.

### *Preoperative preparation*

All elective patients were prepared preoperatively in the usual manner as a standard mechanical cathartic bowel preparation on the day prior to the surgery (using poly ethylene glycol, in addition both oral and parenteral broad-spectrum prophylactic antibiotics was administered

in the form of 1 gm neomycin and 1 gm metronidazole by mouth at 2:00 pm and 7:00 pm one day before surgery and approximately 30 minutes before surgery the patient receives 1gm cefotaxime. Prophylactic measures against venous thrombosis will be taken according to the patient's risk in the form of elastic stockings.

### Anaesthesia

All patients were receiving general anaesthesia. Nasogastric tube and Foley's catheter was inserted together with elastic stockings for prophylaxis against lower limb deep vein thrombosis.

Comparison between loop ileostomy and transverse colostomy was done for operative details (first surgery-resection) which included operative time, blood loss, metabolic complication, damage or injury to nearby organs high output stoma, time to tolerating oral feeding and length of hospital stay.

Complications which included prolapse, skin irritation and inflammation, retraction, parastomal hernia and stoma stricture as intraoperative and post-operative complications.

### Operative details of second surgery (closure of stoma)

#### Preoperative preparation

Preoperative admission, time and blood loss.

#### Complications of stoma reversal

Including wound infection, bleeding, ileus, bowel obstruction, leak, fistula, and incisional hernia, ICU stay.

#### Closure of stoma

Intraoperative and post-operative complication.

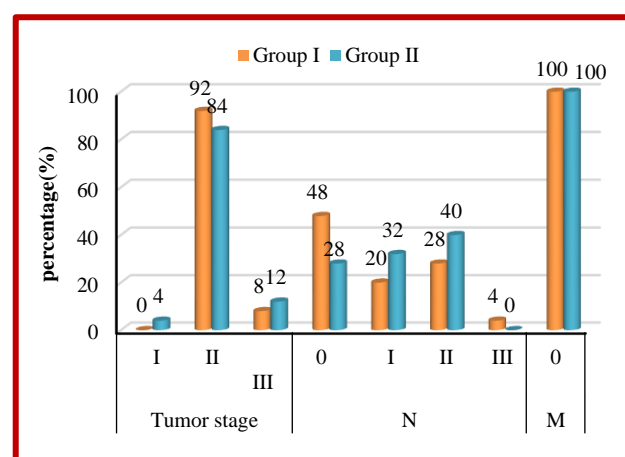
### Statistical analysis

Results were tabulated and statistically analyzed by using a personal computer using Microsoft Excel 2016 and

SPSS v. 21 (SPSS Inc., Chicago, IL, USA). Statistical analysis was done using descriptive e.g., percentage (%), mean and standard deviation. Student's t-test, Chi-Squared ( $\chi^2$ ), Fisher's exact test A value of p less than 0.05 was considered statistically significant.

### RESULTS

Results showed that most of the studied groups were males. Age of them ranged from 26-68 years with mean age  $49.72 \pm 11.66$  years in group I and  $49.80 \pm 9.12$  years in group II. There was no statistically significant difference between the two studied group regarding sex ( $p=0.529$ ) and age ( $p=0.979$ ) (Table 1).



**Figure 1: Distribution of the studied groups regarding stage of cancer.**

The current study shows that, upper 1/3 rectum was the most site of cancer common among the studied group (80% in group I and 84% in group II), but there was no statistically significant difference between the two studied group regarding site of cancer (Table 2). Cancer at stage T (II) was the most frequency among the studied group (92% in group I and 84% in group II). While, 48% of the group I were not in stage N and 40% of group II were in stage II. While there were no cases in stage M, but there was no statistically significant difference between the two studied group regarding stages of cancer (Figure 1).

**Table 1: Comparison between the two studied groups according to demographic data.**

	Group I (n=25)		Group II (n=25)		Test of sig.	P value
	N	%	N	%		
<b>Gender</b>						
Male	19	76.0	17	68.0	$\chi^2=0.397$	0.529
Female	6	24.0	8	32.0		
<b>Age (in years)</b>						
Min.-Max.	26.0-66.0		30.0-68.0		t=0.027	0.979
Mean±SD.	49.72±11.66		49.80±9.12			
Median	51.0		50.0			

Group I: Loop ileostomy; Group II: transverse colostomy;  $\chi^2$ : Chi square test; t: Student t-test; P: p value for comparing between the two studied groups.

**Table 2: Comparison between the two studied groups according to site of cancer.**

Site of cancer	Group I (n=25)		Group II (n=25)		$\chi^2$	P value
	N	%	N	%		
Upper 1/3 rectum	20	80.0	21	84.0	0.136	1.000
Middle 1/3 rectum	5	20.0	4	16.0		

$\chi^2$ : Chi square test; P: p value for comparing between the two studied groups calculated by Fisher exact test; Group I: Loop ileostomy; Group II: Transverse colostomy.

**Table 3: Comparison between the two studied groups according to anterior resection.**

	Group I (n=25)		Group II (n=25)		$\chi^2$	P value
	No.	%	No.	%		
<b>Anterior resection</b>						
Yes	20	80.0	21	84.0	1.67	0.831
No	5	20.0	4	16.0		

Group I: Loop ileostomy; Group II: Transverse colostomy; ASA: American Society of Anesthesiologists;  $\chi^2$ : Chi square test; NA: Not comparable; P: p value for comparing between the two studied groups.

**Table 4: Comparison between the two studied groups according to time of closure and stay in hospital.**

		Group I (n=25)	Group II (n=25)	Test of sig.	P value
Time of closure (weeks)					
Min.-Max.		6.0-8.0	10.0-12.0	t=9.771*	<0.001*
Mean±SD.		5.2±0.25	9.6±0.37		
Time of stay in hospital (days)					
Min.-Max.	1st operation	3.0-10.0	5.0-13.0	U=122.0*	<0.001*
		5.16±1.65	7.44±2.58		
Mean±S.D.	2 <sup>nd</sup> closure	4.0-11.0	4.0-15.0	U=87.0*	<0.001*
Median		3.29±0.55	6.03±1.97		

Group I: Loop ileostomy; Group II: Transverse colostomy; U: Mann Whitney test; t: Student t-test; P: p value for comparing between the two studied groups; \*: Statistically significant at p≤0.05.

**Table 5: Comparison between the two studied groups according to complications.**

Complications	Group I (n=25)		Group II (n=25)		$\chi^2$	P value
	N	%	N	%		
Leakage	1	4.0	2	8.0	1.495	0.417
Metabolic complication (hypokalemia, hyperkalemia, metabolic acidosis, hyponatremia)	3	12.0	0	0.0	3.191	0.235
Ileus	2	8.0	2	8.0	2.0	0.349
Bowel obstruction	0	0.0	3	12.0	3.191	0.235
Wound infection	2	8.0	5	20.0	1.495	0.417
Skin irritation and inflammation	6	24.0	2	8.0	3.388	0.138
Parastomal hernia	1	4.0	1	4.0	0.0	1.000
Stoma stricture	1	4.0	1	4.0	0.0	1.000
Stoma prolapse	1	4.0	2	8.0	0.355	1.000
Pre-operative 2 <sup>nd</sup> preparation closure	0	0.0	25	100	50.0	<0.001*

Group I: Loop ileostomy; Group II: Transverse colostomy;  $\chi^2$ : Chi square test; P: p value for comparing between the two studied groups calculated by Fisher exact test; \*: Statistically significant at p≤0.05.

Also, 80% and 84% of loop ileostomy and transverse colostomy patients had anterior resection, respectively with no statistically significant differences between the two studied groups regarding anterior resection (Table 3).

In addition to, there was highly statistically significant difference between the studied patients regarding time of closure and stay in hospital. Patient who treated by loop ileostomy had decreased time of closure (5.2±0.25 weeks) and stay in hospital (5.16±1.65 and 3.29±0.55 days) than those treated by transverse colostomy (9.6±0.37 weeks)

and ( $7.44 \pm 2.58$  and  $6.03 \pm 1.97$  days), respectively (Table 4).

Regarding the complication, the present study showed that, the patients treated by loop ileostomy had lower rate of leakage (4%), wound infection (8%), stoma prolapse (4%) and hadn't bowel obstruction and pre-operative 2<sup>nd</sup> preparation closure related complications than the patients treated by loop transverse colostomy. While, wound infection was the most frequent complication (20%) in the loop transverse colostomy group, followed by bowel obstruction (12%) and stoma prolapse (8%) (Table 5).

## DISCUSSION

In the current study, most of the studied groups were males. Age of them ranged from 26-68 years with mean age  $49.72 \pm 11.66$  years in group I and  $49.80 \pm 9.12$  years in group II. There was no statistically significant difference between the two studied group regarding sex, age and site of tumor. These agree with Ali included 28 patients suffering from mid- or low-rectal cancer who underwent elective low anterior resection.<sup>8</sup> They found that patients included in this study were comparable and there were no significant differences in demographic data between the two groups such as gender, age. Also, in the study by Kawada et al found that there were almost equal numbers of men and women in this study, 62 and 64, respectively; however, there were more women in the transverse colostomy group than in the loop ileostomy group (43 and 21, respectively [ $P < 0.001$ ]).<sup>9</sup> While, Sun et al studied 288 patients who underwent anterior resection of rectal cancer with preventative loop ileostomy or loop transverse colostomy.<sup>10</sup> They found that the propensity score-matched loop ileostomy group ( $n=66$ ) and the loop transverse colostomy group ( $n=111$ ) were comparable in-patient demographic and baseline characteristics.

The current study indicated that most of the studied patient had tumor stage (II) (92% in group I and 84% in group II). Also, 80% and 84% of loop ileostomy and transverse colostomy patients had anterior resection, respectively with no statistically significant differences between the two studied groups regarding anterior resection. Semi results confirmed by Sun et al who found that 59 (71.95) of loop ileostomy had ASA score (II), followed by 15 (18.29) had grad I and 8 (9.76) patients had grad III.<sup>10</sup> While, in loop transverse colostomy group, 143 (69.42) had II, followed by 53 (25.73) had grad I and 10 (4.85) patients had grad III. While, 36 (43.90%) of loop ileostomy had tumor stage III and 80 (38.83%) of loop transverse patients had tumor stage II.

In the present study, there was highly statistically significant difference between the studied patients regarding time of closure and stay in hospital. Patient who treated by loop ileostomy had decreased time of closure ( $5.2 \pm 0.25$  weeks) and stay in hospital ( $5.16 \pm 1.65$  and  $3.29 \pm 0.55$  days) than those treated by transverse

colostomy ( $9.6 \pm 0.37$  weeks) and ( $7.44 \pm 2.58$  and  $6.03 \pm 1.97$  days), respectively. These result in agreement with Ali who found that the mean time between stoma construction and closure was  $90 \pm 12$  days for loop transverse colostomy group and  $70 \pm 15$  days for loop ileostomy group.<sup>8</sup> The mean duration of loop ileostomy closure was  $60 \pm 12$  and for loop transverse colostomy was  $45 \pm 11$ . The mean cumulative total hospital stay was significantly longer in the loop transverse colostomy group than in the loop ileostomy group ( $p < 0.001$ ). Another study by Kaidar-Person et al found that the construction of loop ileostomy was associated with significantly higher incidence rate of skin excoriation than loop transverse colostomy which required prolonged dressings; needing more total hospital stay and more money expenditure.<sup>11</sup> This is probably due to the more aggressive behavior of small bowel feces. On the other hand, Sun et al studied 288 patients who underwent anterior resection of rectal cancer with preventative loop ileostomy or loop transverse colostomy.<sup>10</sup> They found that mean length of hospital stay was  $7.3 \pm 3.30$  days in patients treated by loop ileostomy and  $6.8 \pm 0.97$  in patients treated by loop transverse colostomy.

Results of the present study showed that the patients treated by loop ileostomy had lower rate of leakage (4%), wound infection (8%), stoma prolapse (4%) and hadn't bowel obstruction and pre-operative 2<sup>nd</sup> preparation closure related complications than the patients treated by loop transverse colostomy. While, wound infection was the most frequent complication (20%) in the loop transverse colostomy group, followed by bowel obstruction (12%) and stoma prolapse (8%). These agreed with Kumar et al who found that there was a significantly higher incidence rate of leakage of liquid stool after loss of the seal of the ileostomy bag than that of the colostomy bag thus making patients suffer more of financial problems pressing more also towards early closure of the stoma which may not be applicable when there is a risk of permanent stoma.<sup>12,13</sup> Another study by Fazekas et al reported a significantly higher incidence of small intestinal obstruction with loop ileostomy group of patients rather than the loop transverse colostomy group (31% vs. 7%) which is in accordance with other studies.<sup>14,15</sup> Small intestinal obstruction before loop ileostomy closure has been reported to be due to adhesions adjacent to the stoma, increase the chance of twisting the small intestine, retraction of loop ileostomy and herniation of proximal bowel lateral to the ileostomy.<sup>16</sup>

The occurrence of small bowel obstruction, associated with loop ileostomy, in present study is greater (34%) than that reported in literature of 1.2-14%, as these studies have reported only those patients that subsequently required re-operation after closure of the covering loop ileostomy.<sup>17</sup> Some authors showed that loop ileostomy had fewer stoma-related complications and fewer stoma reversal associated infections and incisional hernia than loop transverse colostomy.<sup>18,19</sup>



Some others found that, compared to loop ileostomy, loop transverse colostomy patients were more readily predisposed to develop stoma-related complications such as irritant dermatitis and electrolyte disorders.<sup>7</sup>

The intestinal mucosa, especially in the proximal colon where absorption mainly occurs, could not effectively absorb and transport water and vitamins as a result of deficiency of short chain fatty acids.<sup>20</sup> Loop ileostomy and loop transverse colostomy differ in anatomic position and the difference in the extent of diverted colon may explain the higher rate of diarrhoea in loop ileostomy patients during the stoma reversal perioperative period. Low anterior resection syndrome is another possible contributory cause to diarrhoea, but it has no clear correlation with stoma position.<sup>21</sup> Another author has advocated that loop ileostomy is best for temporary diversion because of its ease of construction and management and the infrequency of complications.<sup>22</sup> Others support routine use of transverse colostomy, claiming fewer complications from this procedure. The lack of agreement between these studies may be due to any number of variables regarding patient background (diagnosis, general conditions) and operative factors (procedures and timing of surgery).<sup>15</sup> Furthermore, several studies either failed to directly compare the 2 options or compared the techniques but did not assure equal surgeon experience with both.<sup>23-25</sup> The reports that did provide direct comparisons contained relatively small numbers of patients in each group. This case-matched study was undertaken to help resolve this conflict. Because our findings indicate little difference between transverse colostomy and loop ileostomy in terms of complications and safety, surgeons should select the procedure with which they are most familiar. Alternatively, the stoma should be chosen because of the stoma-related complications.<sup>26</sup>

## CONCLUSION

Both transverse colostomy and loop ileostomy were associated with surprisingly few complications in stoma closure. A few reports have described such high rates of stoma closure complications to discourage the use of faecal diversion for protecting low rectal or coloanal anastomosis. Loop transverse colostomy and loop ileostomy; both have advantages and disadvantages and the use of any for faecal diversion after low and mid-rectal carcinoma should be considered for every patient individually according to his circumstances. Finally, Egyptians have unique tumor characters and behavior, and different compliance with treatment regimens. Multicenter prospective studies, as well as evolving Egyptian treatment guidelines are needed to address this.

## ACKNOWLEDGEMENTS

We are thankful to all staff of Surgical Oncology department, Faculty of Medicine, Al Azhar University, Cairo, Egypt.

*Funding: No funding sources*

*Conflict of interest: None declared*

*Ethical approval: The study was approved by the Institutional Ethics Committee*

## REFERENCES

1. Gohar SF, Al Hassanin SA, El-Assal M, Hussein AM. Clinico-epidemiology study of colorectal cancer in Menoufia University Oncology Department. Age. 2015;44(5):21-5.
2. Kidane B, Chadi SA, Kanter S, Colquhoun PH, Ott MC. Local resection compared with radical resection in the treatment of T1N0M0 rectal adenocarcinoma: a systematic review and meta-analysis. Dis Colon Rectum. 2015;58(1):122-140.
3. Salvadalena G, Hendren S, McKenna L, Muldoon R, Netsch D, Paquette I, et al. WOCN Society and AUA position statement on preoperative stoma site marking for patients undergoing urostomy surgery. J Wound Ostomy Continence Nurs. 2015;42(3):253-6.
4. Arnold M, Sierra MS, Laversanne M, Soerjomataram I, Jemal A, Bray F. Global patterns and trends in colorectal cancer incidence and mortality. Gut. 2017;66(4):683-91.
5. Liu Y, Luan L, Wang X. A randomized Phase II clinical study of combining panitumumab and bevacizumab, plus irinotecan, 5-fluorouracil, and leucovorin (FOLFIRI) compared with FOLFIRI alone as second-line treatment for patients with metastatic colorectal cancer and KRAS mutation. Onco Targets Therap. 2015;8:1061-8.
6. Shabbir MN, Memon ZA, Nizami M, Khanzada RI. Colostomy related complications. Pakistan J Surg. 2014;24(2):102-4.
7. Manzenreiter L, Spaun G, Weitzendorfer M, Luketina R, Antoniou SA, Wundsam H, et al. A proposal for a tailored approach to diverting ostomy for colorectal anastomosis. Minerva Chirurgica. 2018;73(1):29-35.
8. Ali AM. Loop transverse colostomy versus loop ileostomy after low and ultralow anterior resection. Int Surg J. 2018;5(16):33-9.
9. Kawada K, Hasegawa S, Wada T, Takahashi R, Hisamori S, Hida K, et al. Evaluation of intestinal perfusion by ICG fluorescence imaging in laparoscopic colorectal surgery with DST anastomosis. Surgical Endoscop. 2017;31(3):1061-9.
10. Sun X, Han H, Qiu H, Wu B, Lin G, Niu B, et al. Comparison of safety of loop ileostomy and loop transverse colostomy for low-lying rectal cancer patients undergoing anterior resection: A retrospective, single institute, propensity score-matched study. J BUON. 2019;24(1):123-9.
11. Kaidar-Person O, Person B, Wexner SD. Complications of Construction and Closure of Temporary Loop Ileostomy. J Am Coll Surg. 2005;20(1):759-73.

12. Kumar V L, Sathyanarayana KV. A comparative study between Santulli ileostomy and loop ileostomy. (IOSR-JDMS). 2016;15:36-40.
13. Lindgren R, Hallbook O, Rutegard J, Sjudahl R, Matthiessen P. What is the risk for a permanent stoma after low anterior resection of the rectum for cancer? A six-year follow-up of a multicenter trial. *Dis Colon Rectum*. 2011;54:41-7.
14. Fazekas B, Hendricks J, Smart N, Arulampalam T. The incidence of incisional hernias following ileostomy reversal in colorectal cancer patients treated with anterior resection. *Ann R Coll Surg Engl*. 2017;99:319-24.
15. Gooszen AW, Geelkerken RH, Hermans J, Lagaay MB, Gooszen HG. Temporary decompression after colorectal surgery: randomized comparison of loop ileostomy and loop colostomy. *Br J Surg*. 1998;85:76-9.
16. Metcalf MA, Dozois RR, Beart RW, Wolff BG. Temporary ileostomy for ileal pouch anal anastomosis: Functions and complications. *Dis Colon Rect*. 1986;29:300-3.
17. Rullier E, Letoux N, Laurant C, Garrelon JL, Parneix M, Saric J. Loop ileostomy vs loop colostomy for defunctioning low anastomosis during rectal cancer surgery. *World J Surg*. 2001;25:274-7.
18. Klink CD, Lioupis K, Binnebosel M, Kaemmer D, Kozubek I, Grommes J. Diversion stoma after colorectal surgery: loop colostomy or ileostomy. *Int J Colorectal Dis*. 2011;26:431-6.
19. Whitehead A, Cataldo PA. Technical Considerations in Stoma Creation. *Clin Colon Rectal Surg*. 2017;30:162-71.
20. Arthur C, Guyton JEH. *Textbook of Medical Physiology* (11th edn). Philadelphia, Penn-sylvania: Saunders Elsevier; 2006.
21. Bryant CL, Lunniss PJ, Knowles CH. Anterior resection syndrome. *Lancet Oncol*. 2012;13:403-8.
22. Khoo RE, Cohen MM, Chapman GM. Loop ileostomy for temporary fecal diversion. *Am J Surg*. 1994;167:519-22.
23. Riesener KP, Lehnen W, Hofer M, Kasperk R, Braun JC, Schumpelick V. Morbidity of ileostomy and colostomy closure: impact of surgical technique and perioperative treatment. *World J Surg*. 1997;21(1):103-8.
24. Senapati A, Nicholls RJ, Ritchie JK. Temporary loop ileostomy for restorative proctocolectomy. *Br J Surg*. 1993;80:628-30.
25. van de Pavoordt HDWM, Fazio VW, Jagelman DG. The outcome of loop ileostomy closure in 293 cases. *Int J Colorectal Dis*. 1987;2:214-7.
26. Chen F, Stuart M. The morbidity of defunctioning stomata. *Aust NZJ Surg*. 1996;66:218-21.

**Cite this article as:** Bendary SH, El Sheikh AET, Ramadan MK. Loop ileostomy versus transverse colostomy as a covering stoma after anterior resection for rectal cancer. *Int Surg J* 2019;6:4216-22.