

## Original Research Article

# Pre-tertiary hospital management of neoplastic neck lumps in adults: the need for an appraisal in North Western Nigeria

Abdullahi Mohammed\*, Kufre R. Iseh, Stanley B. Amutta, Aliyu Daniel

Department of Otorhinolaryngology, Usmanu Danfodiyo University Teaching Hospital, Sokoto, Nigeria

**Received:** 30 September 2019

**Accepted:** 08 November 2019

### \*Correspondence:

Dr. Abdullahi Mohammed,

E-mail: mabdullahi7174@gmail.com

**Copyright:** © the author(s), publisher and licensee Medip Academy. This is an open-access article distributed under the terms of the Creative Commons Attribution Non-Commercial License, which permits unrestricted non-commercial use, distribution, and reproduction in any medium, provided the original work is properly cited.

## ABSTRACT

**Background:** Pathologies in the head and neck sites may manifest as neck lumps, which is an important prognostic significance in the management. The aim of the study was to describe the pre-tertiary hospital management of adult patients with neoplastic neck lumps.

**Methods:** This was a retrospective study of all the patients managed for neoplastic neck lumps from September 2008 to September 2018, at the Department of Otorhinolaryngology, Usmanu Danfodiyo University Teaching Hospital, Sokoto, Nigeria.

**Results:** A total of 118 patients were included in the study. The age ranged from 16-83 years (mean age;  $42.3 \pm 16.7$  years). Majority of the patients 71 (60.2%) were of lower socioeconomic status. Duration of neck swellings was between 3-240 months with an overall mean duration of 30.2 months (mean duration for benign and malignant neck masses respectively;  $100 \pm 56$  and  $20.1 \pm 47.1$  months). Malignant neck lumps 103 (87.3%) constituted most of the neck lumps, and of these, 91 (77.1%) were metastatic neck lumps. Patients delay 94 (79.7%), and professionals delay 24 (20.3%) were responsible for advanced primary head and neck neoplasia and their metastatic deposits. Eighty-seven (73.7%) patients were managed at the tertiary hospital: fifty-two (59.8%) were successfully discharged and were lost to follow up within six months after the intervention. Thirty-five (40.2%) patients died during treatment and 31 (26.3%) signed against medical advice.

**Conclusions:** Malignant lumps, mainly the metastatic neck disease, are common in adults. The notable contributory factors for delay presentation can be preventable through creating public awareness and the improvement of socioeconomic status.

**Keywords:** Neck lumps, Pre-tertiary hospital treatment, Late presentation

## INTRODUCTION

Benign, malignant head and neck pathologies are usually manifest externally as neck lump(s).<sup>1</sup> Neck lumps in adults are mostly metastatic neck disease located commonly in the lateral aspect of the neck in patients over 40 years.<sup>2-7</sup> The less common benign tumours arise from the thyroid and salivary glands.<sup>1,7</sup>

Neoplastic neck lumps in adults are usually asymptomatic.<sup>8-11</sup> Open biopsy on adult neck lump

increases the risk of tumour upstaging, the tendency for recurrence, fungation and tumour seedling. Hence, this form of evaluation is usually avoided for metastatic neck disease with the primary site in the head and neck, and in a few benign neck lump(s) such as pleomorphic adenoma of the parotid gland.<sup>6,8,12</sup>

In developing countries, delayed presentation of patients with head and neck pathologies is common.<sup>13,14</sup> This is attributed to the high poverty rate; patient tend to patronize traditional healers, who performs various

unorthodox procedures on the neck lump, self-medication with antibiotics, and coupled with the role played by the medical professionals; all these factors contribute to the poor outcome of both the primary and secondary head and neoplastic neck pathologies.<sup>15-17</sup>

There is a dearth of information on the pre-tertiary hospital management of adults with neoplastic neck lumps.

This study aims to describe the roles of adult patients and health professionals in pre-tertiary hospital management of neoplastic neck lumps.

## METHODS

A retrospective review of patients with neoplastic neck lumps, who presented to the Department of Otorhinolaryngology, Usmanu Danfodiyo University Teaching Hospital, Sokoto, Nigeria, from September 2008 to September 2018. Data retrieved from the clinical records include demographic characteristics, the socioeconomic status based on the patient's occupation and the level of educational attainment: Social class 1 and 2 signifies upper class, social class 3 represent the middle class, while the social class 4 and 5 (lower socioeconomic status).<sup>18</sup> Other data retrieved include the reasons for delayed presentation, pre-tertiary hospital treatments, the treatment offered at the tertiary health centre and the outcome

Inclusive criteria include patients aged 16 and above and those with neoplastic neck lumps. Excluded from the study were patients below 16 years and the non-neoplastic neck lumps.

Data were analyzed using SPSS version 23. Fisher's exact test was used to determine the statistical significance between genders that received pre-tertiary hospital treatment and the relation between age group and the primary head and neck sites. We set statistical significance at a  $p < 0.05$ .

## RESULTS

In the period under review, we recorded 118 patients: 71 males and 47 females (M: F = 1.5:1). The age ranged from 16-83 years (mean age,  $42 \pm 16.7$  years). Majority of the patients 71 (60.2%) were of lower socioeconomic status. The duration of the neck lumps was between 3-240 months with a mean duration of 30.2 months ( $100 \pm 56$  and  $20.1 \pm 47.1$  months for means duration of benign and malignant neck lumps respectively).

Malignant neck lumps 103 (87.3%) constituted the majority of the neck lumps, occurring mostly in males 63 (61.2%), and of these, 91 (88.3%) were metastatic neck lumps (90.5%  $\geq 6$  cm in its greatest diameter). The pharynx was the main primary head and neck site 91 (77.1%) which give rise to most of the metastatic neck

lumps: nasopharyngeal 40 (44%), oropharyngeal 35 (38.5%) and hypopharyngeal 16 (17.6%) regions as shown in Table 1. Other malignant neck lumps include those arising from the parotid salivary gland 3 (2.9%), thyroid gland 7 (6.8%), from cervical lymph nodes and submandibular gland 1 (0.8%) respectively. Grouping the patient ages into two groups:  $>40$  and  $<40$  years; there is no significant statistical association between malignant neck lumps and the age groups ( $p = 0.4$ ) as shown in Table 1.

**Table 1: Primary head and neck sites for neck lumps in relation to age.**

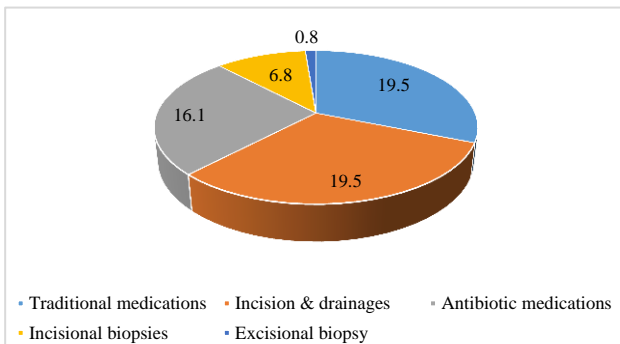
Primary SNL (n=118)	Age (years)		P value
	$\geq 40$	$\leq 40$	
<b>Nasopharynx (40)</b>			1
Males	13	18	
Females	4	5	
<b>Oropharynx (35)</b>			0.289
Male	14	4	
Female	10	7	
<b>Hypopharynx (16)</b>			0.518
Male	9	1	
Female	4	2	
<b>Parotid gland (13)</b>			0.103
Male	1	5	
Female	5	2	
<b>Thyroid (8)</b>			1
Male	1	1	
Female	3	3	
<b>Submandibular gland (5)</b>			1
Male	-	2	
Female	1	2	
<b>Lymph node (1)</b>			
Male	-	1	
Female			
<b>Total</b>	65 (55.1%)	53 (44.9%)	-

Benign neck lumps 16 (13.5%) aroused from the parotid gland 10 (62.5%), submandibular gland 5 (31.5%) and the thyroid gland 1 (6.3%).

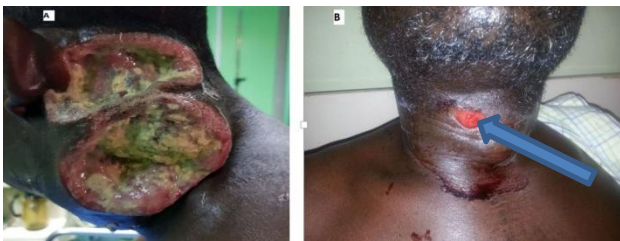Persistent symptoms from the primary head and neck cancer sites 69 (58.5%), were the main reason why patients seek medical attention, and the other reasons include the unsightly appearance of the neck lumps 43 (36.4%) and ulceration and bleeding from the neck lumps 6 (5.1%).

Patients delay 94 (79.7%) were mostly responsible for primary head and neck advanced neoplasia and their metastatic deposits. The reasons for late presentation includes, Painless neck lumps 43 (36.4%), financial constraints 28 (23.7%), and neck lumps attributed to spiritual cause 23 (19.5%). Professionals delay accounted for 24 (20.3%).

Pre-tertiary hospital treatment (Figure 1) was recorded in 73 (61.9%) patients with neck lumps. Over-the-counter antibiotic self-medication 41 (56.2%) was recorded in the majority of the patients, this was followed by traditional healers 23 (31.5%) incision and drainages (Figure 2) and the application of traditional concoction on the incised neck lumps. Other pre-tertiary hospital treatments included the procedures carried out by the non-specialist head and neck surgeons: incisional biopsies 8 (11%) on the metastatic neck lumps and an excisional biopsy of the parotid pleomorphic adenoma with recurrence, four years after the procedure. There was no statistical significance between the two genders ( $p=0.437$ ) that received pre-tertiary hospital treatment.



**Figure 1: Pre-tertiary hospital treatment (%).**



**Figure 2: Male patients with cervical lymphoma with cutaneous ulceration initiated by traditional healer's incision and drainage (A) and (B) papillary thyroid carcinoma with site of incision and drainage (arrow) made by the traditional healer.**

Eighty-seven (73.7%) patients received treatment at the tertiary hospital: primary chemoradiation 56 (64.4%), surgery alone 15 (17.2%), surgery combined with chemotherapy +radiotherapy 8 (9.2%), and chemotherapy alone 8 (6.8%). Thirty-one patients (26.3%) signed against medical advice.

Fifty-two (59.8%) patients were successfully discharged but were later lost to follow up within six months after the intervention. Thirty-five (40.2%) patients died during the treatments.

## DISCUSSION

Neoplastic lesions in the primary head and neck sites, manifest as neck lump(s).<sup>2-10</sup> This manifestation is

commonly seen in adults especially those above 40 years.<sup>2-7</sup> Majority of our patients in the period under review, were above 40 years, which agrees with the previous studies.<sup>2-4,7</sup>

Regional metastatic lymphadenopathy from the primary head and neck neoplasia indicates an aggressive tumour and also a secondary index of the systemic tumour burden; this greatly affects the prognosis.<sup>12</sup> Painless cervical metastatic lumps are the commonest head and neck lumps in adults, and it is prone to misdiagnosis.<sup>2,6,17</sup> This explained why 87.3% of the neck lumps, were of painless malignant neck lumps noted in this present study.

The pharyngeal cancers have a poor prognosis compared to other head and neck malignancies and it is one of the main primary sites for metastatic neck disease.<sup>6,19</sup> Depending on the subsites, the regional metastatic lymphadenopathies occurs in the first five levels.<sup>3,6</sup> In this present study, pharynx (77.1%) was the main primary site for metastatic neck lump; commonly from the nasopharynx (33.9%) followed by the oropharynx (29.7%). This finding was like the study by Abraham et al, 67.2% were metastatic lymph nodes, and the primary cancers occurs commonly from the nasopharynx (21.31%) and oropharynx (21.31%).<sup>20</sup>

Benign neck lumps are less common in adults.<sup>2,6</sup> However, benign tumours arising from the thyroid and salivary glands, are relatively commonly seen in adults.<sup>1,7</sup> This could explain the similar findings of benign tumours of the thyroid and salivary glands in this study.

Delay in diagnosis for patients with malignant neck lumps is common.<sup>2,17</sup> The reported average diagnostic delays were between 3-6 months for head and neck squamous cell carcinoma with metastatic neck masses.<sup>2</sup> In contrast to this study, the average duration recorded included all the malignant neck lumps. Patient and professional delays are recognized factors involved in the delay for making a definitive diagnosis for malignant neck lumps, hence a poor prognostic treatment outcome.<sup>2,17,21</sup> Patients delay were attributed to taking alternative medications, ignorance of clinical features of head and neck cancers, illiteracy and low socioeconomic status.<sup>2</sup> The professional delay includes the delay and failure to make a definitive diagnosis.<sup>21</sup> In this study, factors responsible for delay presentation in patients with neoplastic neck lump are mostly patients related. In contrast, Lee et al reported that patients delay was mostly physician-related (71%).<sup>21</sup>

Poverty is a common problem in Africa, thus allowing patients to seek alternative treatment for their illness.<sup>15</sup> Alternative treatment includes the use of over-the-counter prescription and patronization of traditional healers.<sup>15,22</sup> Manipulations of the metastatic neck lumps in the form of incision and drainage and incisional biopsy, carried out by the traditional healer and the non-specialist head and

neck surgeon respectively was noted in this present study. This practice has a grave consequence to the overall outcome of management metastatic neck lumps.

In this study, we noted some preventable factors that contributed to delay presentation in patients with neoplastic neck lump; low socioeconomic status, self-medication with over the counter antibiotics, neglect of grievous painless neck lump especially for patients over 40 years, pre-treatment management by the traditional healers and the non-specialist head and neck surgeon. These undesirable factors can be avoided by patients' health education and continuing medical education for non-specialist health professionals.

#### **Limitation of the study**

A single centre retrospective study, with a small sample size. A multicenter prospective study is needed to justify the aim of this present study.

#### **CONCLUSION**

Symptomless neck lump in adults is usually metastatic neck diseases. The identified factors for late presentation include low socioeconomic status, financial constraints, neglect of early symptom(s) and signs of the primary head and neck sites and their associated metastatic neck lumps, self-medication with over the counter antibiotics. Additionally, manipulation of the metastatic neck lumps by the traditional healers and the non-specialist head and neck surgeons: all these contributed to the advanced tumour presentations, and the inadequate follow up for these patients who eventually received treatment at the tertiary hospital contributed to the poor outcome. Creation of awareness for the patients, caregivers, traditional healers on the need to seek early treatment, while the non-specialist head and neck surgeons should be enlightened on the diagnosis of metastatic neck disease and the need for early referral to a specialist health institution.

*Funding: No funding sources*

*Conflict of interest: None declared*

*Ethical approval: Not required*

#### **REFERENCES**

1. Irani S, Bidari ZF, Sabeti S. Prevalence of Pathological Entities in Neck Masses: A Study of 1208 Consecutive Cases. *Avicenna J Dent Res.* 2016;8(1):e25614.
2. Pynnonen MA, Gillespie MB, Roman B, Rosenfeld RM, Tunkei DE, Bontempo L, et al. Clinical Practise Guideline:Evaluation of the Neck Masses in Adults. *Otolaryngol Head Neck Surg.* 2017;157(2\_suppl):S1-30.
3. Rosenberg TL, Brown JJ, Jefferson GD. Evaluating the adult patient with a neck mass. *Med Clin North Am.* 2010;94(5):1017-29.
4. Haynes J, Arnold KR, Aguirre-Oskins C, Chandra S. Evaluation of neck masses in adults. *AM Fam Physician.* 2015;91(10):698-706.
5. Gleeson M, Herbert A, Richard A. Management of lateral neck masses in adults. *Br Med J.* 2000;320(7248):1521-4.
6. Sheedy TM. Evaluating and Management of Adult Neck Masses. *Physician Assist Clin.* 2018;3:271-84.
7. Alnefae NM, AlQurashi Y, Saeedi TA, Alamri AA, Algethami M, Baabdullah W. A retrospective study of patients presenting with neck masses to a tertiary care center, Jeddah, Saudi Arabia. *Electronic Physician.* 2019;11(1):7431-40.
8. Roland NJ, Fenton J, Bhalla RK. Management of a lump in the neck. *Hosp Med.* 2001;62(4):205-9.
9. Jones AS, Cook JA, Phillips DE, Roland NR. Squamous carcinoma presenting as an enlarge lymph node. *Cancer.* 1993;72(5):1756-61.
10. Martin H, Romieu C. The diagnostic significances of a lump in the neck. *Postgrad Med.* 1952;11(16):491-500.
11. Paleri V, O'Hara. Metastatic neck disease. In: Watkinson CJ, Clarke WR, editors. *Scott-Brown's Otorhinolaryngology Head and Neck Surgery*, 8th ed. Taylor & Francis Group; 2019: 305-333.
12. Sheahan P, Shaha RA. Salivary gland tumours In: Watkinson CJ, Gilbert WR. *Stell & Muran's Textbook of Head and Neck Surgery and Oncology*, 5th ed. Holder & So toughton Ltd; 2012: 714-733.
13. Iseh RK, Abdullahi M, Aliyu JD, Amutta S, Yikawe SS, Solomon HJ. Clinical and histological pattern of oropharyngeal tumors in selected health institution in North Western Nigeria. *Int J Otolaryngol Head Neck Surg.* 2015;4:5-60.
14. Lilly-Tariah OB, Somefun AO, Adeyemo WL. Current evidence on the burden of head and neck cancers in Nigeria. *Head Neck Oncol.* 2009;1:14.
15. Abdullahi M, Baba SA. Head and neck complications from traditional surgeon's procedures: a tertiary health hospital experience in a developing country. *Int J Innovative Res Develop.* 2017;6(8):38-42.
16. Guggenheimer J, Verbin SR, Johnson TJ, Horkowitz AC, Myers NE. Factors delaying the diagnosis of oral and oropharyngeal carcinomas. *Cancer.* 1989;64:932-5.
17. Franco J, Elghouche AN, Harris MS, Kokoska MS. Diagnostic delays and errors in head and neck cancer patients: opportunities for improvement. *Am J Med Qual.* 2017;32:330-5.
18. Olusanya O, Okpere E, Ezimokhai M. The importance of social class in fertility control on a developing country. *West Afr J Med.* 1985;4:205-12.
19. Koivunen P, Rantala N, Hyrynkangas K, Jokinen K, Alho OP. The impact of patient and professional diagnostic delays on survival in pharyngeal cancer. *Cancer.* 2001;92(11):2885-91.
20. Abraham SZ, Mathias M, Mapondella BK, Kahinga AA, Ntunaguzi D, Massawe RE. Prevalence and

aetiology of neck masses among patients receiving surgical services at Muhimbili national Hospital, Tanzania. *Med J Zambia.* 2019;46(1):54-60.

21. Lee JJ, Dhepnorarrat C, Nyhof-Young J, Witterick I. Investigating patient and physician delays in the diagnosis of Head and Neck Cancers: a Canadian Perspective. *J Cancer Educ.* 2016;31(1):8-14.
22. World Health Organization: Traditional medicine strategy 200-2005. World Health Organization

Geneva: World Health Organization; 2002: WHO/EDM/TRM/2002.1.

**Cite this article as:** Mohammed A, Iseh KR, Amutta SB, Daniel A. Pre-tertiary hospital management of neoplastic neck lumps in adults: the need for an appraisal in North Western Nigeria. *Int Surg J* 2019;6:4261-5.