

## Original Research Article

# Surgical intervention using ellipse technique in treatment of gynecomastia

Mohamed Hamdy Elghotmy\*

Department of Intensive Care and Pain Management, Ministry of Health, Menoufia, Egypt

**Received:** 24 September 2019

**Revised:** 09 November 2019

**Accepted:** 13 November 2019

**\*Correspondence:**

Dr. Mohamed Hamdy Elghotmy,  
E-mail: [dr.muhamed.hamdy@gmail.com](mailto:dr.muhamed.hamdy@gmail.com)

**Copyright:** © the author(s), publisher and licensee Medip Academy. This is an open-access article distributed under the terms of the Creative Commons Attribution Non-Commercial License, which permits unrestricted non-commercial use, distribution, and reproduction in any medium, provided the original work is properly cited.

### ABSTRACT

**Background:** The objective of the study was to evaluate the outcome of the ellipse technique in 10 Egyptian patients in contrast with state-of-the-art practice cited in the medical literature.

**Methods:** A prospective comparative study was carried out on 10 consecutive patients with grade III (Simon's classification) gynecomastia presenting to the outpatient clinic at Menoufia university hospital, Menoufia, Egypt during the period from June 2015 to March 2018. History taking, local examination, radiological examination and laboratory investigation were done.

**Results:** Mean age of patients was 29.3 years. The BMI of the patients ranged from 32.3 kg/m<sup>2</sup> to 37 kg/m<sup>2</sup> with a mean BMI of 34.82 kg/m<sup>2</sup>. All patients showed good wound healing when dressings were removed at the 10-day interval. The scars showed maturation at around 10 to 12 months. None of the patients had a major complication such as infection, hematoma, seroma, or nipple-areola complex necrosis. There were no early postoperative complications apart from moderate bruising in 3 patients. Late complications included slowly resolving hypoesthesia in two patients. This was a transient complication that resolved completely. No patient required revision surgery.

**Conclusions:** The technique allows precise control of the final shape and contour of the corrected chest wall with proper positioning of the nipple-areola complex without a residual deformity. It has been shown to yield consistent and reproducible results in this subset of patients in an easy, quick and safe manner. The technique is also easily learned and taught. The resultant scarring is positioned along the lines of least skin tension and is quite inconspicuous and well hidden in patients with excess chest wall hair.

**Keywords:** Ellipse technique, Gynecomastia, Outcomes, Simon's classification, Surgical intervention

### INTRODUCTION

Gynecomastia is the development of abnormally large mammary glands in males thus acquiring a feminine look of the breast, which can sometimes cause secretion of milk.<sup>1</sup> Gynecomastia can be emotionally devastating. Feelings of shame, embarrassment and humiliation are common.<sup>2</sup> It results from an altered estrogen androgen balance, in favor of estrogen, or increased breast sensitivity to a normal circulating estrogen level. The

imbalance is between the stimulatory effect of estrogen and the inhibitory effect of androgen.<sup>3</sup>

The prevalence of gynecomastia was reported to be between 32-65%, due to use of different methods of assessment and the analysis of males of different ages and with different lifestyles, while autopsy data suggest a prevalence of 40%.<sup>4</sup> Generally, a trimodal age distribution is observed. The first peak occurs in infancy or the neonatal period, with an occurrence of 60-90%.

During pregnancy, the placenta converts DHEA (dehydroepiandrosterone) and dehydroepiandrosterone-sulfate (DHEA-SO<sub>4</sub>), derived from both mother and fetus, to estrone (E1) and estradiol (E2), respectively. E1 and E2 then enter the fetal circulation and later stimulate breast glandular proliferation, which results in transient neonatal gynecomastia. Normally, this condition regresses within 2-3 weeks of delivery.<sup>5</sup> The second peak occurs during puberty and has a prevalence of 4-69%. This wide variation is likely due to differences in what is considered to be normal sub-areolar glandular tissue, the diagnosing physician and most importantly variations in the age distribution of the patient populations.<sup>4</sup> Pubertal gynecomastia usually begins at age 10-12 years-old and peaks at ages 13-14 years-old. It usually regresses within 18m and is uncommon in males aged 17 and older. The final peak occurs in older males (particularly in those aged 50-80 years-old), with a prevalence of 24-65%.<sup>6</sup>

Gynecomastia can be physiologic or pathologic. Physiologic gynecomastia is seen in newborn infants, pubescent adolescents, and elderly individuals. Pathologic gynecomastia can be caused by a decrease in production or a decrease in action of testosterone, an increase in production or an increase in action of estrogen, or drug use; however, gynecomastia can also be idiopathic.<sup>7</sup> Medical treatment can be used early in the course of gynecomastia. Drugs such as clomiphene, tamoxifen, danazol and test lactone can be prescribed.<sup>8</sup> For many men, the best solution is surgery. Many modalities of surgery are available such as liposuction, reduction mammoplasty or subcutaneous mastectomy.<sup>9</sup>

The aim of the study was to evaluate the outcome of the ellipse technique in 10 Egyptian patients in contrast with state-of-the-art practice cited in the medical literature.

## METHODS

### Study design

A prospective comparative study was carried out on 10 consecutive patients with grade III (Simon's Classification) gynecomastia presenting to the outpatient clinic at Menoufia university hospital, Menoufia, Egypt during the period during from June 2015 to March 2018.

### Inclusion criteria

Any male patient between 24 and 35 years old not was suffering from hormonal disturbance, with no previous gynecomastia surgery, Patients with grade III gynecomastia according to Simon's classification with lip glandular pattern.

### Exclusion Criteria

Exclusion criteria were any male patient below 24 or above 35 years old, patients with medical causes of gynecomastia e.g., liver cell failure, patients on

medications that cause gynecomastia, patients with psychiatric problems and patients with cancer breast.

### Ethical consideration

The study was approved by the ethical committee of Menoufia Faculty of Medicine and an informed consent obtained from all patients before the study was commenced.

### All patients included in the study were evaluated by

Careful history taking and thorough physical examination. In addition to a detailed medical history the following items were specifically stressed upon: Related to breast enlargement: Duration of breast enlargement, Presence of breast pain or tenderness and Worrisome symptoms of breast cancer (e.g. bloody nipple discharge, ulceration and family history), systemic illness: (recent abnormal weight loss or weight gain, liver disease, CRF or dialysis and symptoms of hyperthyroidism), changes in libido, sexual functioning, or other symptoms of hypogonadism, medication use, recreational drug use (e.g., marijuana, heroin), occupational/dietary/accidental exposure to estrogen and previous treatment of gynecomastia. In addition, patients were requested to grade their emotional and psychological distress caused by the condition by filling in the following questionnaire:

What is the amount of suffering or psychological distress you have because of this problem?

1- Minimal	+
2-	++
3-	+++
4- Marked	++++

### Physical examination

In addition to a systematic physical examination the following points were specifically looked for in every case:

- *Degree of virilization:* voice, facial and body hair, muscular development
- *Breast examination:* (True gynecomastia versus pseudo gynecomastia, Signs suspicious for breast cancer (e.g. hard asymmetric mass, fixation to skin or underlying structures, axillary lymphadenopathy) and breast tenderness.
- *Examination of genitalia:* (Testicular size, Testicular masses, Phallus size and development and Pubic hair development).
- Stigmata of chronic liver or kidney disease.
- Examination of thyroid and signs of hyperthyroidism.

### Laboratory evaluation

Kidney function (blood urea nitrogen/creatinine), Liver function tests.

Thyroid function (thyroid-stimulating hormone with or without free thyroxine), serum testosterone (total and bioavailable or free), LH, FSH, prolactin, serum estrogens (serum E2). All the values were normal except for 3 patients (cases number: 3, 7, 9) who had abnormal liver function tests. Both their alanine aminotransferase and aminotransferase were elevated but the elevation was less than two-fold in all three patients. They were further investigated by abdominal ultrasound which showed mild fatty changes in case 3. The other 2 patients had normal abdominal ultrasound. The 3 patients were also investigated by hepatitis markers, but the 3 patients came negative for all markers.

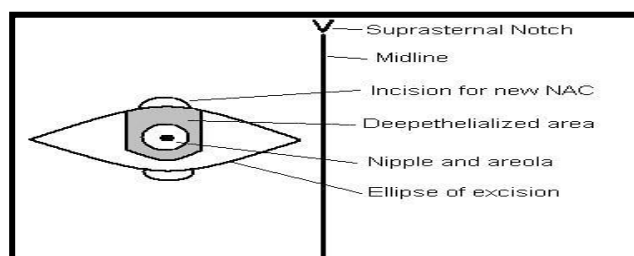
### Radiological examination

Radiological examination is not recommended for routine evaluation of gynecomastia.<sup>10</sup> All the patients included in the study had no indication for mammography and breast ultrasound. The 3 patients with elevated liver enzymes were investigated by abdominal ultrasound.

### The ellipse technique

**Indications:** This method is suitable for patients with grade III gynecomastia and breast ptosis. All the patients included in this study were operated upon using “The ellipse technique”.

**Preoperative markings:** Preoperatively all patients were marked in the upright sitting position.



**Figure 1: Preoperative markings.**

This figure shows the preoperative markings. The ellipse covers the area of excessive breast tissue. The extremities of the ellipse lie at the edge of the breast tissue. The distance to the new areola from the supra sternal notch and from the midline should be identical on both sides to achieve symmetry of position of the areola on the chest wall. The grey area represents the area to be deepithelialized.

- The ideal site for the neo nipple location on the chest wall is marked. It should fall on the breast axis, which begins at the sternal notch; this location will vary individually according to the built of each patient.
- The measured distance to the new site of the nipple, from supra sternal notch and from the middle line,

should be identical on both sides to assure symmetry of both areola positions.

- A horizontal ellipse of breast resection is planned, both its extremities begin at the flat border of the breast medially as well as laterally and that could differ from one breast to the other. The upper limb of the ellipse is on the horizontal line passing by the suggested site of the new nipple while its lower limb falls at around 6 cm from the infra-mammary line.
- The areola-nipple complex blood supply is from a superior pedicle dermo-glandular flap with a thickness of around 1.5 cm and a width of 7-8 cm and variable length depending on the extent of ptosis.

### Anaesthesia

All the patients were operated upon under general anaesthesia. 1 gm of intravenous broad-spectrum antibiotic was given along with the induction of anaesthesia.

### Operative technique

The ellipse of excision is traced and the superior pedicle flap maintaining the blood supply to the areola nipple complex is de-epithelialized and elevated. The excessive skin, glandular and fat tissues are removed from the front of the pectoral muscle. The two edges of the ellipse closed, and the areola buried. The new circle site of the areola is de-epithelialized in its upper half while full thickness skin excision in its lower half.

The buried areola is delivered and sutured to the skin. The subcutaneous tissue is approximated by 3-0 polyglactin or polydioxanone absorbable sutures. The skin is closed in a subcuticular manner using 4-0 polypropylene sutures.

**Drains:** No drains are placed.

**Dressings:** Compressive dressings are used and are left for 10 days.

The procedures suggested for reduction of the breast, when there is marked hypertrophy and ptosis, are usually derived from the methods applied to females and offer some disadvantages mainly the multiplicity of scars, which remains apparent in the male, and the lack of symmetry as regard the size of both breasts or shape and the nipple position.

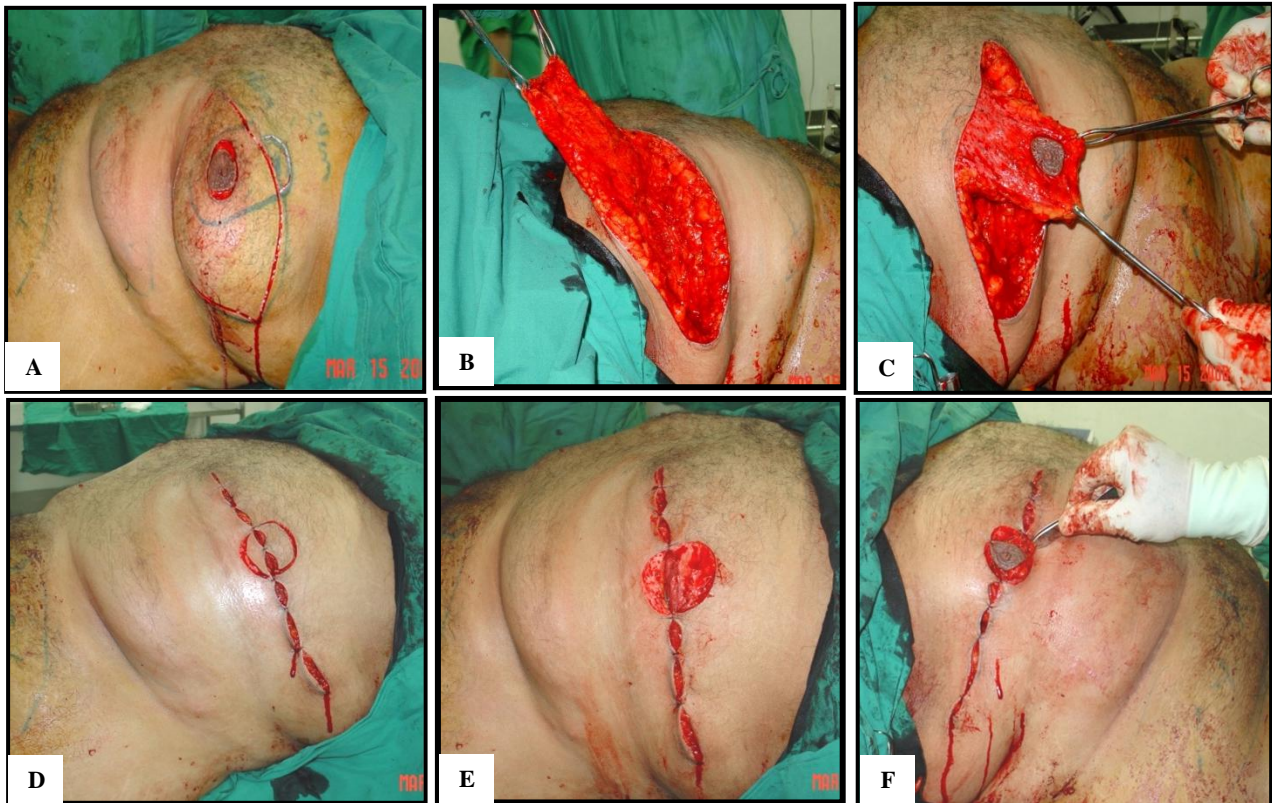
Over the years, numerous approaches to respect the excess skin were described. However, those approaches used methods respecting female anatomy and more suitable for female breasts. The proposed technique has got many advantages. There is no vertical scar but only one transverse scar right and left of the areola. The scars heal with a pleasing cosmetic appearance and become inconspicuous with time.



### Postoperative care

The patients received oral broad-spectrum antibiotics for 7 days after surgery. Compressive dressings were used and were left for 10 days. The follow up schedule was as follows: 24 hours post operatively, 3 and 5 days

postoperatively, 10 days postoperatively for removal of compressive dressings, 14 days post operatively for removal of stitches and One-month post operatively. Two months post operatively and then regular two monthly follow up for a year.



**Figure 2:** (A) The incisions for the ellipse of excision and circular around the areola preparing for the dermo-glandular flap carrying the areola-nipple complex; (B) the resection of the ptotic skin & breast tissues in excess completed. This should achieve symmetry of the size and shape on both sides and the superior pedicle flap turned up to show the depth of the glandular and fat resection; (C) the superior pedicle dermo-glandular flap maintaining the blood supply to the areola & nipple complex and the ellipse of deep excision of mammary gland and/or fat; (D) the horizontal wound is closed, and the précised site of the neo-areola is incised taking all precautions to be in the breast axis and symmetric with the contra lateral side; (E) the circle or the defect in the skin for lodging the areola at its new site on the male chest wall has been prepared and ready to receive it; (F) the nipple-areola complex delivered on the surface and fixed at its new site. There is a single horizontal scar interrupted in its middle by the areola.

### Statistical analysis

Results were tabulated and statistically analyzed by using a personal computer using MICROSOFT EXCEL 2016 and SPSS v. 21 (SPSS Inc., Chicago, IL, USA. Statistical analysis was done using descriptive: e.g., percentage (%), mean and standard deviation.

### RESULTS

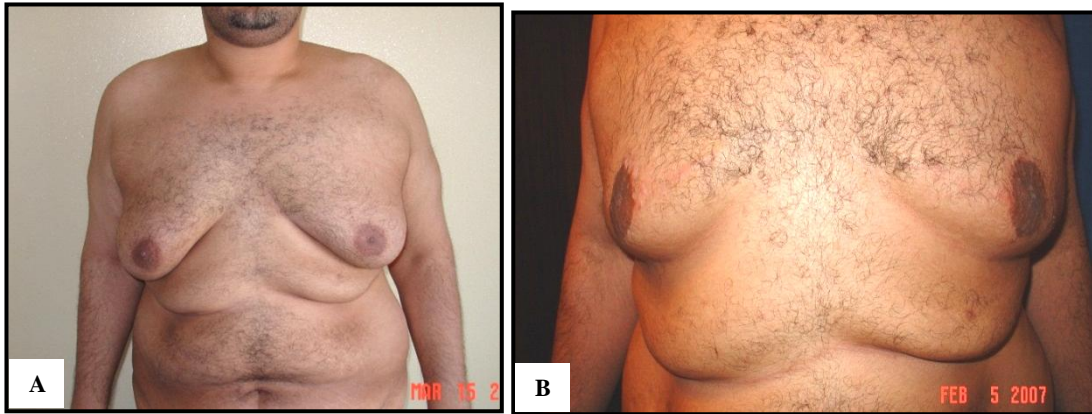
The current study showed that this study was conducted on 10 patients whose ages ranged from 24 years to 35 years with a mean age of 29.3 years. The BMI of the patients ranged from 32.3 kg/m<sup>2</sup> to 37 kg/m<sup>2</sup> with a mean

BMI of 34.82 kg/m<sup>2</sup>. All patients showed good wound healing when dressings were removed at the 10-day interval. The scars showed maturation at around 10 to 12 months. None of the patients had a major complication such as infection, hematoma, seroma, or nipple-areola complex necrosis. There were no early postoperative complications apart from moderate bruising in 3 patients. Late complications included slowly resolving hypoesthesia in two patients. This was a transient complication that resolved completely. No patient required revision surgery (Table 1).

Also, all patients completed an assessment sheet evaluating their satisfaction with surgery regarding their

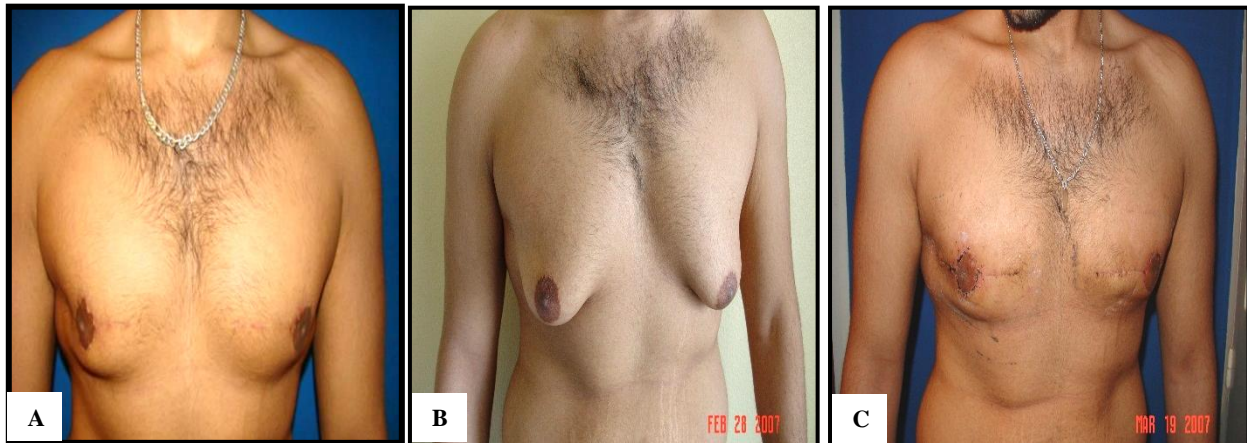overall satisfaction, their satisfaction with chest contour and their satisfaction with the scars, with a linear score out of a maximum of 10. This assessment sheet was adopted after Fruhstorfer et al who used a similar sheet in

their study on gynecomastia in 2003. The average overall patient satisfaction was 8.6 out of 10. The average satisfaction of chest contour was 8.95 out of 10. The average satisfaction of scars was 8.3 out of 10.



**Figure 3 (A and B): The result one-year post operatively using the ellipse technique.**

Note: how the scars healed inconspicuously.



**Figure 4 (A-C): The result 2 weeks postoperatively and one year postoperatively.**

Note: how the scars healed inconspicuously and the chest contour is aesthetically restored.

**Table 1: History of the studied patients.**

	Mean±SD	Range
<b>Age/year</b>	29.3±7.11	24-35
<b>Duration</b>	5.5±2.03	2.5-8
<b>Pain</b>	Yes: 7 (70%)	Mild: 3 (30%)
	<b>Yes</b>	<b>No</b>
	N (%)	N (%)
<b>Symptoms of cancer</b>	0 (0)	10 (100, Increase)
<b>Change in weight</b>	5 (50)	5 (50)
<b>Symptoms of liver disease</b>	0 (0)	10 (100)
<b>Symptoms of renal disease</b>	0 (0)	10 (100)
<b>Symptoms of hyperthyroidism</b>	0 (0)	10 (100)
<b>Symptoms of hypogonadism</b>	0 (0)	10 (100)
<b>Medication use</b>	0 (0)	10 (100)
<b>Recreational drugs use</b>	7 (70)	3 (30)
<b>Exposure to estrogen</b>	0 (0)	10 (100)
<b>Previous treatment</b>	0 (0)	10 (100)

Continued.

	Stationary	Progressive
	N (%)	N (%)
Course of gynecomastia	6 (60)	4 (40)
<b>Psychological impact of the deformity</b>		
++	4 (40)	
+++	3 (30)	
++++	3 (30)	

Table 2 a: Examination of the patients included in the study.

		No.	%				
<b>Virilization</b>	Normal	10	100				
	Abnormal	0	0				
<b>Simon's grade</b>	III (with ptosis)	10	100				
<b>Signs suspicious of cancer</b>	No	10	100				
	Yes	0	0				
<b>Breast tenderness</b>	No.	7	70				
	Mild	3	30				
<b>Laterality</b>	Rt > Lt	2	20				
	Lt > Rt	7	70				
	Equal	1	10				
<b>Consistency</b>	Soft, female like	10	100				
<b>Examination of genitalia</b>	Normal	10	100				
<b>Stigmata of chronic liver disease</b>	No	10	100				
	Yes	0	0				
<b>Stigmata of chronic renal disease</b>	No	10	100				
	Yes	0	0				
<b>Thyroid examination</b>	Normal	10	100				
	Abnormal	0	0				
<b>Body mass index (kg/m<sup>2</sup>)</b>	<b>Areolar diameter (cm)</b>	<b>SSN to nipple distance (cm)</b>		<b>Midline to nipple distance (cm)</b>			
	<b>Rt</b>	<b>Lt</b>	<b>Rt</b>	<b>Lt</b>	<b>Rt</b>	<b>Lt</b>	
<b>Mean±SD</b>	34.82±1.53	4.49±0.38	4.44±0.47	26.76±1.7	26.71±2.1	14.56±1.14	14.53±1.28
<b>Range</b>	32.3-37	3.9-4.9	3.8-5.4	24.2-30	23.2-31.2	13-16.5	13-16.9
	<b>NAC asymmetry</b>			<b>Previous chest wall scars</b>			
	<b>Rt &gt; Lt</b>	<b>Lt &gt; Rt</b>	<b>None</b>	<b>Yes</b>	<b>None</b>		
	2 (20%)	1 (10%)	7 (70%)	0 (0.0%)	10 (100%)		

Table 3: Outcome of the results.

	Mean±SD	Range	
<b>Overall satisfaction</b>	8.6±0.63	7.5-10	
<b>Chest contour satisfaction</b>	8.95±0.66	7.5-10	
<b>Scars satisfaction</b>	8.3±0.68	7-10	
		<b>No.</b>	<b>%</b>
<b>Histopathology</b>	Gynecomastia	8	80
	Gynecomastia with mild focal epithelioid	1	10
	Gynecomastia with epithelial hyperplasia	1	10
<b>Complications</b>	Moderate bruising	2	20
	None	6	60
	Moderate bruising and hypoesthesia	1	10
	Hypoesthesia	1	10



## DISCUSSION

Numerous techniques have been described for the correction of gynecomastia, and the surgeon is faced with a wide range of excisional and liposuction procedures.<sup>11</sup> The surgical approach to the treatment of gynecomastia shows a wide variation in the literature.<sup>12</sup> Early publications focused on surgical excision of the glandular tissue, whereas more recent studies advocate the unique use of liposuction, emphasizing superior esthetic results and decreased complication rates.<sup>12</sup> The surgical treatment of gynecomastia requires an individual approach, depending on the grade of male breast hypertrophy. True glandular hypertrophy requires a surgical glandular tissue excision and subsequent histological examination, thus avoiding oncological pitfalls.<sup>12</sup> Liposuction can be used as an additional technique for optimizing the esthetic result following the excision of the glandular tissue. Exclusive liposuction should be restricted to cases of pseudo gynecomastia.<sup>13</sup> The major concern with the exclusive use of liposuction is the lack of histopathological analysis of the resected tissue.<sup>12</sup> Even though it is technically possible to submit tissue pieces from liposuction to a histopathological analysis, this has been performed only rarely, and the results are difficult to interpret due to tissue damage and consistency.<sup>14</sup> In one study, 3% of patients were diagnosed as having atypical cellular findings.<sup>12</sup>

In this study all surgical specimens were submitted for histopathological analysis. One patient had mild focal epitheliosis and another patient had epithelial hyperplasia. Webster's incision is the most commonly employed if open excision is indicated in order to resect glandular tissue. The operation with the semicircular intra-areolar incision has become the standard operation for excision of gynecomastia. This technique, however, is of limited use in larger breasts, notably those with skin excess. Over the following years, numerous approaches to respect the excess skin were described. However, these approaches used methods respecting female anatomy and are more suitable for female breasts because they were developed with the aesthetics of the female breast taken into consideration, which are essentially different from the aesthetics of the male breast.

In this study only patients suffering from gynecomastia with significant skin redundancy and breast ptosis were included. The review of literature concerning the methods described for treatment of this group of patients revealed that the most commonly employed methods are the Letterman technique, breast amputation with a free nipple areola graft, concentric mastopexy, Lejour mastopexy and inferiorly based dermal flap (which was described by Courtiss et al for reduction mammoplasty in females and applied to males with gynecomastia). The Letterman technique has the advantage of ending with a single scar which unfortunately lies obliquely on the chest wall rendering it conspicuous as Langer's lines in this area are actually horizontal and not oblique. In addition, it shifts

the nipple-areola complex to a medial position which is not desired.<sup>15</sup> Breast amputation with a free nipple areola graft has the advantage of ending with a single scar with more control over the final position and symmetry of the nipple-areola complex. Survival of the nipple-areola complex, however, with this technique is not consistent. Even if survival is adequate, frequent pigmentary disturbances render results less than ideal.<sup>16</sup>

Concerning concentric mastopexy, the advantages are a circular scar, good blood supply to the areola and nipple, excellent access to the glandular excision, and the possibility of nipple relocation to a higher level if necessary. The possible widening of the circumareolar scar and the significant wrinkling of the skin at the circumareolar closure especially in patients with significant skin redundancy are major drawbacks of this technique. The higher incidence of scar hypertrophy is another disadvantage. Finally, residual skin redundancy may still be noted.<sup>17</sup> Lejour mastopexy is one of these techniques which use methods of female breast reduction to correct gynecomastia. This technique has the disadvantage of ending with a vertical scar on the chest wall as well as wrinkling of excessive skin in cases of marked skin redundancy.<sup>15</sup> Regarding the inferiorly based dermal flap, this technique has the disadvantage of multiplicity of scars. It is also one of the techniques that adopt methods used for the female breast to manage gynecomastia.<sup>15</sup>

In the Ellipse technique, the final scar lying horizontally conforms to Langer's lines of least skin tension. This may explain the adequate healing of the scar without complications of hypertrophy or widening with reduced visibility. The scar was noted to be particularly well hidden and inconspicuous in patients with a hairy chest wall. This technique leaves the patient with no residual skin redundancy whatsoever while maintaining the nipple-areola complex intact, it offers a wide exposure in the surgical field rendering the surgery easier and quicker. The final shape of the corrected breast conforms to the aesthetics of the male breast. This technique is also simple, quick and easy to learn. A total of ten patients were included in this study. All patients had grade III gynecomastia (with ptosis) and all were operated upon by the ellipse technique. None of the patients had a major complication such as hematoma, infection, seroma, or nipple-areola complex necrosis. There were no early postoperative complications apart from moderate bruising in 3 patients. Late complications included slowly resolving hypoesthesia in two patients. This was a transient complication that resolved completely. In addition, the technique allows perfect matching between the areolar diameter and the incised periareolar wound. Thus, widening of the periareolar scar and wrinkling of the surrounding skin seen with other techniques is not a problem with this technique and has not been observed in any of our patients. As the technique employs a dermo glandular pedicle for transfer of the NAC, viability of the NAC is not compromised. Moreover, the technique

allows fine control of areolar diameter and more importantly of the exact position and symmetry of the NAC in a safe and predictable way. This is due to the final template of the new NAC circle being only incised after adequate correction of the gynecomastia and even closure of the skin. This contrasts with other techniques where the future position of the NAC is predetermined preoperatively and before resection of the excess skin and glandular tissue.

One of the main advantages of the ellipse technique is the wide exposure it provides during resection of the glandular tissue. Thus, adequate resection, summarization and proper hemostasis are facilitated. In addition, it renders correction of gynecomastia safe, easy, rapid and easily learned with minimal complications. The mean operative time in our patients has been around 1 hour and 20 minutes which contrasts well with other techniques. Thus, the technique by offering a wide exposure of the surgeon allows rapid execution of the surgery while minimizing complications as well. No patient required revision surgery. The patients were asked to complete a survey regarding their overall satisfaction, their satisfaction with chest contour and their satisfaction with the scars. The survey of satisfaction was done on a scale from 1 to 10. The average overall patient satisfaction was 8.6 out of 10. The average satisfaction of chest contour was 8.95 out of 10. The average satisfaction of scars was 8.3 out of 10. This technique allows precise control of the final symmetry of the corrected chest wall, the position, size and symmetry of the nipple-areola complex in an easy, quick and easily learned manner. The technique in addition has shown to produce predictable, consistent and reproducible results.

## CONCLUSION

The technique allows precise control of the final shape and contour of the corrected chest wall with proper positioning of the nipple-areola complex without a residual deformity. It has been shown to yield consistent and reproducible results in this subset of patients in an easy, quick and safe manner. The technique is also easily learned and taught. The resultant scarring is positioned along the lines of least skin tension and is quite inconspicuous and well hidden in patients with excess chest wall hair.

*Funding: No funding sources*

*Conflict of interest: None declared*

*Ethical approval: The study was approved by the Institutional Ethics Committee*

## REFERENCES

1. Filgo AJ, Foley JF, Puvanesarajah S, Borde AR, Midkiff BR, Reed CE, et al. Mammary gland

- evaluation in juvenile toxicity studies: temporal developmental patterns in the male and female harlan sprague-dawley rat. *Toxicol Pathol.* 2016;44(7):1034-58.
2. Swerdloff RS, Ng CM. Gynecomastia: etiology, diagnosis, and treatment. In *Endotext*. MDText. com, Inc. 2019.
3. Filgo AJ, Faqi AS. Effects of chemicals on mammary gland development. In *Developmental and Reproductive Toxicology*, Humana Press, New York, NY; 2017: 205-234.
4. Rahmani S, Turton P, Shaaban A, Dall B. Overview of gynecomastia in the modern era and the Leeds Gynaecomastia Investigation algorithm. *Breast J.* 2011;17(3):246-55.
5. Cuhaci N, Polat SB, Evranos B, Ersoy R, Cakir B. Gynecomastia: clinical evaluation and management. *Indian J Endocrinol Metabol.* 2014;18(2):150.
6. Barros AC, Sampaio MD. Gynecomastia: physiopathology, evaluation and treatment. *Sao Paulo Med J.* 2012;130(3):187-97.
7. Sansone A, Romanelli F, Sansone M, Lenzi A, Di Luigi L. Gynecomastia and hormones. *Endocrine.* 2017;55(1):37-44.
8. Soliman AT, De Sanctis V, Yassin M. Management of adolescent gynecomastia: an update. *Acta bio-medica: Atenei Parmensis.* 2017;88(2):204.
9. Leung KCA, Leung AC. Gynecomastia in infants, children, and adolescents. *Recent patents on endocrine, metabolic and immune drug discovery.* Ingenta. 2016,10(2):127-37.
10. Narula HS, Carlson HE. Gynecomastia. *Endocrinol Metab Clin N Am.* 2007;36:497-519.
11. Fruhstorfer BH, Malata CM. A systematic approach to the surgical management of gynecomastia. *Br J Plast Surg.* 2007;56:237-46.
12. Handschin AE, Bietry D, Husler R, Banic A, Constantinescu M. Surgical Management of Gynecomastia a 10-year Analysis. *World J Surg.* 2008;32:38-44.
13. Rohrich RJ, Ha RY, Kenkel JM. Classification and management of gynecomastia: Defining the role of ultrasound assisted liposuction. *Plast Reconstr Surg.* 2003;111:909-23.
14. Fentiman IS, Fourquet A, Hortobagyi GN. Male breast cancer. *Lancet.* 2006;367:595-604.
15. Goldwyn RM, Cohen MN. *The Unfavorable Result in Plastic Surgery: Avoidance and Treatment.* 3rd ed. Baltimore, Md: Lippincott Williams and Wilkins; 2001: 663-673.
16. Simon BE, Hoffman S, Kahn S. Classification and surgical correction of gynecomastia. *Plast Reconstr Surg.* 1973;124:556.
17. Tashkandi M, Al-Qattan M, Hassanain JM, Hawary MB. The Surgical Management of High-Grade Gynecomastia. *Ann Plastic Surg.* 2004;53(1):17-20.

**Cite this article as:** Elghotmy MH. Surgical intervention using ellipse technique in treatment of gynecomastia. *Int Surg J* 2019;6:4253-60.