

Case Report

Giant prostatic utricle with reflux mimicking ureteric diverticulum in the setting of a penoscrotal hypospadias: a rare case report

Amit Kumar, Rashi*, Amit Kumar Sinha, Bindey Kumar, Sambedna

Department of pediatric surgery, AIIMS, Patna, Bihar, India

Received: 14 September 2019

Accepted: 17 October 2019

*Correspondence:

Dr. Rashi,

E-mail: arshishad@gmail.com

Copyright: © the author(s), publisher and licensee Medip Academy. This is an open-access article distributed under the terms of the Creative Commons Attribution Non-Commercial License, which permits unrestricted non-commercial use, distribution, and reproduction in any medium, provided the original work is properly cited.

ABSTRACT

Prostatic utricle may present as big cystic mass and may mimic ureteral diverticulum. A giant prostatic utricle may be asymptomatic with proximal hypospadias with undescended testis. We are describing a case which was operated twice for hypospadias and then came to us with recurrent penoscrotal hypospadias. On workup giant prostatic utricle was diagnosed and managed.

Keywords: Penoscrotal hypospadias, Prostatic utricle, Vas deferens

INTRODUCTION

Prostatic utricle is a depression in the prostatic urethra at the summit of the urethral crest on the veru montanum bounded laterally by the ejaculatory ducts. The incidence of prostatic utricle in severe hypospadias is 14% and the incidence is even higher if associated with cryptorchidism.¹ The common complications are difficult catheterization and occasionally infection. Here we report a case of giant prostatic utricle (more than 5 cm diameter) which mimicked ureteric diverticulum and on exploration turned out to be prostatic utricle communicating to the right sided undescended testis.

CASE REPORT

An eleven year old male child presented to us with complains of penoscrotal hypospadias with right side undescended testis. A thorough history taking it was found that he had undergone two previous surgeries for hypospadias at some other hospital. There was no history of hematuria, dysuria or urinary incontinence. On local examination meatal opening was present at the penoscrotal junction; mild ventral chordee was present, with edematous mucosa protruding through the urethral

opening. Penoscrotal transposition and bifid scrotum was present with absence of testis in right hemiscrotum.

Due to previous history of multiple surgeries we wanted to evaluate the status of bladder and upper tract so an ultrasound of kidney, ureter, and bladder was done. It showed right sided duplex ureter, lower ureter opening in proximal urethra upper ureter opening in urinary bladder at normal position.

To confirm the diagnosis of right duplex system we advised intravenous pyelogram. It showed a fusiform shaped contrast filled lesion in right side of urinary bladder (inferolateral aspect) which was abutting the urinary bladder. On ultrasound correlation a cystic lesion measuring 5×1.2 cm noted in inferolateral aspect abutting the urinary bladder. The differential diagnosis was-

- Possibility of ectopic ureteric insertion of right upper ureteric moiety
- Cecoureterocele

To confirm the functionality and duplex system of right kidney DMSA was done showing normal bilateral kidneys with no evidence of renal scar. To clear the anatomy of right lower ureter and both the ureteric

openings we planned cystoscopy. But on table the urinary meatus was almost non catheterize. We deferred the cystoscopy and did suprapubic catheter (SPC) to prevent urinary retention. After 3 months we did meatotomy of perineal meatus and cystoscopy. Cystoscopic findings were trabeculated bladder with scarring at previous SPC site. There was a tubular opening just proximal to the urethral meatus. Authors were able to pass the 9 French cystoscope in that tunnel like lumen. With this cystoscopic finding we made diagnosis of right ectopic insertion of ureter at prostatic urethra. After routine work up, right sided ureteric reimplantation was contemplated with extravesical approach. Patient was posted for surgery. Foleys catheterization was done. Pfannenstiel incision was given and abdomen was opened. But to our greatest surprise Foleys bulb could be palpated outside the bladder in a blind ending pouch. The decision was taken to open the bladder. Operative findings were bilateral ureteric orifice opening normally at the bladder trigone (both catheterized with infant feeding tube no 5). Bladder neck was normal. A tubular structure was arising from the posterior urethra (10 cm) and connecting proximally to testes like structure in right inguinal region (Figure 1). On further exploration dysplastic right testis and dilated thick right vas was noted. Dilated vas with atrophic right testis was excised and sent for histopathological examination (Figure 2). SPC and PUC (per urethral catheters) were left in situ and bladder closed in 2 layers.

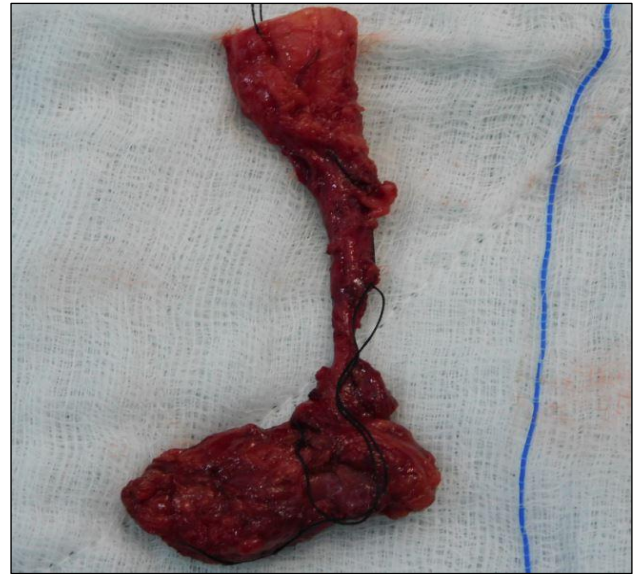


Figure 2: Excised specimen of atrophic testis with tract communicating with prostatic utricle.

Postoperative course was uneventful, PUC catheter was removed on post op day 8. Patient passed urine per urethral and SPC catheter was removed on post op day 10 and patient was discharged on post op day 15. Histopathology confirmed the diagnosis of dysplastic right testis.

DISCUSSION

Prostatic utricle is a mullerian duct remnant which is usually seen in patients with disorders of sexual differentiation or proximal hypospadias. Grossly enlarged prostatic utricle can lead to urinary tract infection, dysuria, urgency, hematuria, epididymitis or calculus formation. Diagnosis is usually confirmed by micturating cystourethrogram or retrograde urethrogram. The cranial portion of the prostatic utricle is derived from the Mullerian duct and the caudal segment is thought to have mixed origins from the Mullerian and Wolffian ducts and the urogenital sinus.² A giant prostatic utricle may also mimic mullerian duct cyst but in latter case external genitalia is typically normal and it usually present post puberty.

These pelvic cysts usually arise behind the veru montanum and extending above the base but not in continuity with it. The excision of mullerian cysts is more difficult than prostatic utricle as it is more adhered to the nearby structures.³ Prostatic utricles or persistent Mullerian duct remnants have traditionally been excised via the open or laparoscopic approach.⁴ But we preferred open approach due to confusing anatomy of our case. This was a case which initially looked like an ectopic ureter turned out to be a giant prostatic utricle which was mimicking ureteric diverticulum and extending up to the undescended right testis. No such case has been reported in literature so far.

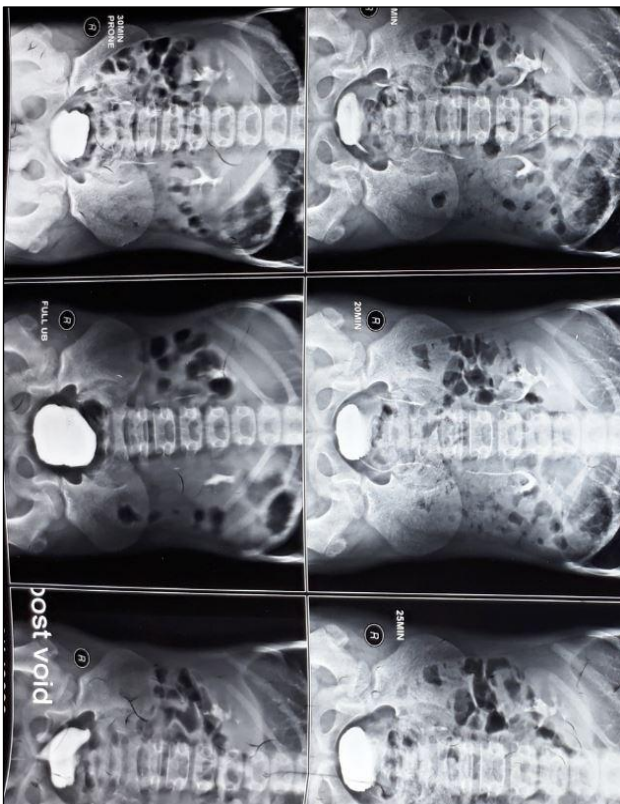


Figure 1: IVP-showing cystic lesion on right side of bladder.

CONCLUSION

Giant prostatic utricle should be suspected in cases of penoscrotal hypospadias and it should be more strongly suspected if associated with cryptorchidism.

Funding: No funding sources

Conflict of interest: None declared

Ethical approval: Not required

REFERENCES

1. Devine CJ, Gonzalez-Serva L, Stecker JF, Devine PC, Horton CE. Utricular configuration in hypospadias and intersex. J Urol. 1980;123(3):407-11.
2. Gualco G, Ortega V, Ardao G, Cravioto F. Clear cell adenocarcinoma of the prostatic utricle in an adolescent. Annal Diag Pathol. 2005;9(3):153-6.
3. Myers GH. Deep pelvic cysts. Saunders WB, eds. Clinical urography: an Atlas and Textbook of Roentgenologic diagnosis. Philadelphia; 1971: 159.
4. Yeung CK, Sihoe JD, Tam YH, Lee KH. Laparoscopic excision of prostatic utricles in children. BJU Int. 2001;87(6):505-8.

Cite this article as: Kumar A, Rashi, Sinha AK, Kumar B, Sambedna. Giant prostatic utricle with reflux mimicking ureteric diverticulum in the setting of a penoscrotal hypospadias: a rare case report. Int Surg J 2019;6:4187-9.