

## Case Report

# Gossypiboma: case report and review of literature

Tulasi Ram<sup>1</sup>, Divya Dahiya<sup>2\*</sup>, Anil Naik<sup>2</sup>

<sup>1</sup>Department of Surgery, All India Institute of Medical Sciences, New Delhi, India

<sup>2</sup>Department of Surgery, Post Graduate Institute of Medical Education and Research, Chandigarh, India

**Received:** 27 August 2019

**Accepted:** 02 October 2019

**\*Correspondence:**

Dr. Divya Dahiya,

E-mail: [dahiyadivya30@gmail.com](mailto:dahiyadivya30@gmail.com)

**Copyright:** © the author(s), publisher and licensee Medip Academy. This is an open-access article distributed under the terms of the Creative Commons Attribution Non-Commercial License, which permits unrestricted non-commercial use, distribution, and reproduction in any medium, provided the original work is properly cited.

### ABSTRACT

Gossypiboma or retained surgical sponge is an entirely preventable surgical complication; it is associated with significant morbidity to patient and medico legal issues to the surgeon. Clinical presentation depends upon location of the foreign body and tissue reaction to the foreign body. Pre-operative diagnosis is the most difficult part and treatment of choice is surgery. A 30 year female presented with 16 months history of gradually increasing lump on left side of lower abdomen following a caesarian section. Ultrasonography was suggestive of infected mesenteric cyst and contrast enhanced computed tomography scan of abdomen was suggestive of either chronic abscess or gossypiboma. She was treated surgically; intra-operatively there was a 10×10 cm well circumscribed lesion in sigmoid mesentery which was adherent to sigmoid colon. It was a single surgical sponge with about 1000 ml of pus. Gossypiboma is an entirely avoidable surgical complication which is associated with significant morbidity and medico-legal implications. Meticulous counts with thorough exploration of site before closure can lessen the undue morbidity or mortality. Radio frequency identification verification by barcode scanner can reduce the error rate.

**Keywords:** Gossypiboma, Textiloma, Lump abdomen

### INTRODUCTION

Gossypiboma was the term which was first described by Wilson in 1884 for unintentionally left gauze or sponge in the body cavity at the end of a surgical operation.<sup>1</sup> The word gossypiboma was derived from two sources: the Latin word “gossypium” meaning textile or cotton, and the Swahili word “boma” meaning place of concealment.<sup>2</sup> Other terms used to describe gossypiboma are as textiloma (Textilis- weave in latin, Oma- swelling or tumor or disease in Greek) and gauzoma.<sup>3</sup> Gossypiboma is the cause of significant morbidity to a patient. Although there are many reports in the literature but the exact incidence of this entirely preventable surgical complication is unknown. The cause of this under-reporting may possibly be attributed to fear of litigation.

Gossypiboma can occur after any surgical procedure but the most commonly reported cases are after an abdominal

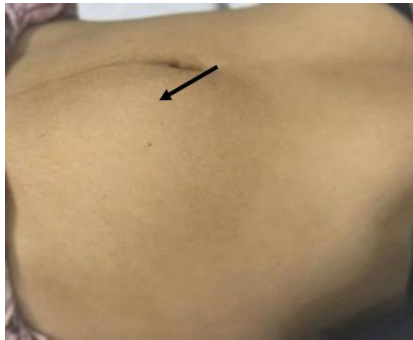surgery followed by pelvic, intra-thoracic and extremities’ surgeries. There are also reported cases of breast, pericardial and intracranial gossypibomas. Herein we report a case of an intra-abdominal gossypiboma after caesarian section.

### CASE REPORT

A 30 years female presented with complaint of awareness of lump in the left side of lower abdomen for 16 months which was gradually increasing in size. It was painful only on palpation with no other associated symptoms like vomiting, early satiety, alteration in bowel habits, GI bleed, menstrual or urinary complaints. She underwent lower segment caesarean section 18 months back.

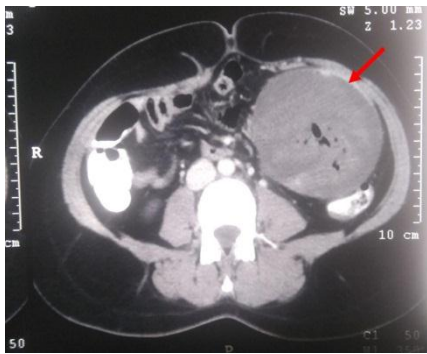
Her general physical examination was unremarkable. On abdominal examination there was a well-healed

Pfannenstiell scar and fullness in left umbilical and lumbar region causing abdominal asymmetry (Figure 1).

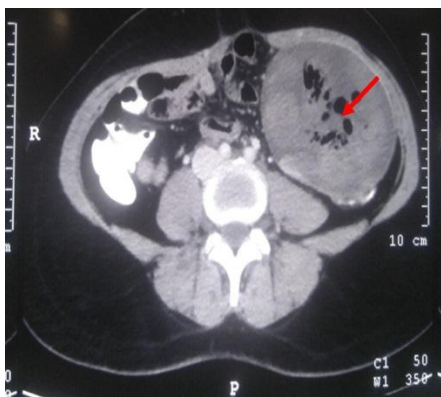


**Figure 1: Asymmetric mass in the left para-umbilical region (marked with arrow).**

On palpation there was a 10×8 cm well circumscribed firm mildly tender intra-abdominal mass with smooth surface; present predominantly in left iliac region which was mobile in the transverse direction.



**Figure 2a: Contrast enhanced computed tomography of abdomen showing well encapsulated mass (arrow).**

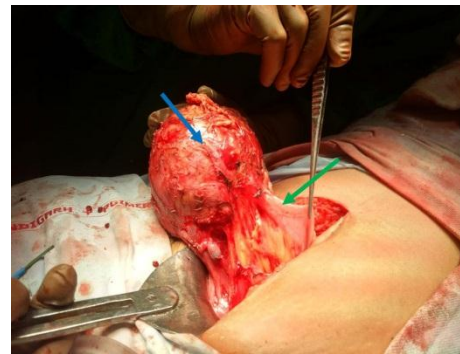

**Figure 2b: Well circumscribed mass with spongiform mottling appearance suggestive of foreign body (arrow).**

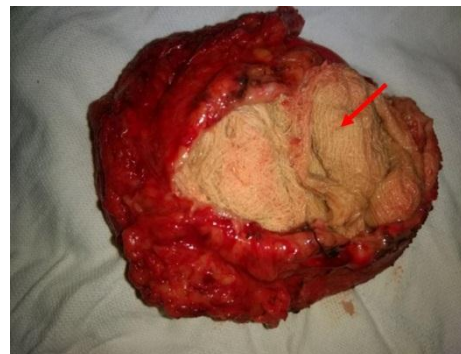
Laboratory parameters were within normal limit. On ultrasonography (USG) of abdomen there was a 7×9.3 cm well-circumscribed mass lesion in left para-umbilical region with hyperechogenic content which was

suggestive of an infected mesenteric cyst. Contrast enhanced computed tomography (CECT) abdomen showed a 7.8×9.3×10.3 cm well-defined heterogenous lesion with areas of hyperdensities and multiple air foci in left lumbar region which was surrounded by thin capsule; anteriorly it was causing a contour bulge in the anterior abdominal wall and posteriorly it was compressing sigmoid colon (Figures 2a and 2b). These findings were suggestive of gossypiboma or chronic abscess.

She was operated with a provisional diagnosis of gossypiboma after caesarian section. Lower midline laparotomy was done. On exploration, there was a 10×8cm well circumscribed lesion which was adherent to anterior abdominal wall, omentum and bowel. The main bulk of the lesion was in the sigmoid mesocolon and sigmoid colon was forming one of its walls (Figures 3a and 3b).



**Figure 3a: Operating photograph showing encapsulated mass (blue arrow) in sigmoid mesentery with sigmoid colon (green arrow).**



**Figure 3b: Cut section shows retained foreign body (single surgical sponge-arrow).**

It was freed all around by sharp dissection taking care not to injure sigmoid colon. On cut section, there was about 1000 ml of frank pus and the content was single surgical sponge. Post-operative course was uneventful and she was discharged on post-operative day 5. She is doing well on follow up. Culture of pus showed no bacterial growth. Histopathology was consistent with retained foreign body.

## DISCUSSION

Gossypiboma is a serious but avoidable surgical complication. It increases the cost of treatment, increases the morbidity and may cause mortality if there is delay in diagnosis and treatment.<sup>4</sup> True incidence of gossypiboma is difficult to estimate because of under-reporting; however reported incidence varies from 0.01-0.001%.<sup>5</sup>

The most forgotten materials after surgical procedure are gauze, sponge, needles or clamps. Gossypiboma accounts for 50% of malpractice claims for retained foreign bodies.<sup>6</sup> Most common cause is falsely pronounced correct counts at the end of surgery and other important causes are emergency surgery, unexpected change in surgical procedure, prolonged procedures, obesity or unstable patient condition. Gawande et al found emergency surgery, unplanned change in operation and high body mass index are statistically significant by multivariate logistic regression.<sup>7</sup> Gossypiboma are frequently reported after abdominal (56%), pelvic (18%) and thorax (11%) surgeries.<sup>5</sup> However, there are also reports after orthopedic, neurosurgical and cardiac procedures in paraspinal muscles, legs, shoulders and pericardial space.<sup>8</sup>

Symptoms of gossypiboma are non-specific. Symptomatology depends upon the location of foreign material and the body reaction to foreign material which can be either exudative or aseptic fibrinous reaction. Exudative reaction is an acute inflammatory reaction in the early post-operative period and leads to an abscess formation. Aseptic fibrinous response causes adhesions and encapsulation which eventually results in the development of a foreign-body granuloma. For that reason, gossypiboma may be asymptomatic or may present with abdominal pain, abdominal mass, intestinal obstruction, diarrhoea, gastrointestinal hemorrhage, granulomatous peritonitis or internal fistulization. Patients may present with significant loss of weight secondary to malabsorption caused by intestinal fistulization and intra-luminal bacterial overgrowth. There were reports of complete migration of foreign material into lumen of bowel or bladder without any apparent opening externally.<sup>9</sup> These usually do not pass the ileocecal valve and may present with intestinal obstruction.

Diagnosis is difficult as mostly gossypiboma are asymptomatic and present with variable presentation years after the primary surgery. A correct pre-operative diagnosis of gossypiboma is reported only in 1/3<sup>rd</sup> of cases; with a new onset or a recurrent tumor being the most common differential diagnosis.<sup>10,11</sup> Incorrect diagnosis may subject a patient to unnecessary invasive diagnostic procedures. Diagnosis is mainly by radiological imaging. If surgical sponges contain radiopaque material that facilitates detection by standard abdominal radiography; but identification is difficult in cases where no radio-opaque marker is used in surgical

sponges. Plain radiograph is not helpful when these markers are disintegrated or fragmented with time.

USG shows three characteristic patterns as echogenic area with intense posterior shadow, well-defined cystic mass containing distinct internal hyperechoic wavy stripped structure and nonspecific pattern with a hypoechoic or complex mass.<sup>12</sup> CECT is the investigation of choice which shows well circumscribed capsulated mass with presence of air within and calcification or enhancement of the wall. Internal structure may appear as a whirl like or spongiform due to the presence of gas trapped in the mesh of sponge and it may be of low density or complex with both low density and wavy, stripped or spotted high density area.<sup>13</sup> Foreign body reaction in the surrounding tissues may lead to misdiagnosis as a tumor.

Delay in diagnosis and initiation of treatment results in increased morbidity and also mortality in some cases. Surgery is the only treatment option which can be either open or laparoscopy. There are also reports of endoscopic removal.

The 'captain of the ship' doctrine is no longer assumed to be true and members of the entire surgical team should be accountable in litigations for retained foreign bodies. It is a preventable surgical complication. Canh et al first introduced radio opaque threads impregnated into surgical sponge in 1929.<sup>14</sup> It is in use in USA since 1940 and in Asian countries since 1980.<sup>15</sup> However, it is not being used in all health care institutes worldwide. With use of these sponges, early detection is possible but the condition itself cannot be prevented. The most effective measure to avoid this catastrophic complication is to do meticulous surgical count at various times, i.e., before making the incision, before closing the peritoneum or any cavity (uterus, pericardium), before closing the fascia, before skin closure and whenever sponges are added or scrub nurse changes. If count is incorrect, thorough exploration of the surgical site should be done; which should be complemented with fluoroscopy if a radio opaque impregnated surgical sponge is not retrieved by the surgeon. Radiofrequency chip identification (RFID) by barcode scanner can decrease the incidence of retained foreign body particle by eliminating errors in the sponge count by removing the human error factor.<sup>16</sup>

## CONCLUSION

Gossypiboma is an entirely avoidable surgical complication which is associated with significant morbidity and medico-legal implications. It has a wide range of clinical presentations; diagnosis is difficult, and therefore treatment is delayed. However, the best action will be prevention. Meticulous surgical count and thorough exploration of surgical site before closure lessen the undue morbidity and mortality. Errors in the sponge count can be eliminated further by removing the human error factor by using RFID by barcode scanner.

*Funding: No funding sources*

*Conflict of interest: None declared*

*Ethical approval: Not required*

## REFERENCES

1. Arora RK, Johal KS. Gossypiboma in thigh- a case report. *J Orthop Case Rep.* 2014;4:22-4.
2. Rajput A, Loud PA, Gibbs JF, Kraybill WG. Diagnostic challenges in patients with tumors: Gossypiboma (foreign body) manifesting 30 years after laparotomy. *J Clin Oncol.* 2003;21:3700-1.
3. Srivastava KN, Agarwal A. Gossypiboma posing as a diagnostic dilemma: a case report and review of the literature. *Case Rep Surg.* 2014;2014:713428.
4. Lata I, Kapoor D, Sahu S. Gossypiboma a rare cause of acute abdomen: a case report and review of literature. *Int J Crit Illn Inj Sci.* 2011;1:157-60.
5. Wan W, Le T, Riskin L, Macario A. Improving safety in the operating room: a systematic literature review of retained surgical sponges. *Curr Opin Anaesthesiol.* 2009;22:207-14.
6. Mathew RP, Thomas B, Basti RS, Suresh HB. Gossypibomas, a surgeon's nightmare-patient demographics, risk factors, imaging and how we can prevent it. *Br J Radiol.* 2017;90:20160761.
7. Gawande AA, Studdert DM, Orav EJ, Brennan TA, Zinner MJ. Risk factors for retained instruments and sponges after surgery. *N Engl J Med.* 2003;348:229-35.
8. Manzella A, Filho PB, Albuquerque E, Farias F, Kaercher J. Imaging of gossypibomas: pictorial review. *AJR Am J Roentgenol.* 2009;193:S94-101.
9. Moslemi MK, Abedinzadeh M. Retained intraabdominal gossypiboma, five years after bilateral orchiopexy. *Case Rep Med.* 2010;2010:420357.
10. Kopka L, Fischer U, Gross AJ, Funke M, Oestmann JW, Grabbe E. CT of retained surgical sponges (textilomas): pitfalls in detection and evaluation. *J Comput Assist Tomogr.* 1996;20:919-23.
11. Bulus H, Simşek G, Coskun A, Koyuncu A. Intraabdominal gossypiboma mimicking gastrointestinal stromal tumor: a case report. *Turk J Gastroenterol.* 2011;22:534-6.
12. Yamato M, Ido K, Izutsu M, Narimatsu Y, Hiramatsu K. CT and ultrasound findings of surgically retained sponges and towels. *J Comput Assist Tomogr.* 1987;11:1003-6.
13. Choi BI, Kim SH, Yu ES, Chung HS, Han MC, Kim CW. Retained surgical sponge: diagnosis with CT and sonography. *AJR Am J Roentgenol.* 1988;150:1047-50.
14. Shyung LR, Chang WH, Lin SC, Shih SC, Kao CR, Chou SY. Report of gossypiboma from the standpoint in medicine and law. *World J Gastroenterol.* 2005;11:1248-9.
15. Cheng TC, Chou ASB, Jeng CM, Chang PY, Lee CC. Computed tomography findings of gossypiboma. *J Chin Med Assoc.* 2007;70:565-9.
16. Macario A, Morris D, Morris S. Initial clinical evaluation of a handheld device for detecting retained surgical gauze sponges using radiofrequency identification technology. *Arch Surg Chic Ill.* 1960. 2006;141:659-62.

**Cite this article as:** Ram T, Dahiya D, Naik A. Gossypiboma: case report and review of literature. *Int Surg J* 2019;6:4148-51.