

## Case Report

# Leiomyosarcoma of vascular origin: a rare presentation

Sreeramulu P. N.<sup>1</sup>, Nipun A. C.<sup>2</sup>, Anup<sup>3</sup>, Vikranth N. Suresh<sup>1\*</sup>

<sup>1</sup>Department of Surgery, <sup>2</sup>Department of Urology, Sri Devaraj Urs Medical College, Kolar, Karnataka, India  
<sup>3</sup>Manipal Hospital, Bengaluru, Karnataka, India

**Received:** 28 July 2019

**Accepted:** 11 September 2019

**\*Correspondence:**

Dr. Vikranth N. Suresh,

E-mail: [dr.vikranth.sn@gmail.com](mailto:dr.vikranth.sn@gmail.com)

**Copyright:** © the author(s), publisher and licensee Medip Academy. This is an open-access article distributed under the terms of the Creative Commons Attribution Non-Commercial License, which permits unrestricted non-commercial use, distribution, and reproduction in any medium, provided the original work is properly cited.

### ABSTRACT

Malignant soft tissue neoplasm exhibiting smooth muscle differentiation is called leiomyosarcoma (LMS). LMS arising from the smooth muscles of tunica media of the major blood vessels like inferior vena cava (IVC) is a rare type of neoplasm, accounting for less than 0.5% of adult soft tissue sarcoma, affecting <1/1,00,000 of all adult malignancies. The prognosis of this tumor is poor, as patients often present with intra or extra-luminal growth often with invasion of adjacent structures. Only 400 cases of IVC LMS have been reported. Here we report a case of 40 year old female with large asymptomatic mass per abdomen of 3 months duration occupying the central and right part of abdomen. Investigations revealed a large retroperitoneal mass of 20.4\*22.8\*22.5 cms arising from the right kidney, likely Renal cell carcinoma. On exploration a huge tumor of size 25\*25\*20 cms was seen arising from retroperitoneum on right side, right kidney its vessels and ureter could not be seen separately. IVC could not be delineated. Histopathology report revealed it to be LMS of vascular origin. We report one such case because although incidence of such cases is low but should be considered in the differential diagnosis of mass per abdomen which grows unusually fast.

**Keywords:** Inferior vena cava, Leiomyosarcoma, Retroperitoneal tumor

### INTRODUCTION

Sarcoma is a cancer arising from mesenchymal origin. Leiomyosarcoma (LMS) of venous origin are 5 times more common than arterial origin, out of which 50% to 60% are seen in inferior vena cava.<sup>1,2</sup> Commonly seen in women of median age group around 50 years. Of all the soft tissue sarcoma, around 5% to 10% are LMS.<sup>3</sup> The prognosis of these tumors is poor as clinical presentation is very late. The type of intervention depends on the level of the tumor. Surgery remains the only intervention with curative content which sometimes include vascular reconstruction of the resected part of IVC. Here, we report one such case of LMS arising from IVC for which surgical resection along with IVC reconstruction using vascular graft (Dacron) was done.

### CASE REPORT

A 40 year old female presented to the hospital with chief complaint of painless mass per abdomen since 3 months without any other symptoms pertaining to hepatobiliary, gastrointestinal or urinary system.

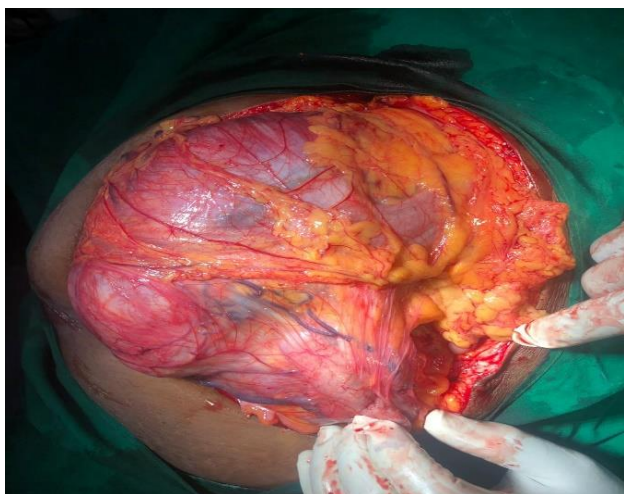
On clinical examination, a 24×26 cm hard mass was found occupying right hypochondrium, lumbar, iliac regions including epigastric and umbilical regions. Fingers could be insinuated between the mass and costal margins.

Blood investigations including renal function tests were within normal limits. Abdominal ultrasonography showed it to be a well-defined retroperitoneal mass with mixed echogenicity arising from the right kidney.

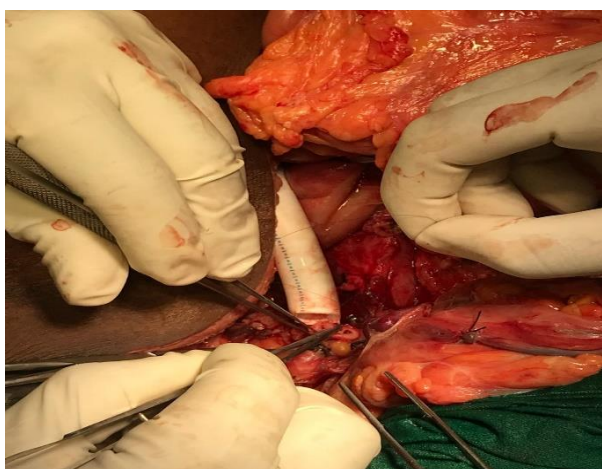Abdominopelvic computed tomography (CECT) showed large irregular, lobulated heterogeneously enhancing retroperitoneal lesion measuring 20.4×22.8×22.5 cms arising from the right kidney and the lesion was found to be encasing right renal vessels. Radiologically, features were suggestive of malignant etiology likely renal cell carcinoma. The lesion is encasing the right renal vessels, non-visualisation of right renal vein is probably due to infiltration by the tumor. The inferior vena cava is displaced to left side and is grossly compressed by the mass. Computed tomography of thorax was done and lung metastasis was ruled out.

### Treatment

Patient was taken up for surgery as per the tumor board opinion of our institution, after forming a Surgical team consisting of Urologist, Onco surgeon, Vascular Surgeon and General Surgeon. Intraoperatively, a large non encapsulated, multilobulated tumor was found as shown in Figure 1.

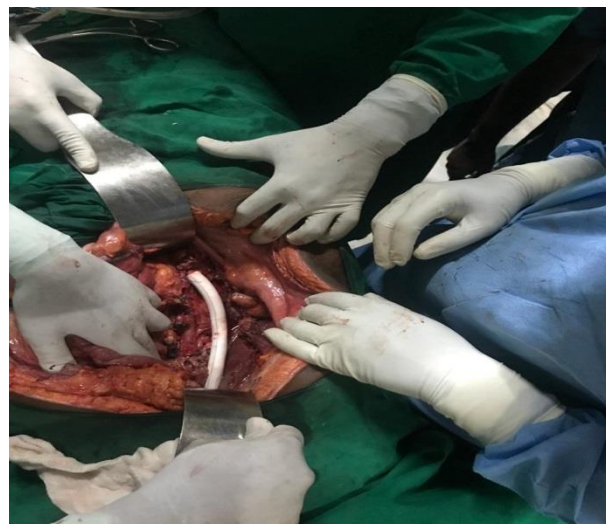


**Figure 1: Intra-operative picture of the tumor.**



**Figure 2: Anastomosis of IVC to dacron vascular graft.**

The right kidney, its artery, vein and ureter could not be made out separately. Inferior vena cava was completely encased and occluded by the tumor, hence could not be delineated separately from the tumor. The inferior vena cava above the iliac bifurcation to the infra-hepatic part was excised enblock with tumor. The resected tumor was 25×25×20 cm in size. The cut surface of the mass showed grey white to grey yellow areas with right kidney, its vessels and ureter embedded within. The resected part of the IVC was reconstructed using dacron graft as shown in Figure 2 and 3, the abdomen was closed in layers after placing two drains.



**Figure 3: Intra-operative picture of IVC reconstruction using Dacron graft.**

### Histopathology report

Section studied from tumor showed proper pleomorphic elongated spindle cells arranged in syncytial sheets, interlacing bundles and fascicles. The cells show moderate to severe nuclear pleomorphism with vesicular chromatin and irregular nuclear membrane with moderate eosinophilic cytoplasm. Also noted are areas of necrosis. More than 35 mitotic figures were observed per 10 high power fields. Section studied from the right kidney showed normal glomeruli and tubules. Interstitium shows mild inflammatory infiltrate in the form of lymphocytes and occasional plasma cells. Final impression was LMS of vascular origin.

### Post-operative period

Patient developed mild right pleural effusion and was treated accordingly. Patient was started on anticoagulants so as to maintain INR between 2.5 to 3. Patient recovered well and was discharged without any complications.

### DISCUSSION

LMS are one of the common types of retroperitoneal sarcomas. Vascular LMS are rare type of LMS with IVC

being the most common among them.<sup>2</sup> It can also arise from pulmonary artery and aorta. A retroperitoneal tumor with an intra- and extra-IVC growth pattern is strongly suggestive of LMS because most other primary retroperitoneal tumors such as liposarcoma and malignant fibrous histiocytoma do not have such growth pattern.

The incidence of IVC LMS constitute up to 1 in 100,000 of all malignant tumors. IVC LMS are more common in females in 5<sup>th</sup> or 6<sup>th</sup> decade. The first case of this kind was reported in 1871 by Perl et al which was diagnosed after postmortem examination.<sup>4</sup>

Venous obstruction and a palpable tumor mass were the most common symptoms. Deep venous thrombosis and even pulmonary embolism may be the initial clinical symptoms.<sup>5</sup>

LMS arising from smaller vessels are less frequent and may present primarily as nerve compression syndrome.<sup>6</sup> Venous branches of the lower extremity as well as the azygos vein have been described as unusual sites of manifestation of intravascular LMS in the current literature.<sup>7,8</sup>

Clinical manifestations depend upon the tumor volume, rate of growth, intra- or extravascular development, and thrombosis, but the most important, dependent on its location. It often presents as a vague mass per abdomen which is fairly large in size at the time of presentation. When a tumor involves the lower IVC segment, a palpable mass is the most common clinical manifestation. Budd–Chiari syndrome is associated sometimes only when a tumor involves the upper IVC segment. It can also present with pressure symptoms such as lower limb edema or abdominal pain.

Distant metastasis is rare and lungs are the most common site for the distant metastasis.

Surgery with negative margin is currently the only potentially curative therapy.<sup>9-11</sup> The aim when approaching IVC LMS should include achieving local control, maintaining the patency of major venous flow and decide on further adjuvant therapeutic strategies to reduce the recurrence rate.

Surgical management depends on the level of the tumor, extent of the tumor and presence of collateral circulation. Level 3 tumors are usually unresectable. Level 1 and 2 tumors are resectable and IVC reconstruction is required in cases with extensive IVC involvement without collateral circulation.

Small tumors with <75% circumference of IVC can be taken up for partial resection and cavoplasty. Large tumors with >75% circumference of IVC might require graft reconstruction of IVC. Various material including Dacron, polytetrafluoroethylene (PTFE) prosthesis are available.

Post-operative complications like graft thrombosis and chronic lower limb edema can occur. In our case patient did not develop such complications. Sometimes alternate venous channels open up in chronic venous block which can prevent development of lower limb edema even if graft is blocked. Patient is coming for regular follow up and doing well, Doppler ultrasound of the abdomen to look for patency of the graft was done, which showed normal blood flow. Serial renal function tests are being done in every follow up, which is within normal limits. The function of the opposite kidney (left side) is maintained due to venous drainage through alternate channels (collaterals). Patient requires further follow up to look for continued function of the opposite kidney and recurrence.

The role of neo-adjuvant and adjuvant therapies is controversial. Postoperatively adjuvant radiotherapy is advocated in few centres for patients with R0 resection and high grade large tumors with resection margins close to the tumor.

The survival rate for 2 and 5 years is 90% and 66.7% respectively for patients with tumor free margins after resection.

## CONCLUSION

The LMS of vascular origin (IVC) are rare, and therefore the diagnosis and management requires a multidisciplinary approach, consisting of Urologist, Oncosurgeon, Vascular Surgeon and General Surgeon. High amount of suspicion is required in diagnosing such tumor preoperatively, as radiological investigations may not give the complete information.

Hence the surgical team should detect if any untoward complications occurs intra-operatively and be ready with all the necessary procedures like vascular reconstruction of major vessels if required without depending too much on radiological investigations.

At present, tumor resection with negative margins remains the intervention of choice giving high survival rates.

*Funding: No funding sources*

*Conflict of interest: None declared*

*Ethical approval: Not required*

## REFERENCES

1. Issels R. Manual Knochtumoren und Weichteilsarkome. 4. München: W Zuckerschwerdt Verlag; 2004.
2. Varela-Duran J, Oliva H, Rosai J. Vascular leiomyosarcoma: the malignant counterpart of vascular leiomyoma. *Cancer*. 1979;8:1684–91.
3. Shimoda HOK, Otani S, Hakoziaki H, Yoshimura T, Okazaki HNS, Tomita S, et al. Vascular

- leiomyosarcoma arising from the inferior vena cava diagnosed by intraluminal biopsy. *Virchows Arch.* 1998;8:97–100.
4. Perl L. Ein Fall vom Sarkom der Vena cava inferior. *Virchows Arch.* 1871;8:378–85.
  5. Subramaniam MM, Martinez-Rodriguez M, Navarro S, Rosaleny JG, Bosch AL. Primary intravascular myxoid leiomyosarcoma of the femoral vein presenting clinically as deep vein thrombosis: a case report. *Virchows Arch.* 2007;8:235-7.
  6. Weiss SWGJ. In: (Hrsg) Enzinger and Weiss's soft tissue tumors. Weiss SW, Goldblum JR, editor. Mosby, StLouis Baltimore Berlin; *Leiomyosarcoma*; 2001: 727-748.
  7. Dasika U, Shariati N, Brown JM. Resection of a leiomyosarcoma of the azygos vein. *Ann Thorac Surg.* 1998;8:1405.
  8. Kevorkian J, Cento DP. Leiomyosarcoma of large arteries and veins. *Surgery.* 1973;8:390-400.
  9. Abed R, Abudu A, Grimer RJ, Tillman RM, Carter SR, Jeys L. Leiomyosarcomas of vascular origin in the extremity. *Sarcoma.* 2009;8:385164.
  10. Svarvar C, Bohling T, Berlin O, Gustafson P, Folleras G, Bjerkehagen B, et al. Clinical course of nonvisceral soft tissue leiomyosarcoma in 225 patients from the Scandinavian Sarcoma Group. *Cancer.* 2007;8:282-91.
  11. Berlin O, Stener B, Kindblom LG, Angervall L. Leiomyosarcomas of venous origin in the extremities. A correlated clinical, roentgenologic, and morphologic study with diagnostic and surgical implications. *Cancer.* 1984;8:2147-59.

**Cite this article as:** Sreeramulu PN, Nipun AC, Anup, Suresh VN. Leiomyosarcoma of vascular origin: a rare presentation. *Int Surg J* 2019;6:3841-4.