

Original Research Article

Study of upper gastrointestinal endoscopy in patients with gastrointestinal symptoms

Shashidhara Puttaraju^{1*}, Sudarshana Sreramaseshadri R. M.²

Department of General Surgery, ¹JSS Hospital, Chamarajanagar, ²JSS Medical College, Mysuru, Karnataka, India

Received: 13 July 2019

Revised: 04 September 2019

Accepted: 05 September 2019

***Correspondence:**

Dr. Shashidhara Puttaraju,

E-mail: dr.shashi85@gmail.com

Copyright: © the author(s), publisher and licensee Medip Academy. This is an open-access article distributed under the terms of the Creative Commons Attribution Non-Commercial License, which permits unrestricted non-commercial use, distribution, and reproduction in any medium, provided the original work is properly cited.

ABSTRACT

Background: Upper gastrointestinal (GI) symptoms are the commonest complaints among the general population and the diseases associated with them carries a significant risk of morbidity and mortality. Hence early diagnosis and appropriate management of the condition can prevent life threatening complications. Upper GI endoscopy is an effective diagnostic as well as therapeutic tool for the patients presenting with upper GI symptoms. The objective of the study is to show the effectiveness of upper gastrointestinal endoscopy as an initial diagnostic, screening and therapeutic tool in patients with upper GI symptoms.

Methods: Present study comprises of 100 patients presenting with upper gastrointestinal symptoms at JSS Hospital, Chamarajanagar (both out-patients and referred patients) during the period of October 2018 to June 2019, who underwent upper GI endoscopy.

Results: Out of 100 patients, 60 were males and 40 were females. In the study majority of the patients were found to have gastritis, esophagitis and acid peptic disease. Other patients had malignant changes, reflux disease, hiatus hernia, perforation, foreign body, obstruction and esophageal varices.

Conclusions: Upper GI endoscopy is a simple, safe, more reliable and valuable tool with easy learning curve. It will remain as the initial investigation of choice for the patients with upper GI symptoms. It plays a significant role as a screening, diagnostic as well as therapeutic tool.

Keywords: Upper gastrointestinal endoscopy, Gastrointestinal symptoms, Initial diagnostic, Therapeutic tool

INTRODUCTION

Upper gastrointestinal (GI) symptoms are the commonest complaints among the patients, for which they seek medical attention. Diseases associated with these symptoms are leading causes of morbidity and mortality worldwide.¹ Prevalence of upper gastro-intestinal symptoms (mostly commonly upper abdominal pain or discomfort) varies from approximately 8-54%, while the prevalence of heartburn varies from 10-48%, regurgitation varies from 9-45% and 21-59% for both.² The common upper GI symptoms are dyspepsia, dysphagia, gastrointestinal bleeding, progressive

unintentional weight loss, persistent vomiting or of unknown cause, anaemia or epigastric mass.³

Endoscopy is recommended as the first line of investigation for the patients presenting with upper gastro-intestinal symptoms.⁴ Upper GI endoscopy is a procedure that uses a small, flexible camera with a light source to examine the upper GI tract.³ It affords an excellent view of mucosal surfaces of the oesophagus, stomach, and proximal duodenum. Observations are made looking for focal benign or malignant lesions, diffuse mucosal changes, luminal obstruction, motility, and extrinsic compression by contiguous structures.

Standard diagnostic functions include inspection, biopsy, photography and video recording.⁵ A cost analysis also showed that endoscopy with therapeutic approach is more cost effective than an initial diagnostic approach with barium swallow in patients with upper gastro-intestinal symptoms.⁷

Objective

The objective of the study is to show the effectiveness of upper gastrointestinal endoscopy as an initial diagnostic, screening and therapeutic tool in patients with upper gastrointestinal symptoms.

METHODS

This study comprised of 100 patients who presented with upper gastro-intestinal symptoms and underwent endoscopy procedure in the JSS Hospital, Chamaranagar from October 2018 to June 2019. Informed consent from patients was obtained both for the procedure as well as for research purpose. After taking proper history and good physical examination, patients were subjected to fibre-optic upper GI endoscopy.

Patients were kept fasting over-night or 6 hours nil per oral. Pharyngeal spray with 10% xylocaine is sprayed topical before the procedure and asked to retain it for 10-15 minutes for local anaesthesia. Endoscopy was carried out by fibre optic flexible esophagogastroduodenoscopy (Olympus) by placing patient in left lateral position. A mouth guard was used to protect the instrument. Lubricated instrument was passed over the back of the tongue and under direct vision into the oesophagus. Subsequently the endoscope was advanced with clear view of lumen. During the whole procedure, examination of oesophagus, stomach and duodenum was done to look for abnormal areas in the form of swelling, ulcer, growth, fibrosis, bile reflux, varices and gastroesophageal reflux and were evaluated properly and biopsy was taken from suspicious areas and wherever required. Before withdrawal of endoscope from stomach, air and gastric contents were aspirated. The whole procedure is recorded by photography and videography for documentation and further follow-up.

Inclusion criteria

Patients above the age of 16 years with stable general conditions presenting with dyspepsia, dysphagia, odynophagia, nausea and vomiting, pyrosis, occult GI bleeding, cirrhosis (both outpatients and patients referred from other hospitals).

Exclusion criteria

- Pediatric patients <16 years.
- Massive upper gastrointestinal bleeding.
- Corrosive poisoning
- Unconscious and unstable patients.

RESULTS

Out of 100 patients, 60 males and 40 females (Figure 1), who presented with upper GI symptoms after history and clinical examination, underwent upper GI endoscopy and the results were found out to be following.

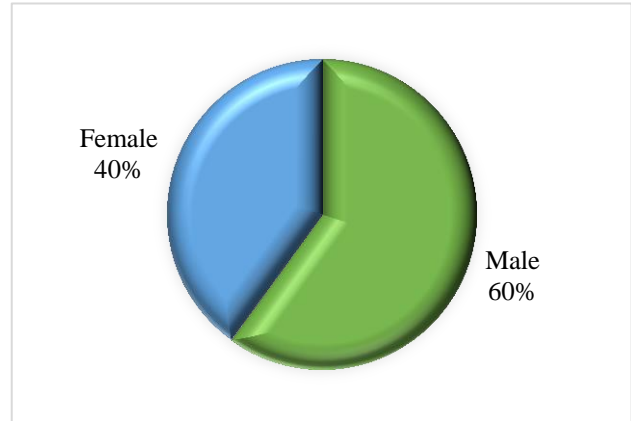


Figure 1: Sex ratio.

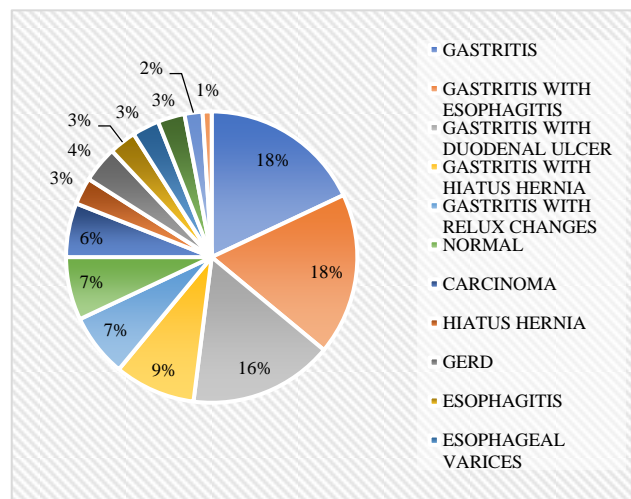


Figure 2: Results.

Most of the patients were found to gastritis and was seen in 18 (18%) cases; 10 (10%) were male and 8 (8%) were female, gastritis with duodenal ulcer (acid peptic disease) was seen in 16 (16%); cases 11 (11%) were males and 5 (5%) were female, gastritis with esophagitis was seen in 18 cases (18%); 13 (13%) were male and 5 (5%) were female, gastritis with hiatus hernia was seen in 9 (9%) cases: 7 (7%) were male and 2 (2%) were female, gastritis with reflux changes was seen in 7 (7%) cases: 4 (4%) were male and 3 (3%) were female. Esophagitis was found in 3 (3%) cases: 1 (1%) were male and 2 (2%) were female. Perforated duodenal ulcer was seen in 2 patients (2%); both were males. Esophageal varices were found in 3 (3%) cases; 3 were male. Malignant features were seen in 6 cases (6%), out of which 5 cases (5%) were esophageal carcinoma; 1 (1%) was male and 4 (4%) were female and 1 (1%) case was carcinoma stomach,

which was male. GERD was found in 4 cases (4%); 3 (3%) were male and 1 (1%) was female. Hiatus hernia was found in 3 cases; 2 (2%) were male and 1 (1%) was female. Obstructive features was found in 3 patients (3%), out of which 2 (2%) were found to have gastric outlet obstruction; both were males and 1 (1%) female had CBD obstruction involving the ampulla of Vater due to distal CBD stone. Foreign body (bone) was found stuck in posterior cricoid region in 1 case (1%) female and was removed through endoscope. 7 (7%) of cases; 1 (1%) male and 6 (6%) female, had normal study on endoscopy (Figure 2).

DISCUSSION

The clinical indications for upper gastrointestinal (UGI) endoscopy is, patients presenting with upper GI symptoms which includes dyspepsia that's refractory to treatment, dysphagia, upper GI bleeding, weight loss, anemia, foreign body in upper GI tract. There is no absolute contraindication for upper gastrointestinal endoscopy. Major complications such as perforation or aspiration are rare, occurring in less than 1 per 1000 cases.³

In this study, GI symptoms were found more common in males (60%) compared to females (40%). This might be due to alcoholism; smoking and lifestyle factors are more common in males compared to females.

The present study found that majority of patients with upper gastrointestinal symptoms were diagnosed to have gastritis which was found alone or found to be co-existing with other pathologies like esophagitis, GERD, Barrett's esophagus, hiatus hernia followed by reflux esophagitis, carcinoma esophagus and stomach, gastric ulcer and duodenal ulcer. Other findings were gastric outlet obstruction, perforation of hollow viscus and foreign body.

Gastritis is a condition in which the mucosa lining the stomach is inflamed, or swollen that can be acute or chronic. Common cause for gastritis is *Helicobacter pylori* infection, damage to the stomach lining, which leads to reactive gastritis and an autoimmune response. Other factors causing reactive gastritis are alcohol, cocaine, radiation exposure or having radiation treatments, reflux of bile from the small intestine into the stomach and a reaction to stress (stress gastritis).³ Endoscopy plays a vital role in diagnosis and to assess the severity of gastritis. Patient was started on PPI's and *H. pylori* kit and was advised to stop smoking, alcohol consumption and various methods of lifestyle modification to reduce stress.

Peptic ulcer disease is erosions in gastric or duodenal mucosa that extends through muscularis mucosa. Common causes are infection with *H. pylori* and use of nonsteroidal anti-inflammatory drugs. If untreated it may lead to complications like bleeding, perforation, gastric

outlet obstruction, giant gastric ulcers, refractory ulcers and malignant transformation may also occur. UGI endoscopy is more sensitive and specific for peptic ulcer disease and allows biopsy of gastric lesions.⁸

Perforation in peptic ulcer disease occurs in approximately 2 to 10 percent of peptic ulcers. It most commonly involves the anterior wall of the duodenum 60%, however it may also occur in antral 20% and lesser-curvature 20%. Hollow viscus perforation and resulting chemical and bacterial peritonitis is a surgical emergency that can cause sudden and rapid deterioration of general condition and requires immediate surgical intervention laparotomy and placement of an omental patch (Graham patch plication). In otherwise healthy patients with a history of chronic ulcer and minimal peritoneal contamination, definitive anti-ulcer procedure (vagotomy and drainage, highly selective vagotomy) may also be considered. Perforated gastric ulcers are treated with an omental patch, wedge resection of the ulcer, or a partial gastrectomy and re-anastomosis.⁸

5-8% of patients of peptic ulcer disease presents with gastric outlet obstruction. UGI endoscopy is recommended to determine the site, cause, and degree of obstruction.⁸ Biopsy was taken from the site to evaluate for the cause and found to be benign in nature. Patients were managed conservatively with nil per oral, nasogastric tube insertion for decompression and regular saline wash to reduce the oedema. On subsequent endoscopic studies, oedema reduced and the obstruction was relieved. Cholelithiasis develops in about 10-20% of patients with gall bladder stones and at least 3-10% of patients undergoing cholecystectomy will have common bile duct (CBD) stones. Multiple modalities are available for assessing patients for cholelithiasis, in which endoscopy stands as a simple and effective tool in diagnosis.⁹ Patients were referred to gastro-enterologist for endoscopic ultrasonogram (EUS) and ERCP with sphincterotomy was done for stone retrieval.

Gastroesophageal reflux disease (GERD) is the most common benign disorder of stomach and esophagus, which occurs when there is retro-grade flow of gastric contents through lower esophageal sphincter (LES), which results from the failure of endogenous anti-reflux mechanisms. GERD most commonly manifest as heart burns, which can gradually worsen causing complications like strictures, ulcers, metaplasia, dysplasia, carcinoma and pulmonary disease.¹⁰ Patients with GERD were sent for manometry studies and followed up with gastro-enterologist advice.

Gastric cancer is the 14th most common cancer and second leading cause of death from malignant disease worldwide, with especially high mortality rates. 90% of stomach tumors are adenocarcinomas, which are subdivided into two main histologic types as well-differentiated or intestinal type and undifferentiated or diffuse type. Multiple factors play role in etiology of

gastric cancer, more than 80% of cases have been associated with *H. pylori* infection. Other risk factors includes diet, genetic, socioeconomic, polyps and proton pump inhibitors also attributes to gastric carcinogenesis.¹¹ Carcinoma esophagus is the sixth leading cause of cancer-related mortality and the eighth most common cancer worldwide. Squamous-cell carcinoma is the predominant form of oesophageal carcinoma worldwide and others forms are adenocarcinoma, mesenchymal tumour, neuroendocrine tumour and benign tumours. Tobacco and alcohol are strong risk factors and others include achalasia, socioeconomic, GERD, Barrett's esophagus.¹² Patient with malignant changes found during endoscopy, adequate tissues (6 to 8) were taken from suspicious site and send for biopsy.

Herniation of the contents of the abdominal cavity most commonly the stomach is referred as hiatus hernia, through the esophageal hiatus of the diaphragm into the mediastinum. GERD is the main clinical manifestation of hiatus hernia. Other symptoms associated with hiatus hernia are reflux oesophagitis, Barrett's oesophagus and oesophageal adenocarcinoma. Hiatus hernia is of three types which are type 1 (sliding) hiatus hernia, which is the commonest and accounts for about 90%, type 2 (paraesophageal or rolling) hiatus hernia and type 3 are mixed types I and II i.e., with a sliding element to the type II hernia.¹³ Endoscopy plays a significant role in the diagnosis of hiatus hernia.

Varices are dilated sub-mucosal veins, that commonly occurs as consequences of portal hypertension. Mortality after an index haemorrhage in patients with varices is as high as 50% and with subsequent bleeding it's 30% mortality rate. Endoscopy plays an essential role in the management of varices as it identifies patients in initial stage and helps to prevent variceal haemorrhage and helps to initiate specific therapies.¹⁴

Foreign body ingestion is one of the common conditions seen in practice. 10-20% of ingested foreign bodies require treatment. Incidence of complications caused by foreign bodies in the upper gastrointestinal tract is 15-42%, that varies with time, higher the complications, longer the foreign bodies had been impacted. Complications were observed in 60% of foreign bodies that had been impacted for 48-72 h and 10.5% of those impacted for up to 24 h. These complications may vary from mild such as erosions, superficial lacerations, oedema, hematoma, and mild respiratory complications to severe forms such as perforation (most frequent), and haemorrhage resulting from injury to large vessels that could be fatal.¹⁵ UGI endoscopy is a safe and effective tool that helps in early removal of foreign bodies from the upper gastrointestinal tract.

CONCLUSION

Upper gastro-intestinal endoscopy is a simple, safe, more reliable and valuable tool with easy learning curve, it

enables direct visualization of the upper GI tract and when combined with histopathological examination helps in diagnosing as well as therapeutic interventions for patients with various pathologies. Upper GI endoscopy will remain as the initial investigation of choice for the patients presenting with upper GI symptoms. In our studies endoscopic findings correlated well with signs and symptoms of majority of patients.

Funding: No funding sources

Conflict of interest: None declared

Ethical approval: The study was approved by the Institutional Ethics Committee

REFERENCES

1. Patremane UM, Periyasamy V. Clinical study of endoscopic findings in patients presenting with upper GI symptoms. *J Evol Med Dent Sci.* 2017;6(94):6881-5.
2. Heading RC. Prevalence of upper gastrointestinal symptoms in the general population: a systematic review. *Scand J Gastroenterol.* 1999;231:3-8.
3. Shah JV, Shah S. Upper gastrointestinal endoscopy in early diagnosis of gastric disorders. *Int J Contemp Med Res.* 2016;3(7):1943-5.
4. Tytgat GN. Role of endoscopy and biopsy in the work up of dyspepsia. *Gut.* 2002;50(S4):13-6.
5. Early DS, Ben-Menachem T, Decker GA, Evans JA, Fanelli RD, Fisher DA, et al. Appropriate use of GI endoscopy. *Gastrointestinal Endoscopy.* 2012;75(6):1127-31.
6. Qureshi NA, Hallissey MT, Fielding JW. Outcome of index upper gastrointestinal endoscopy in patients presenting with dysphagia in a tertiary care hospital- a 10 years review. *BMC Gastroenterol.* 2007;7(1):43.
7. Pasha SF, Acosta RD, Chandrasekhara V, Chathadi KV, Decker GA, Early DS, et al. The role of endoscopy in the evaluation and management of dysphagia. *Gastrointestinal Endoscopy.* 2014;79(2):191-201.
8. Ramakrishnan K, Salinas RC. Peptic ulcer disease. *Am Fam Phys.* 2007;76(7).
9. Freitas ML, Bell RL, Duffy AJ. Choledocholithiasis: evolving standards for diagnosis and management. *World J Gastroenterol.* 2006;12(20):3162.
10. Yates RB, Oelschlager BK, Pellegrini CA. Gastroesophageal reflux disease and hiatal hernia. *Sabiston Textbook of Surgery.* 20th ed. Philadelphia, PA: Elsevier; 2017: 1043-1064.
11. Crew KD, Neugut AI. Epidemiology of gastric cancer. *World J Gastroenterol.* 2006;12(3):354.
12. Pennathur A, Gibson MK, Jobe BA, Luketich JD. Oesophageal carcinoma. *Lancet.* 2013;381(9864):400-12.
13. Gordon C, Kang JY, Neild PJ, Maxwell JD. The role of the hiatus hernia in gastro-oesophageal

reflux disease. *Alimentary Pharmacol Therapeutic.* 2004;20(7):719-32.

14. Hwang JH, Shergill AK, Acosta RD, Chandrasekhara V, Chathadi KV, Decker GA, et al. The role of endoscopy in the management of variceal hemorrhage. *Gastrointestinal Endoscopy.* 2014;80(2):221-7.
15. Chaves DM, Ishioka S, Felix VN, Sakai P, Gama-Rodrigues JJ. Removal of a foreign body from the

upper gastrointestinal tract with a flexible endoscope: a prospective study. *Endoscopy.* 2004;36(10):887-92.

Cite this article as: Puttaraju S, Sreramaseshadri SRM. Study of upper gastrointestinal endoscopy in patients with gastrointestinal symptoms. *Int Surg J* 2019;6:3595-9.