

## Original Research Article

# Evaluation of intracapsular total thyroidectomy as a safe method in benign thyroid diseases

Ahmed S. Elgamaal<sup>1</sup>, Asem Fayed<sup>1</sup>, Mohammed A. Elbalshy<sup>1</sup>, Mohamed M. Aziz<sup>2\*</sup>

Department of Surgery, <sup>1</sup>Menoufia faculty of Medicine, <sup>2</sup>Tala Central Hospital, Menoufia, Egypt

**Received:** 05 July 2019

**Revised:** 19 July 2019

**Accepted:** 21 July 2019

**\*Correspondence:**

Dr. Mohamed M. Aziz,

E-mail: [dr.mohamed.azizz@gmail.com](mailto:dr.mohamed.azizz@gmail.com)

**Copyright:** © the author(s), publisher and licensee Medip Academy. This is an open-access article distributed under the terms of the Creative Commons Attribution Non-Commercial License, which permits unrestricted non-commercial use, distribution, and reproduction in any medium, provided the original work is properly cited.

### ABSTRACT

**Background:** Intracapsular total thyroidectomy is a rising new technique in management of benign thyroid disease seeking for safety. Our aim in this study is to evaluate safety and effectiveness of intracapsular technique in treatment of benign thyroid disease.

**Methods:** this prospective study was carried out in department of general surgery, Menoufia University hospital and department of general surgery, Tala central hospital; from June 2018 to April 2019 on 58 patients with benign thyroid disease all had undergone intracapsular total thyroidectomy.

**Results:** 58 patients underwent intracapsular total thyroidectomy. There was no recurrent laryngeal nerve injury either transient or permanent and no external laryngeal nerve injury. There was no parathyroid injury or hypoparathyroid complications.

**Conclusions:** Intracapsular total thyroidectomy is a safe method in treatment of benign thyroid disease and can be done easily in central hospitals and non-highly specialized centres.

**Keywords:** Benign thyroid disease management, Intracapsular total thyroidectomy, Safe total thyroidectomy

### INTRODUCTION

There is continuous evolution in surgical management of thyroid diseases, from highly morbid to highly sophisticated surgery with minimal or even no morbidity.<sup>1</sup> Total thyroidectomy was initially introduced by Theodore Kocher 1880.<sup>2</sup> The aim of surgical treatment in benign thyroid disease is to treat with the less complications rate and decrease recurrence rate.<sup>3</sup> Nowadays there is uprising rate for total excision instead of subtotal excision in benign thyroid disease Muller et al reported that the rates of complications associated with total extracapsular thyroidectomy are 0.9% for recurrent nerve palsy 0.9% for hypocalcaemia, 0.9% for wound infection, and 0.6% for secondary haemorrhage.<sup>4</sup> Our aim in this study is to evaluate safety and effectiveness of

intracapsular technique in treatment of benign thyroid disease.

### METHODS

This prospective study carried out in department of general surgery, Menoufia university hospital and Tala central hospital, from June 2018 to April 2019 on 58 patients with benign thyroid disease they underwent intracapsular total thyroidectomy each patient provided his/her written consent to participate in the study. Continuous variables were presented as means and standard deviation, while categorical variables were expressed as percentages. A  $p < 0.05$  was considered statistically significant.

All statistical tests and analysis were performed by statistical package SPSS version 22 for Windows, Armonk, NY: IBM Corp.

Menoufia Faculty of Medicine Ethics Committee approved this study.

### ***Inclusion criteria***

Inclusion criteria were presence of primary toxic goiter after recurrence or failure of medical treatment; presence of secondary toxic goiter; presence of simple multinodular goiter.

### ***Exclusion criteria***

Exclusion criteria were presence of clinically and preoperative evidence of malignant goiter; presence of thyroiditis; presence of recurrent thyroid disease.

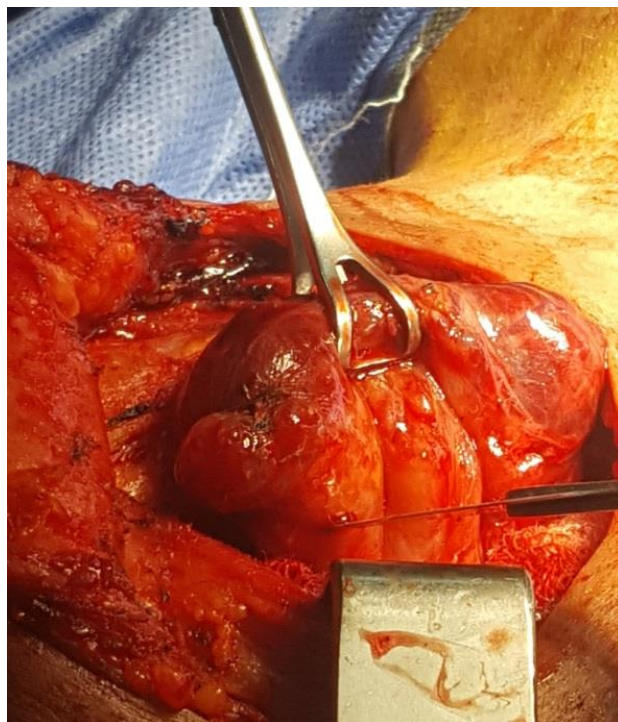
### ***Preoperative investigations***

- Routine tests CBC, LFTS, RFTS.
- Thyroid hormones tests: freeT3, freeT4, and TSH.
- Thyroid imaging: thyroid ultrasound and thyroid scan.
- Fine needle aspiration cytology (FNAC) when needed.
- Indirect laryngoscopy in all patients

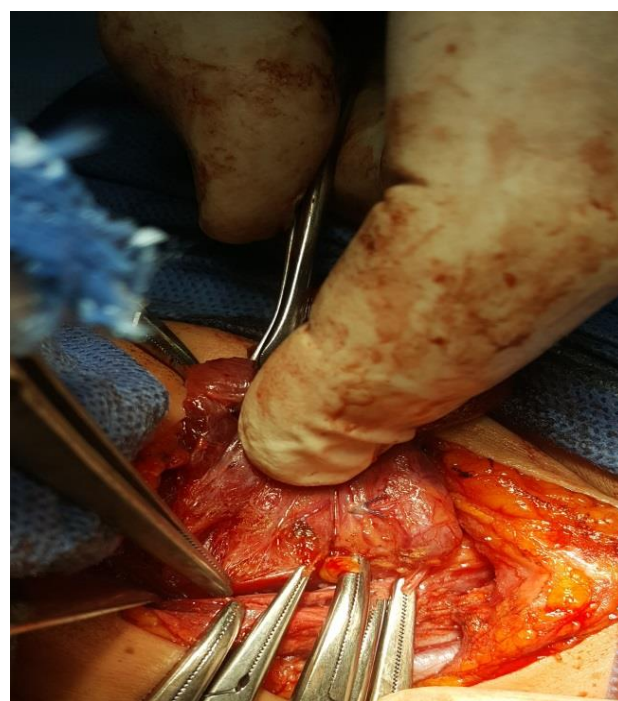
### ***Operative technique***

Proper positioning of the patient was made and sterilization of the skin was made. An incision is made in the skin two fingers above the sternal notch between the medial borders of the sternocleidomastoid muscles. The width of the incision may be extended if the thyroid mass is large. Subcutaneous fat and platysma are divided using diathermy. A subplatysmal flap is made above the incision up to the level of the thyroid cartilage above, and the sternal notch down. The fascia between the sternohyoid, omohyoid and sternothyroid muscles (strap muscles) is divided along the midline and the muscles is retracted laterally. The thyroid lobe is rotated medially by surgeon fingers to identify the middle thyroid vein (it will be tightly stretched by the medial rotation of the gland), which is then ligated. Identify the superior thyroid artery as close to the superior pole of the thyroid. Great care should be taken while ligating the superior thyroid artery so as to avoid injury to the external laryngeal nerve. Ligation of the inferior thyroid veins at the lower pole. Longitudinal incision was made in an avascular area of the lower part of the thyroid capsule on the middle to distal part of the gland. This longitudinal incision was extended with scalpel to open the whole capsule (Figure 1). Then the thyroid capsule was reflected off the gland with tissue forceps and the thyroid tissue was then moved away gently from the inside aspect of the thyroid capsule with a sterile tissue peanut to leave the capsule intact (Figure 2). Inferior thyroid artery was ligated from the

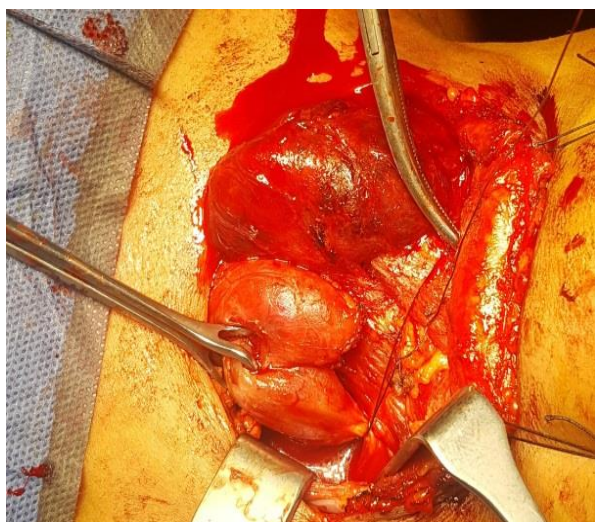inner aspect of the thyroid capsule (Figure 3). No attempts were made in looking for or identification of the recurrent laryngeal nerve from the outer aspect. No attempts were made to find parathyroid glands on each side of the thyroid lobe from the outer side for preserving intact blood supply to them removing of thyroid gland. Suction drain is put routinely in all our cases and left for 24 hrs or 48 hrs.



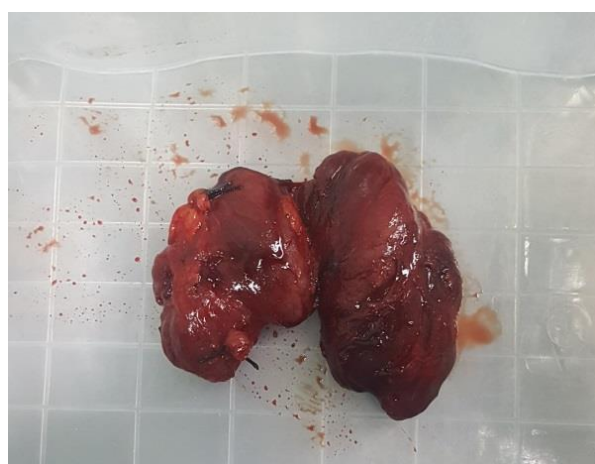**Figure 1: Opening of the thyroid capsule.**



**Figure 2: Dissection of the thyroid capsule.**



**Figure 3: Ligation of inferior thyroid artery.**



**Figure 4: Total thyroid gland.**

## RESULTS

This study included 58 patients with non-malignant thyroid disease underwent surgical treatment. They all underwent intracapsular total thyroidectomy.

**Table 1: Personal characteristics of the studied group (n=58).**

| Characteristics       | Patients  |
|-----------------------|-----------|
|                       | N (%)     |
| <b>Age (in years)</b> |           |
| Mean ±SD              | 36.39±9.8 |
| Range                 | 18-55     |
| <b>Sex</b>            |           |
| Females               | 38(65.52) |
| Males                 | 20(34.48) |

The patients mean age was 36.39±9.8 years range from (18-55) years. Twenty patients were males (34.48%) males and thirty eight were females (65.52) (Table 1).

**Table 2: Types of thyroid pathology.**

| Type of goiter pathology      | N (%)      |
|-------------------------------|------------|
| <b>Primary toxic goiter</b>   | 12 (20.68) |
| <b>Secondary toxic goiter</b> | 18 (31.03) |
| <b>Multinodular goiter</b>    | 28 (48.27) |

From the 58 patients twenty eight patients were diagnosed with simple multinodular goiter twelve were primary toxic goiter and eighteen patients were diagnosed with secondary toxic goiter. In fifty eight patients was no postoperative recurrent laryngeal nerve injury found (0%) (Table 2).

**Table 3: Complication operative complications in the studied group.**

| Operative complication (type )                                    | N (%) |
|---|-------|
| <b>Recurrent laryngeal nerve injury (transient and permanent)</b> | 0 (0) |
| <b>Parathyroid glands injury (hypocalcaemia manifestations)</b>   | 0 (0) |
| <b>Superior laryngeal nerve injury</b>                            | 0 (0) |
| <b>Wound complications</b>  | 3 (5) |

No postoperative hypocalcaemia manifestations found no postoperative SLN injury (low-pitched voice) found 3 (5%) patients wound was complicated with seroma. Operative blood loss mean was 110±50 ml the mean operative time mean was 89.1±10.5 min and hospital stay was 1.01±0.5 day (Table 3).

## DISCUSSION

total thyroidectomy in benign thyroid disease is the new standard technique instead of subtotal thyroidectomy due to high risk of complications in reoperations due to recurrence in subtotal thyroidectomy.<sup>5-6</sup> So in seeking for more safe surgical technique intracapsular total thyroidectomy was a solution to minimize the complications of the total thyroidectomy in the traditional extracapsular technique which happens due to recurrent laryngeal nerve injury in lateral dissection or parathyroid glands injury these are the two major complications in the traditional extracapsular.<sup>7-9</sup> Many studies suggest that the new technique of intracapsular total thyroidectomy is a safe method in terms of recurrent nerve injury or parathyroid gland injury because in the intracapsular thyroidectomy the capsule is opened and thyroid tissue is enucleated from the capsule leaving the recurrent laryngeal nerve under the capsule and its blood supply intact also the parathyroid gland lies beneath the thyroid capsule and by the intracapsular technique the parathyroid is preserved and its blood supply. Sewefy et al made study on 224 patients 112 patients underwent intracapsular total thyroidectomy and 112 patients underwent extracapsular total thyroidectomy and found that by intracapsular method the complication of recurrent laryngeal nerve injury was 0% compared to

0.9% in extracapsular method and permanent hypocalcaemia was 0% in intracapsular method compared to 0.9% in extracapsular method.<sup>11</sup> Meer et al made retrospective study on patients on tertiary care center and complications was counted from this technique and found that 0% cases complicated from permanent recurrent laryngeal nerve damage and temporary neuropraxia was around 0.5% and The incidence of temporary and permanent hypocalcaemia was found to be around 0.7% and 0.2% respectively.<sup>12</sup>

Dong y et al made retrospective study on 44 patients underwent thyroid capsular dissection and the result was 1 patient suffered from postoperative hoarseness of voice.<sup>13</sup> Rageh et al made prospective study on 50 patients who all underwent intracapsular total thyroidectomy none of the patients 0% suffered from RLN palsy postoperative and there was no parathyroid gland complications.<sup>14</sup> All of these studies suggest that the new technique is easy to learn and do by junior surgeons which make it perfect choice in secondary health centres like central hospital in which study was made because the previous studies was done only in highly specialized centres like universities hospitals or endocrine surgery centres only.<sup>11</sup> In the new technique time in searching for recurrent laryngeal is saved as in intracapsular dissection no time spent in searching for recurrent laryngeal nerve or parathyroid glands.<sup>14</sup>

## CONCLUSION

Intracapsular total thyroidectomy is a safe method in treatment of benign thyroid disease and can be done easily in central hospitals and non-highly specialized centres.

## ACKNOWLEDGEMENTS

We thank our colleagues from Department of Surgery, Menoufia faculty of Medicine and Department of Surgery, Tala central hospital for their assistance and comments that greatly improved the manuscript.

*Funding: No funding sources*

*Conflict of interest: None declared*

*Ethical approval: The study was approved by the Institutional Ethics Committee by Menoufia ethical committee*

## REFERENCES

- Dadan J, Nowacka A. A journey into the past – The history of thyroid surgery. *Wiad Lek.* 2008;61:88-92.
- Delbridge L. Total thyroidectomy: The evolution of surgical technique. *ANZ J Surg.* 2003;73:761-8.
- Harrison BJ, Maddox PR, Smith DM. Disorders of the thyroid gland. In Cuschieri A, Steele RJ, Moosa AR, eds. *Essential surgical practice.* 4th ed. London: Arnold; 2002;2:95–110.
- Muller PE, Kabus S, Robens E, Spelsberg F. Indications, risks, and acceptance of total thyroidectomy for multinodular benign goiter. *Surg Today.* 2001;31:958–62.
- Pappalardo G, Guadalaxara A, Frattaroli FM, Illomei G, Falaschi P. Total compared with subtotal thyroidectomy in benign nodular disease. *Eur J Surg.* 1998;164(7):501-6.
- Salman YG, Hassan AA. Total and near-total thyroidectomy is better than subtotal thyroidectomy for the treatment of bilateral benign multinodular goiter-a prospective analysis. *Br J Med Med.* 2011;1:1-6.
- Serpell JW, Phan D. Safety of total thyroidectomy. *ANZ J Surg.* 2007;77:15-9.
- Koyuncu A, Dokmetas HS, Turan M, Aydin C, Karadayi K, Budak E, et al. Comparison of different thyroidectomy techniques for benign thyroid disease. *Endocr J.* 2003;50(6):723-7.
- Jessie WU, Harrison B. Hypocalcaemia after thyroidectomy: the need for improved definitions. *World J. Endocr. Surg.* 2010;2(1):17-20.
- Lee JS, John ES, Panajiotis NS. *Surgical Anatomy and Technique: a Pocket Manual,* 3d ed, New York, Springer Business Media LLC; 2009: 33-38.
- Sewefy AM, Tohamy TA, Esmael TM, Atyia AM. Intra-capsular total thyroid enucleation versus total thyroidectomy in treatment of benign multinodular goiter: A prospective randomized controlled clinical trial. *Int J Surg.* 2017;45:29-34.
- Chisthi MM, Kuttanchettiyar KG. Capsular dissection technique for reducing recurrent laryngeal neuropraxia and temporary hypoparathyroidism after thyroidectomy: a single center experience. *Int J Otorhinolaryngol Head Neck Surg.* 2015;1(1):17-22.
- Dong Y, Yuan H, Jiang H. Application of meticulous capsular dissection technique in thyroidectomy. *J Clin Otorhinolaryngol Head Neck Surg.* 2013;27(9):455-6.
- Rageh TM, ElGammal AS, Elsisy A, Gaber A. Intracapsular total thyroidectomy: no more complications in benign thyroid diseases. *Egypt J Surg.* 2016;35:445-8.

**Cite this article as:** Elgamaal AS, Fayed A, Elbalshy MA, Aziz MM. Evaluation of intracapsular total thyroidectomy as a safe method in benign thyroid diseases. *Int Surg J* 2019;6:2682-5.