

## Case Report

# An uncommon presentation of cryptorchidism

Ipseet Mishra<sup>1\*</sup>, Washim Mollah<sup>2</sup>, Arup Kumar Dutta<sup>3</sup>, Rohan Kumar<sup>4</sup>

<sup>1</sup>Department of Surgical Oncology, Saroj Gupta Cancer Centre and Research Institute, Thakurpukur, Kolkata, India  
<sup>2</sup>Department of General Surgery, <sup>3</sup>Islampur Super speciality Hospital, <sup>3</sup>Raiganj Super speciality Hospital, Uttar  
Dinajpur, <sup>4</sup>Calcutta National Medical College and Hospital, Kolkata, West Bengal, India

**Received:** 03 July 2019

**Accepted:** 12 August 2019

### \*Correspondence:

Dr. Ipeet Mishra,

E-mail: drimishra13@gmail.com

**Copyright:** © the author(s), publisher and licensee Medip Academy. This is an open-access article distributed under the terms of the Creative Commons Attribution Non-Commercial License, which permits unrestricted non-commercial use, distribution, and reproduction in any medium, provided the original work is properly cited.

### ABSTRACT

Cryptorchidism as a cause of bowel obstruction is very unsuspecting. Bowel obstructions in cases of cryptorchidism, though reported were mostly as a complication of malignant transformation. Only two case reports of cryptorchidism document a non-malignant aetiology for bowel obstruction. This case is of a 16 year old boy referred for pain abdomen and obstipation for last 3 days. He had signs of peritonitis on examination and so, urgent exploratory laparotomy was planned. A loop of jejunum of approx. 30 cm length at a distance of 35 cm from duodeno-jejunal junction was found gangrenous with gubernacular bands around the loop emerging from a left cryptorchid testis. Resection– anastomosis was done along with left orchidectomy. Histopathology revealed an atrophied testis with no malignant changes. This is the first case report of a non-malignant cryptorchid testis as a cause of strangulated intestinal obstruction in literature.

**Keywords:** Cryptorchidism, Intestinal obstruction, Strangulation

### INTRODUCTION

Strangulated small bowel obstruction, by compromising blood flow, may lead to intestinal perforation, ischemia, and necrosis. Post-operative adhesions and hernia are considered the most common causes of strangulated small bowel obstructions. Cryptorchidism has been, in rare instances reported as a cause of acute abdomen due to either testicular torsion, malignancy or rupture in literature.<sup>1-3</sup> However, considering its rarity, cryptorchidism as a cause of small bowel obstruction is very unsuspecting.<sup>4</sup> This was the first case report documenting a strangulated small bowel obstruction in an adolescent male with unilateral non-malignant cryptorchidism.

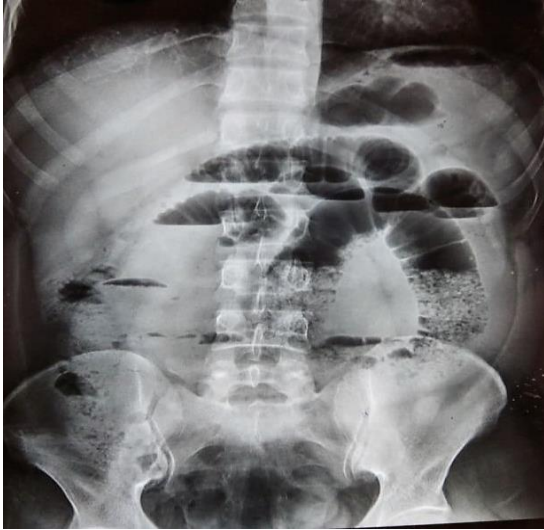### CASE REPORT

A 16 year old adolescent male got referred to the Casualty OT with complaints of pain abdomen, nausea and vomiting for the last 3 days with obstipation for last

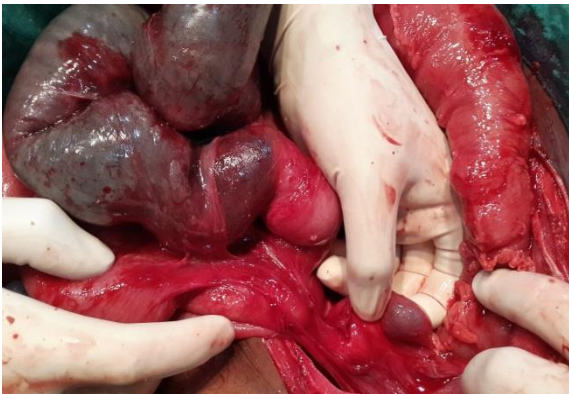24 hours. The patient had no prior hospitalizations - major illness or surgery and had not experienced any such pain episodes before. He is the only living issue of his parents and his family history is unremarkable. He never had any addictions and there is nothing significant in his developmental history.

On examination, the patient had the following parameters: Pulse-118/min, BP-100/76 mmHg, Temp-101.6°F, Respiratory rate-26/min and SpO<sub>2</sub>-94% with room air. Local examination revealed a distended tender abdomen with absent peristaltic sounds and positive rebound tenderness. The tenderness was maximum in the periumbilical region. Per-rectal examination was unyielding. Examination of hernial orifices and external genitalia was normal except for an empty left hemiscrotum- undescended left testis. Blood profiling was within normal limits except for Total leucocyte count – 16000/cmm and Albumin level – 2.6 gm%. Abdominal X-ray had multiple air-fluid levels with dilated loops suggestive of a small bowel obstruction (Figure 1). With

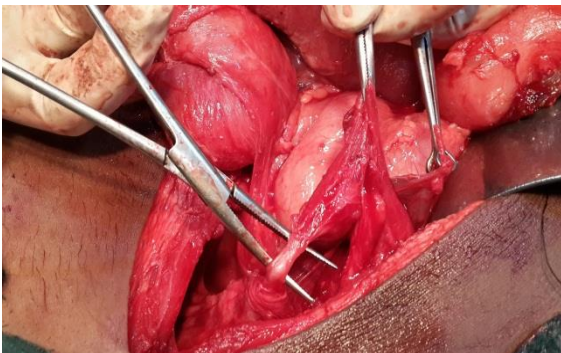
a presumptive diagnosis of peritonitis from small bowel obstruction, the patient was resuscitated with intravenous (IV) fluids, IV cefuroxime, and nasogastric tube decompression. Proper written consent was taken before proceeding for exploratory laparotomy.



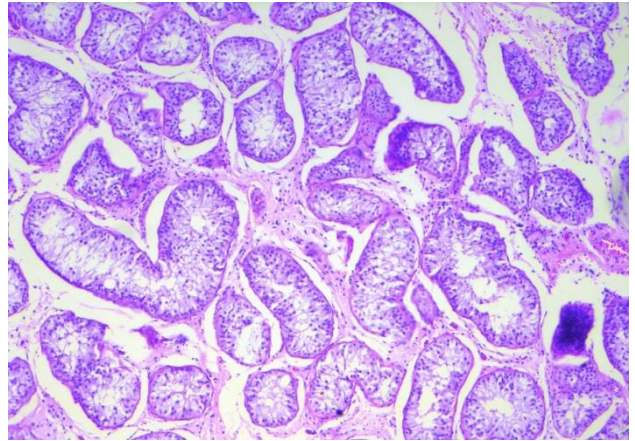
**Figure 1: Abdominal X-ray- multiple air-fluid levels and dilated loops.**



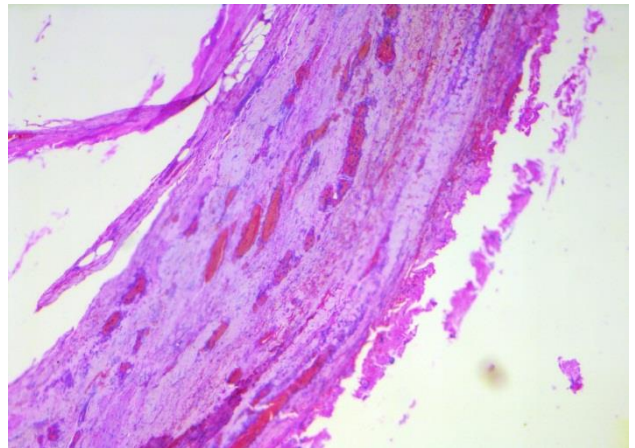
**Figure 2: Gangrenous jejunal loop with left cryptorchid testis after dissecting gubernacular bands.**



**Figure 3: Vas deferens displayed over open artery forceps.**



**Figure 4: Seminiferous tubules lined by Sertoli cells and Leydig cells (in 10X haematoxylin and eosin stain).**



**Figure 5: Loose textured fibrocollagenous tissue in adhesive gubernacular bands (in 10X haematoxylin and eosin stain).**

On exploration under general anaesthesia, approx. 30 cm length of the jejunum at a distance of 35 cm from duodeno-jejunal junction was found gangrenous with bands around the loop emerging from 3 cm x 4 cm firm mass in the left paracolic gutter (Figure 2). Upon further dissection, the swelling was identified to be left undescended testis with gonadal vessels and vas deferens attached to it. The adhesive bands around gut loops were excised while undescended testis was dissected out after ligating vessels and vas deferens (Figure 3). The gangrenous gut loop was resected and side-to-side two-layered anastomosis was done after a thorough peritoneal wash. The patient had an uncomplicated recovery and was discharged on postoperative day 6. The histopathologic reports confirmed the features of an atrophic testis– seminiferous tubules lined by Sertoli cells and Leydig cells; a few tubules contain spermatogonia. No spermatid or spermatozoa was found. There was no evidence of neoplasia and the testis was surrounded by thick bands of fibrocollagenous tissue (Figure 4). The adhesive bands, in histology, showed loose textured

fibro-collagenous tissue infiltrated by inflammatory cells, indicative of Gubernaculum testis (Figure 5).<sup>5</sup>

## DISCUSSION

Mechanical small bowel obstruction is the most frequently encountered surgical disorder of the small intestine with intra-abdominal adhesions accounting for nearly three-fourths of its cases. In the absence of previous surgery, less prevalent aetiologies like hernias, malignancies, Crohn's disease, strictures, diverticulitis, foreign bodies or congenital abnormalities should be looked for.

Congenital abnormalities causing small bowel obstruction usually become evident during childhood, however, they sometimes elude diagnosis and are detected for the first time in adult patients presenting with abdominal symptoms.

Cryptorchidism is apparently diagnosed on grounds of trauma, torsion, malignancy, infertility or psychological impact. Although very rare as a cause of mechanical obstruction of both small and large bowel, cryptorchidism had been reported in few literatures in this regard.<sup>6</sup> Previously bowel obstructions in cases of cryptorchidism were reported from either direct adhesion to gut loops or internal herniation or as a complication of malignant transformation—torsion, mass effect, and rupture/haemorrhage.<sup>1-3,4,7</sup> Only two case reports chronicle a non-malignant aetiology. Kim et al had reported a case of small bowel obstruction due to direct adhesion of cryptorchid testis to distal ileum in a 67-year-old man.<sup>4</sup> In another case, Bassiouny et al had reported of small bowel obstruction in a 2 year old boy from internal herniation, formed by adhesion of the gubernaculum of the right cryptorchid testis to the terminal small bowel loop.<sup>7</sup>

A plausible mechanism of strangulation in our case could be from secondary volvulus. With gubernacular attachments from undescended testis acting as a fulcrum against the fixed duodeno-jejunal junction, the rotated small gut could have compromised its vascularity and had developed peritonitis from strangulation.

Our case emphasizes on the benefits of orchidectomy in preventing undesirable complications in cryptorchid patients presenting after childhood stage who still had not

received orchiopexy procedure. The necessity of reporting this case is for reminding that intra-abdominal testis can develop acute life-threatening complications which should be considered in any patient with acute abdominal symptoms and an empty scrotum. To conclude, it is advisable to keep an open mind in dealing with patients of intestinal obstruction from such atypical and rare causes.

*Funding: No funding sources*

*Conflict of interest: None declared*

*Ethical approval: Not required*

## REFERENCES

1. Tomasz S, Lukasz S, Mirosław T. Torsed intraabdominal testicular tumour diagnosed during surgery performed due to suspicion of acute appendicitis. *Pol J Surg.* 2012;84(10):526–30.
2. Ciftci F, Benek S, Kezer C. A Rare Cause of Mechanical Intestinal Obstruction: A Neoplastic Intra-Abdominal Testis. *Int Surg.* 2016;101:167-70.
3. Singh P, Bajaj K, Kaur R, Mishra A, Riar H. Ruptured Seminoma of Undescended Testis Presenting as Acute Abdomen: Case Report with Literature Review. *Ann Med Health Sci Res.* 2013;3(1):108–9.
4. Kim CW, Min GE, Lee S-H. Small bowel obstruction caused by cryptorchidism in an adult. *Annals Surg Treatment Res.* 2017;93(5):281–3.
5. Erik T, Johansen B, Blom GP. Histological Studies of Gubernaculum Testis Taken During Orchiopexies. *Scandinavian J Urol Nephrol.* 1988;22(2):107-8.
6. Merdad A, Mosli H, Nassif O. Seminoma of an Undescended Testis Presenting As Incomplete Large Bowel Obstruction. *J King Abdulaziz Univ Med Sci.* 1994;4:71-7.
7. Bassiouny IE, Abbas TO, Alansari AN, Ali MA. Unique Presentation of Intra-Abdominal Testis: Small Bowel Obstruction. *ISRN Urol.* 2011:579153.

**Cite this article as:** Mishra I, Mollah W, Dutta AK, Kumar R. An uncommon presentation of cryptorchidism. *Int Surg J* 2019;6:3430-2.