

Original Research Article

Laparoscopic repair of umbilical and paraumbilical hernias: a prospective and interventional study in government hospital

Kiren B. Patel, Mithun V. Barot*

Department of Surgery, Pramukhswami Medical College, Karamsad, Anand, Gujarat, India

Received: 13 June 2019

Revised: 22 July 2019

Accepted: 29 July 2019

***Correspondence:**

Dr. Mithun V. Barot,

E-mail: mithunbarot@gmail.com

Copyright: © the author(s), publisher and licensee Medip Academy. This is an open-access article distributed under the terms of the Creative Commons Attribution Non-Commercial License, which permits unrestricted non-commercial use, distribution, and reproduction in any medium, provided the original work is properly cited.

ABSTRACT

Background: Umbilical and ventral hernia occurs as a result of weakness in musculofascial layer of anterior abdominal wall. The most important causes are congenital, acquired, incisional and traumatic. UH and VH can be repaired by open surgical procedure. A successful series of laparoscopic repair of umbilical hernia and VH was done by Le blanc in 1993. The cost can be optimised by selection of mesh and optimal uses of transabdominal suture and various fixation devices. This original article reveals methods, techniques, indication, contraindication, post-op pain, operative time, surgical site infection recurrence and outcome of laparoscopic umbilical hernia and paraumbilical hernia repair.

Methods: A total of 21 patients of ventral hernia (umbilical, paraumbilical and incisional), who underwent laparoscopic hernia repair from October 2014 to October 2016, were selected have taken part in study with valid consent, in B.J. Medical College Ahmedabad Gujarat. All patient study regarding operative time, postoperative pain, postoperative hospital stay, surgical site infection like wound infection, seroma, hernia defect size, mean drain removal and recurrence.

Results: Out of 21 patients male are 33% and female are 67%. Mean age of patients is 45 yrs with range being 18-65 yrs. 28%, 33.33%, and 38.1% of patient had umbilical, paraumbilical and incisional hernia respectively. Mean size defect was 7.8 cm². Mean operative time in this study is 98.6 minute. Mean drain removal is 2.80 day. Mean postoperative hospital stay was 3.3 days. 4.7% had wound infection, 9.5% had seroma formation. There is 0% recurrence in present study.

Conclusions: The laparoscopic approach appears to be safe, effective and acceptable. It is also effective in those who are obese, with co morbidities (complex) and who have recurrence from prior open repair and having ascites.

Keywords: Laparoscopic umbilical and paraumbilical hernia repair, Minimal invasive surgery, Hernia recurrence, Surgical mesh

INTRODUCTION

The word “hernia” is derived from a Latin term meaning “a rupture.” A hernia is defined as an area of weakness or complete disruption of the fibro muscular tissues of the body wall. Structures arising from the cavity contained by the body wall can pass through, or herniated, through such a defect.¹ Hernia of anterior abdominal wall, or

ventral hernias, represents defects in the parietal abdominal wall fascia and muscle through which intra-abdominal or preperitoneal content can protrude. Ventral hernia may be congenital or acquired. Acquired hernia may develop via slow architectural deterioration of the musculoaponeurotic tissue, or they may develop from failed healing of an anterior abdominal wall incision.¹⁻³ Umbilical hernia occur at the umbilical ring and may be

present at birth or develop later in life. Umbilical hernias are present in approximately 10% of all newborns and are more common in premature infants. Most of the congenital hernias close spontaneously by five years. In adult with small, asymptomatic umbilical hernia should be followed clinically. Surgical treatment is offered if hernia is observed to enlarge or associated with symptoms or if incarceration occur. Surgical treatment can consist of primary suture repair or placement of prosthesis mesh for large defect (>2 cm) using open or laparoscopic method.⁴

Over the last decade, the laparoscopic repair of ventral hernia has been used with increasing frequency. It is based on principle of Rives-Stoppa repair in which mesh is placed deep to the hernia defect and fixed with mesh coverage to healthy abdominal wall fascia using point fixation and full-thickness permanent suture.^{4,5} However, with the introduction of new mesh types, laparoscopic ventral hernia repair LVHR is gaining increasing acceptance and a recurrence rate as low as 0–3% was reported.^{4,6} The Laparoscopic repair differs in that the mesh is placed inside the peritoneal cavity rather than retro-rectus position, a technique made possible by the advent of new two layered biosynthetic material (mesh) that promote tissue in growth in one side and prevent tissue in growth in another side. The laparoscopic ventral hernia repair allows for clear visualisation of the abdominal wall, and secure fixation to abdomen.^{5,7} This study included various aspects of Repair of umbilical and paraumbilical Hernia in view of advantage of Laparoscopic repair in compare to open repair in terms of post op SSI, recurrence, post op pain, efficacy, technical variation, operative time.

METHODS

Study design

The study was conducted at the department of General Surgery, Civil hospital, Ahmedabad, a publicly funded tertiary care institution. A prospective and interventional study of 21 patients with symptoms of umbilical and ventral hernia were admitted for elective surgery.

Study period: October 2014–October 2016.

Inclusion criteria

Inclusion criteria were patients diagnosed with small to medium size umbilical and paraumbilical hernia; patients willing to participate in study and give informed written consent; patients of both genders were between 15 to 55 years.

Exclusion criteria

Exclusion criteria were patient not fit for spinal anaesthesia; patients of <15 and >55 year age; patients of generalised peritonitis; patients not willing for

laparoscopic hernia repair; pregnant females and large hernia.

Pre-operative

The diagnosis will be made by history, clinical examination and ultrasound examination in selected cases of ventral hernia. All patients were evaluated for systemic disease or precipitating cause. Patient will be admitted to surgical ward two days prior to operation. The procedure will be explained to the patient and written and informed consent will be taken. Routine preoperative investigations as per fitness are done. Ultrasound of abdominal –pelvis screening will be done. A day prior to surgery, clipping of the hair of abdomen and genitalia was done. A day prior to surgery, clipping of the hair of abdomen and genitalia will be kept nil by mouth 8 hours prior to surgery. Patient takes bath with antiseptic soap both evening before and on day of surgery. A nasogastric tube is passed and Foley's catheterization done. Patient will be given injectable antibiotic prior to making incision.

Intra operative

The procedure is performed under G/A, patient is given antibiotic prophylaxis and stomach and bladder are decompressed.

An alternative puncture site is chosen away from the primary hernia defect and any abdominal incision. A skin incision is made and a Veress needle is inserted at Palmer's point. The abdomen is insufflated with CO₂ and 30 degree laparoscope is introduced through the same incision (Figure 1).

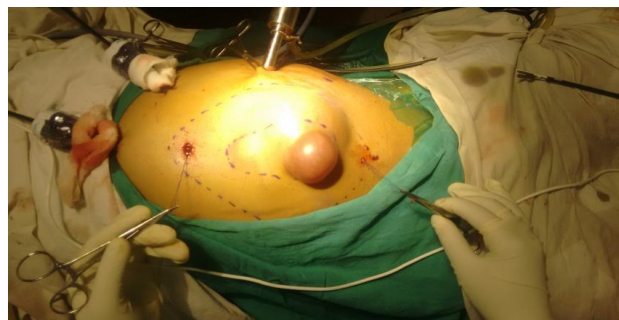

Figure 1: Port placement in umbilical hernia.

Under direct vision, additional 11 mm trocars are inserted as far lateral as possible additional 11 mm trocars are introduced on the opposite side laterally under direct vision. Direct vision and palpation allows identification of the edges of the hernia defect (Figure 1 and 2). Adhesiolysis is performed utilizing an Endo-Babcock to provide exposure and counter traction of hernia contents and adhesions, which are lysed with endoscopic shears by sharp and blunt dissection.

If the adhesions are dense and involve the bowel, a harmonic scalpel is utilized for adhesiolysis to

decrease likelihood of bowel injury and obtain adequate haemostasis.

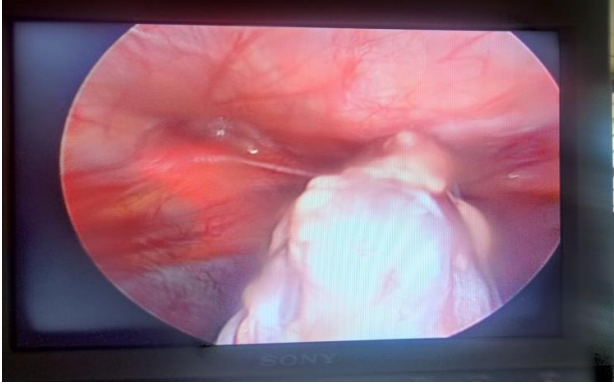


Figure 2: Intraoperative picture of hernia content going inside defect.

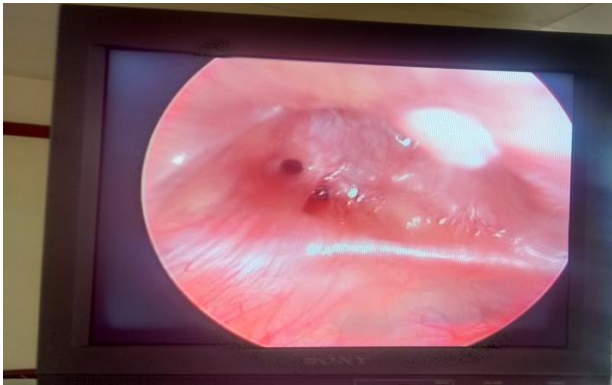

Figure 3: Hernia sac content reduced.

All the hernia sac contents are reduced into peritoneal cavity. The hernia sac is left in situ (Figure 3).




Figure 4: Mesh cut to size with edge fixation.

The edges are then drawn on the abdominal wall, and 1-mm thick Gore-tex dual mesh biomaterial is measured to overlap the defect by at least 3 cm in all directions and cut to the appropriate size. Sutures are placed and tied at all four corners and sutures are left approximately 6 inch long. One or two additional suture of Ethibond (for colour contrast) are placed at edge of patch is rolled up. The patch is grasped at one end with an Endo-Babcock

clamp. One of the trocar is removed and the patch is then introduced into the abdominal cavity. Using 5 mm graspers the free edge of the patch is grasped and the Ethibond suture is pulled unrolling the patch (Figure 4).

The corners that are drawn on the anterior abdominal wall are then identified intraabdominal. The endoscopic suture – passer is then passed through a small skin incision of about 2 mm and the suture previously placed at the corner of patch are grasped with needle driver and loaded into the endoscopic suture-passer and pulled extracorporeal, tied and pushed down through the subcutaneous fat to anterior fascial layer.

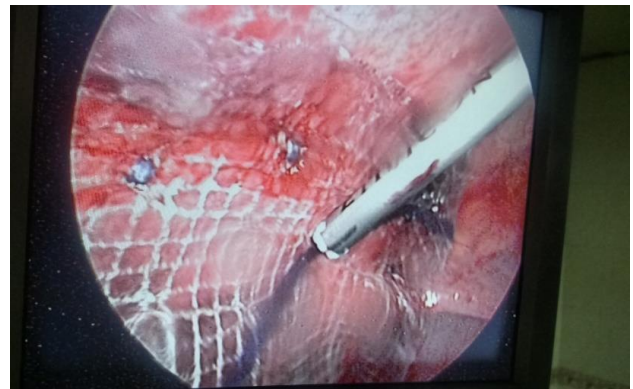


Figure 5: Mesh fixation with tackers.

After this, complete the stapling of mesh circumferentially, additional non absorbable 2-0 suture are placed circumferentially using the endoscopic suture-passer. The sutures are placed at approximately 5 cm interval around the entire circumference of the patch (Figure 5).

Post-operative

Visual analogue scale used to evaluate postoperative pain. Nasogastric tube is removed once the patient passed flatus. Dressing was assessed every 12 hourly and changed if it is soaked. Foley's catheter is removed postoperative period. Suction drain removed by 2nd postoperative day and kept in situ for more days if discharge was >30 ml/day. Postoperatively, deep-breathing exercises are encouraged. Skin sutures removed on 10th day and in few cases after 10th day. Patients were followed up at 1 month, 3 month and 6 month interval. Complications such as seroma formation, wound infection, mesh infection; mesh migration and recurrence of hernia are noted and compared.

RESULTS

A total of 21 patients of ventral hernia (Umbilical, paraumbilical and Incisional), who underwent Laparoscopic hernia repair from October 2014 to October 2016, were selected. Following parameters were observed and analysed.

Table 1: Age distribution.

Age group	No of patients (n=21)	%
0-20	1	4.8
21-40	6	28.6
41-60	11	52.4
61-80	3	14.2

Table 2: Gender distribution and mean age.

Gender	No of patients (n=21)	%	Mean age
Male	07	33.33	44.67 yrs
Female	14	66.67	

In present study 70% of patients were female and 30% patients were male. The incidence of ventral hernia is more common in female patient. In present study mean age of patient is 44.67 year with a range being 18-65 years. In present study most of patient has swelling in abdomen, which reduces on lying down, with abdominal pain are most common symptoms which is followed by constipation and persistent cough. Abdominal distension and nausea presents in two cases. No one has complained of vomiting.

Table 3: Type of hernia.

Type of hernia	No. of patient (n=21)	%
Umbilical	6	28.6
Paraumbilical	7	33.33
Incisional	8	38.1

Incisional hernia is the most common type of ventral hernia in this study, having 38.1% patients of incisional hernia, in which 5 are operated by laparoscopy and 3 are from open repair, while 28.6% have umbilical and 33.1% have paraumbilical hernia are included in the study and were operated laparoscopy.

Table 4: Mean size of hernia defect, operative time, post-op hospital stay, drain removal and infection and recurrence.

Present study (n=21)	
Size of defect (cm ²)	7.8 cm ²
Mean operative time	98.6 minute
Mean post-op hospital stay	3.3 days
Mean drain removal	2.8 days
Wound infection	4.7%
Seroma formation	9.5%
recurrence	0%

Mean size of hernia defect is 7.8 cm². Mean operative time is 98.6 minute in present study.

In present study after laparoscopic ventral hernia repair has less postoperative pain in present study compare with other study, as assessed by visual analogue scale at

postoperative day 1, 3,7 and postoperative month 3 and 6. No patient developed chronic pain after surgery. In present study mean drain removal and mean hospital stay is 2.8 days and 3.3 days respectively in present study 4.7% and 9.5% of patient have wound infection and seroma formation with 0% of recurrence rate.

DISCUSSION

Early studies to describe laparoscopic repair of incisional hernia were published in 1993.⁸ However, recent years have witnessed increasing reports describing the different aspects of the technique, instruments and types of meshes used. LVHR is gradually replacing the open ventral hernia repair OVHR in many centres throughout the world, especially in western countries. The published literature indicates fewer wound-related and overall complications and a lower rate of hernia recurrence for LVHR compared to OVHR.⁹ Other advantages of laparoscopic repair such as shorter operative time and hospitalization, a faster return to work; in addition to a lower incidence of wound infections and major complications, are well documented in the literature.^{10,11}

Umbilical hernias generally develop from small fascial defects. Because of their size, a common practice is to repair the defect with primary sutures with the patient under local anaesthesia with sedation on an outpatient basis. Recurrence rates of up to 15% have been associated with this technique.¹² The use of prosthetic materials during inguinal and ventral hernia repairs has reduced the incidence of recurrences. In a prospective randomized trial of 200 patients followed for 64 months, Arroyo and colleagues⁷ recently reported the same results for umbilical hernia repairs, with recurrence rates of 11% and 1% after PSR and ORWM, respectively. They found no difference in recurrence rates following repair of defects greater or smaller than 3 cm. The main concern surrounding the use of a prosthetic material for hernia repair is its association with complications, such as wound infections, seroma, mesh extrusion, fistula formation, and adhesions.¹³ Infections occur in 15% to 45% of patients following open hernia repair with mesh materials. These infections closely correlate with recurrence rates.^{13,14} both may be secondary to the larger incision with which the mesh is in contact and the wider soft tissue dissection needed for mesh placement. The laparoscopic technique for ventral and incisional hernia repairs has resulted in decreased postoperative pain and LOS, shorter RTNA, and lower recurrence rates. This technique is based on Stoppa's method for hernia repair which involves posterior patching of the fascial defect with a large overlap of mesh, based on Laplace's law. The large surface of the mesh allows substantial tissue in growth for permanent mesh fixation, and the intraabdominal pressure tends to hold the mesh in place against the posterior fascia. The main differences compared with the open technique are the smaller incisions and minimal soft tissue dissection needed for the placement of a large mesh overlap, which decreases the incidence of wound complications.

In a study conducted by Ujiki et al.¹⁵ The mean age of patient was 50 years In study conducted by Liang et al is 56 yrs and In study conducted by Colon et al is 53 yr.^{12,16} In present study mean age of patient is 44.67 year with a range being 18-65 years. So it shows that older age is a risk factor for ventral hernia formation due to weakness of abdominal wall. Mean size of hernia defect is 7.8 cm² in present study and in study of Liang and Lau et al defect size is 11.7 cm² and 2 cm².^{17,18}

Mean operative time of laparoscopic repair is 98.6 minute in present study thus comparable to that observed by Colon et al where mean operative time was 106 minutes and in Ujiki et al is 128 minute, which is also more compare to present study.^{15,16} In Lau et al mean operative time is 66 min which is less in compare with present study, whereas in Heniford et al it is as same as present study 97 min.^{18,19} Thus operative time of hernia repair varies considerably between surgeons also between surgical centres and reduce with experience.

Laparoscopic ventral hernia repair has less postoperative pain in present study compare with other study, as assessed by visual analogue scale at postoperative day 1, 3, 7 and postoperative month 3 and 6. No patient developed chronic pain in laparoscopic ventral hernia repair. This is comparable to study by Colon et al where pain medication required for 4.8 days and in Heniford et al pain is 1.9% at the end of 8th week.^{16,19} In most of patient in present study pain is subside within 7 days.

Mean postoperative stay for Laparoscopic repair in present study was 3.3 days as compared to other study like Ujiki et al, Heniford et al, Hussain et al is 2.1, 8, 1.6 days respectively which is comparable. In present study all wound infections are superficial.^{19,20} only one patient has post-op wound infection present 4.7% which comparably less than study of Mike et al 7.6%, Ujiki et al 5% and Colon et al 4% thus it is comparable.¹⁵⁻¹⁷

Seroma at postoperative day 7 was present in 2 patients that is 9.5% in present study compare to Mike et al, Ujiki et al, Lau et al was 20%, 13% and 7.6% respectively.^{15,16,18} Seroma was managed conservatively. At the end of 1 month seroma was absent in all patients. These seroma are result of fluid collection within hernia sac. Most of them resolve spontaneously.

During follow up of post operatively after 6 month, no one has reported hernia recurrence in present study 0% as compared to other study like to Mike et al, Ujiki et al, Heniford et al had recurrences rate 11%, 6%, and 3.4% respectively.^{15,17,18}

CONCLUSION

The laparoscopic approach appears to be safe, effective and acceptable. It is also effective in those who are obese, with co morbidities (complex) and who have recurrence from prior open repair and having ascitis. The advantages

of laparoscopic repair of umbilical and paraumbilical (ventral) hernia are: (1) smaller incisions and less scar problems; (2) broader coverage of hernia defect; (3) less postoperative hospital stay and early return to work; (4) less post-operative pain, especially late; 5) less chances of seroma formation; 6) lower incidence of mesh and wound complication; 7) better acceptable cosmetic result; 8) low incidence of recurrence. In case of multiple defects of the linea alba laparoscopy is useful in diagnosis and treatment. Laparoscopic umbilical and paraumbilical hernia repair with mesh is reasonable alternative to conventional repair for defect that requires a mesh. At issue of cost, return to work, pain free post-op period and effectiveness may establish the laparoscopic technique as the preferred mesh repair for large umbilical, paraumbilical and incisional (ventral) hernias.

ACKNOWLEDGEMENTS

I express my sincere gratitude, indebtedness and respect to Dr. G.H. Rathod, Professor and Head of Department of Surgery, B.J. Medical College and Civil Hospital, Ahmedabad. His constant encouragement and concern inspired and guided me from the very first step of preparation of this dissertation. His in depth knowledge and insight into the subject of surgery has helped me study this topic. His kindness, compassion, perfection and loving approach to the patients as well as his students have left a deep impact on my career and life. I am also thankful to Dr. R.A. Makwana, Dr. Ravi Gadani, Dr. Rajesh Patel, Department of Surgery, B.J. Medical College for their support and invaluable guidance. I am grateful to my parents who have always inspired me in every sphere of my life. Last but not the least; I am thankful to all my patients and my colleagues for their cooperation, which helped to complete my study.

Funding: No funding sources

Conflict of interest: None declared

Ethical approval: The study was approved by the Institutional Ethics Committee

REFERENCES

1. Sabiston Textbook of Surgery: The Biological Basis of Modern Surgical Practice. 19th edition. Elsevier Science Health Science; 2013: 1114-1140.
2. Maingot, Rodney, Zinner M, Stanley W. Ashley. Hernias. Maingot's Abdominal Operations. New York: McGraw-Hill Medical; 2013: 123-156.
3. Collins D. Bailey and Love's Short Practice of Surgery. 25th Ed. Williams NS, Bulstrode CJK, O'Connell PR, (eds) 283 × 225 mm. Illustrated, London: Hodder Arnold; 2008: 1514.
4. Fischer, Josef E. "Ventral Abdominal Hernia." Fischer's Mastery of Surgery. Philadelphia: Wolters Kluwer Health/Lippincott Williams & Wilkins; 2012: 2127-2142.

5. Mishra RK. Laparoscopic Repair of Ventral Hernia. Textbook of Practical Laparoscopic Surgery. 2nd ed. New Delhi: Jaypee Brothers; 2009: 227-241.
6. Palanivelu, C. Laparoscopic Repair of Ventral Hernia. Palanivelu's Textbook of Surgical Laparoscopy. 2nd ed. Coimbatore: GEM Foundation. 1-77; 205-251.
7. MacFadyen BV, Jr. Edition "Laparoscopic Surgery of the Abdomen. Part-2 Laparoscopic ventral Hernia Repair" springer New York; 2004: 282-287, 315-332.
8. Kua KB, Coleman M, Martin I, O'Rourke N. Laparoscopic repair of ventral incisional hernia. *ANZ J Surg.* 2002;72:296-9.
9. Rives J, Pire JC, Flament JB, Palot JP, Body C. Treatment of large event rations. New therapeutic indications apropos of 322 cases. *Chirurgie.* 1985;111(3):215-25.
10. Olmi S, Scaini A, Cesana GC, Erba L, Croce E. Laparoscopic versus open incisional hernia repair: an open randomized controlled study. *Surg Endosc.* 2007;21:555-9.
11. Misra MC, Bansal VK, Kulkarni MP, Pawar DK. Comparison of laparoscopic and open repair of incisional and primary ventral hernia: results of a prospective randomized study. *Surg Endosc.* 2006;20(12):1839-45.
12. García-Ureña MA, Rico P, Seoane J. Hernia umbilical del adulto. *Cirugía Española.* 1994;56:302-6.
13. Morris-Stiff GJ, Hughes LE. The outcomes of nonabsorbable mesh placed within the abdominal cavity. Literature review and clinical experience. *J Am Coll Surg.* 1998;186:352-67.
14. Mueller CB. Abdominal incisional hernia: the role of wound infection [editorial]. *Can J Surg.* 1974;17:195.
15. Ujiki MB. One hundred consecutive Laparoscopic Ventral hernia repairs. *Am J Surg.* 2004;188:593-7.
16. Colon MJ. Laparoscopic umbilical hernia repair is the preferred in obese patient. *Am J Surg.* 2013;205:231-6.
17. Liang MK, Berger RL, Li LT, Davila JA, Hicks SC, Kao LS. Outcomes of Laparoscopic vs Open repair of primary ventral Hernias. *JAMA Surg.* 2013;148:993-1080.
18. Lau H. Umbilical hernia in adults. *Surg Endosc.* 2003;17:2016-20.
19. Heniford BT, Park A, Ramshaw BJ, Voeller G. Laparoscopic Ventral and Incisional Hernia Repair in 407 patients. *J Am Coll Surg.* 2000;85:645-50.
20. Hussain A, Mahmood H, Nicholls J, El-Hasani S. Laparoscopic Ventral hernia repair.our experience 61 consecutive series. *Int J Surg.* 2008;15:19.
21. Brown RH. Comparison of infectious complication with synthetic mesh in Ventral hernia repair. *The Am J Surg.* 2013;205:182-7.
22. Purusotham B. Comparative study between Laparoscopic and open umbilical and paraumbilical hernia. *Int Surg J.* 2015;2:204-13.
23. Porecha M. Comparative study of Laparoscopic versus Open ventral hernia Repair. *Int Surg J.* 2009;22:2.
24. Thoma CE, Tatete M, Lemye B, Dessily C, Allel M. The suturing concept for laparoscopic mesh fixation in ventral and incisional hernia repair. Mid-term analysis of 400 case. *Surg Endo.* 2007;21:391-5.
25. Belli G, Agostino D, Fantini AC, Cioffi L, Belli A, Russolilo N, et al. Laparoscopic incisional and umbilical hernia repairs in cirrhotic patient. *Surg Laparosc Endosc Percutan Tech.* 2006;16(5):330-3.

Cite this article as: Patel KB, Barot MV. Laparoscopic repair of umbilical and paraumbilical hernias: a prospective and interventional study in government hospital. *Int Surg J* 2019;6:3283-8.