

## Case Report

# Phosphaturic mesenchymal tumor

**Robin George Cheereth\*, Rogers P. Augustine, Highness Tholakkara Nazar**

Department of General Surgery and Surgical Oncology, MBMM Hospital, Kothamangalam, Ernakulam, Kerala, India

**Received:** 19 May 2019

**Revised:** 20 July 2019

**Accepted:** 13 August 2019

**\*Correspondence:**

Dr. Robin George Cheereth,

E-mail: [robin.g.007@gmail.com](mailto:robin.g.007@gmail.com)

**Copyright:** © the author(s), publisher and licensee Medip Academy. This is an open-access article distributed under the terms of the Creative Commons Attribution Non-Commercial License, which permits unrestricted non-commercial use, distribution, and reproduction in any medium, provided the original work is properly cited.

### ABSTRACT

Phosphaturic mesenchymal tumors (PMTs) are very unusual tumors, commonly associated with tumor induced osteomalacia (TIO). The tumor cells produce a peptide hormone-like substance known as fibroblast growth factor 23 (FGF23), which regulates phosphate levels. When FGF23 is over expressed by the tumor cells it leads to phosphaturia, which in turn causes mobilization of calcium and phosphate from bones, and decreased osteoblastic activity, which finally leads to severe osteomalacia. Usual presentation of PMT will be gradual muscular weakness and diffuse bone pain from pathologic fractures. The majority of PMTs are benign, malignant PMTs are extremely rare, but exist. However, very rarely PMT present without phosphaturia and TIO i.e., the nonphosphaturic variant. The challenge in diagnosis of PMT is due to the vague nature of the symptoms and lack of clinical suspicion. The diagnosis is often missed due to the rarity of PMTs. The usual location for PMT involves the extremities followed by head and neck sites. We report a case of a 37 year old male who presented to the outpatient department with a swelling in the left parotid region. He had no associated symptoms. CT scan showed a well-defined heterogeneous mass measuring  $2.3 \times 2.0$  cm with calcification and soft tissue density seen superficially in the left pre auricular region. Per operatively the tumor was found to be intramuscular, embedded in the left masseter muscle. The final histopathology report was confirmative of phosphaturic mesenchymal tumor.

**Keywords:** Phosphaturic mesenchymal tumors, Tumor induced osteomalacia, Nonphosphaturic

### INTRODUCTION

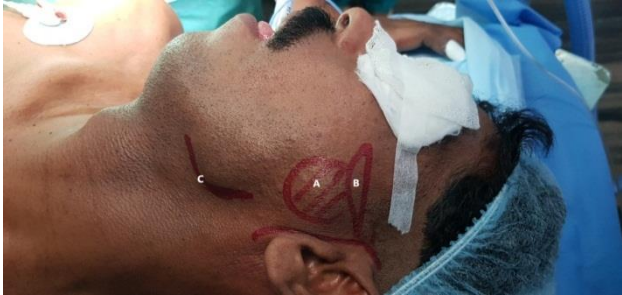Phosphaturic mesenchymal tumors (PMTs) are very unusual tumors which are commonly associated with tumor induced osteomalacia (TIO), the paraneoplastic syndrome associated with PMTs present as phosphaturia. The tumor cells produce a peptide hormone-like substance known as fibroblast growth factor 23 (FGF23), which regulates phosphate levels.<sup>1</sup> When FGF 23 is over expressed by the tumor cells, it leads to phosphaturia, mobilization of calcium and phosphate from bones, and decreased osteoblastic activity, which finally leads to extensive osteomalacia. Patients usually present with gradual muscular weakness and diffuse bone pain from pathologic fractures.<sup>2</sup> The majority of PMTs are benign, malignant PMTs are very rare, but exist.<sup>3</sup> However, rare cases of PMT present without phosphaturia and TIO i.e.,

the nonphosphaturic variant.<sup>4</sup> The diagnosis is often demanding due to the non-specific nature of the symptoms and lack of clinical suspicion. The pathologic diagnosis is often missed due to the rarity of PMTs and histological overlap with other mesenchymal neoplasms such as enchondroma and hemangiopericytoma.<sup>5,6</sup> The most common location for PMTs includes soft tissues, bones of the extremities followed by head and neck sites, with the paranasal sinuses and nasal cavity accounting for more than half of the cases in the head and neck region.<sup>7,8</sup>

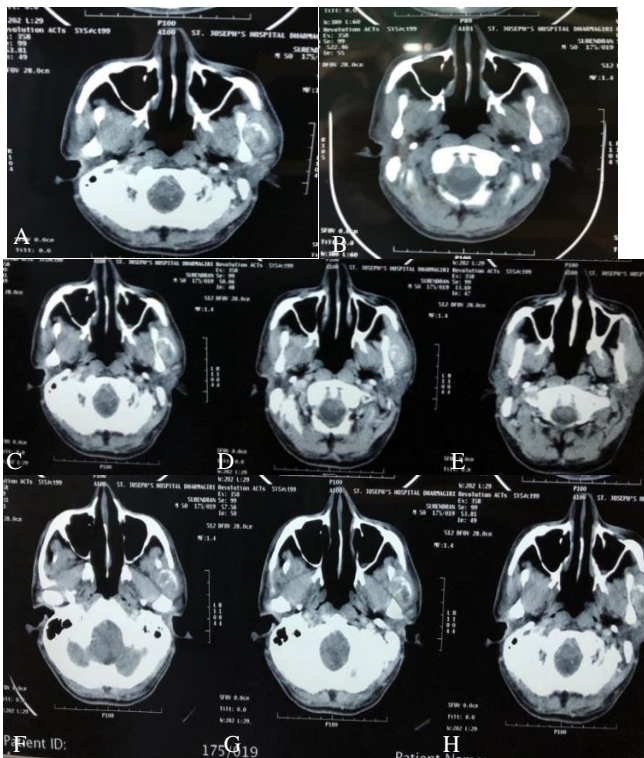
### CASE REPORT

In this article, we report the case of a 37 year old male who presented to the outpatient department with a swelling in the left parotid region. He had no associated symptoms. Clinically he was suspected to have a lesion

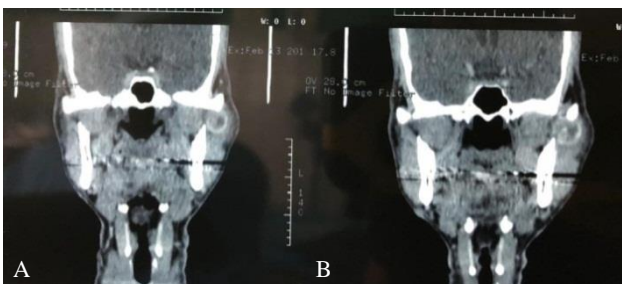
arising from the left parotid gland (Figure 1). CT scan showed a well-defined heterogeneous mass measuring  $2.3 \times 2.0$  cm with calcification and soft tissue density seen superficially in the left pre auricular region. CT was suspicious of a soft tissue tumor or lymph node (Figures 2 and 3).



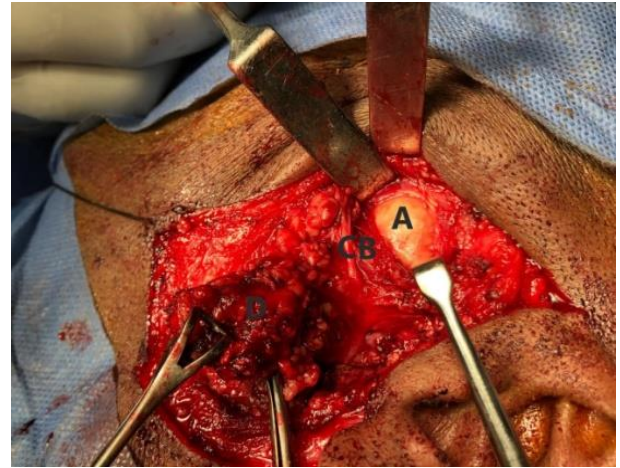
**Figure 1: (A) Lesion, (B) zygoma, (C) angle of mandible.**



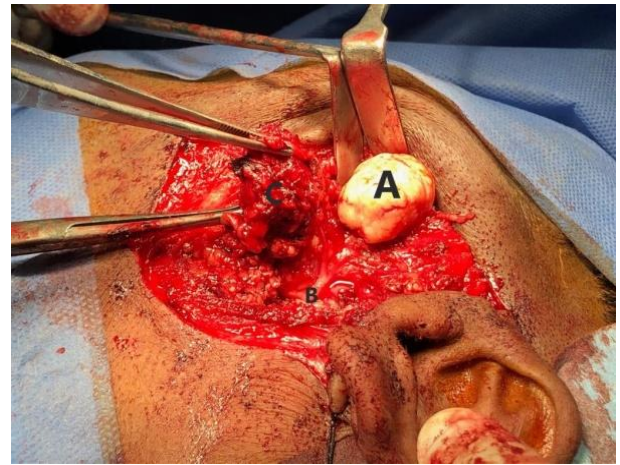
**Figure 1 (A-H): CT head axial view showing lesion.**



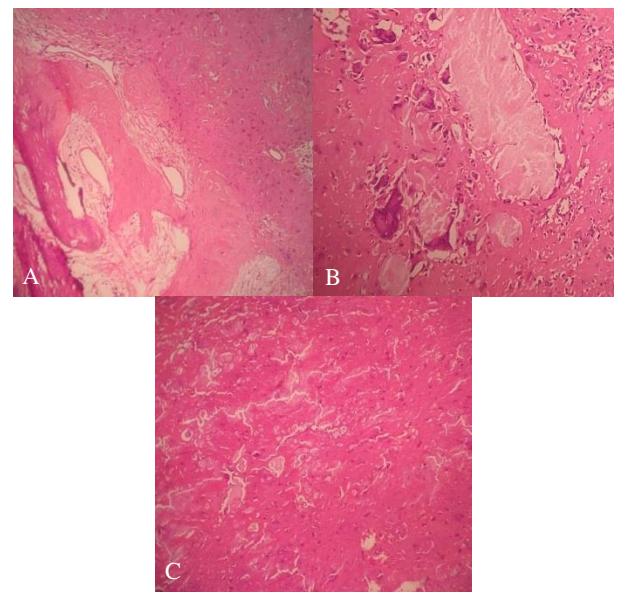
**Figure 3 (A and B): CT head coronal view, lesion in left zygomatic region**



**Figure 2: (A) Lesion, (B) masseter muscle, (C) branch of facial nerve, (D) parotid gland.**



**Figure 3: (A) Lesion, (B) facial nerve, (C) parotid gland.**



**Figure 6 (A-C): Histopathological pictures of PMT.**



A left sistrunk incision was placed. Per operatively the tumor was found to be intramuscular and deep to the superficial lobe of parotid gland, embedded in the left masseter muscle. To minimize the injury to facial nerve we proceeded with a left superficial parotidectomy. A 2 × 2 cm white firm lesion was excised out by splitting the left masseter muscle (Figures 4 and 5). The lesion was sent for histopathology examination. Postoperatively patient had neuropraxia of the orbital branch. Histopathology showed hyalinised tissue with scattered blood vessels, foreign body giant cell, lymphoid nodule and focal areas of osseous metaplasia which was suggestive of PMT (Figures 6 A, B and C). After a diagnosis of PMT was made serum phosphorus, alkaline phosphatase and Vit D3 was done on follow up. Serum phosphorus and alkaline phosphatase was normal. Serum VitD3 was low, hence VitD3 supplementation was given.

## DISCUSSION

PMTs are rare neoplasm associated with tumor induced osteomalacia and is often under recognized by clinician and pathologist.<sup>4</sup> This problem is aggravated by the fact that several variants of PMTs exist to date no consistent or defining histopathological and immune-phenotype has been established.<sup>5</sup> This can be reemphasized in the series by Folpe et al, even after expert review five cases remain unclassified as PMTs.<sup>9</sup>

The paraneoplastic syndrome associated with PMTs manifest as phosphaturia. The tumor cells produce a peptide hormone-like substance known as fibroblast growth factor 23 (FGF23), a physiologic regulator of phosphate levels. Over expression of FGF23 by the tumor cells leads to phosphaturia, mobilization of calcium and phosphate from bones, and the lessening of osteoblastic activity, eventually resulting in extensive osteomalacia. Patients normally present with gradual muscular weakness and diffuse bone pain from pathologic fractures.<sup>10</sup> The majority of PMTs are benign, malignant PMTs are exceedingly rare, but exist.<sup>11</sup> PMTs without phosphaturia i.e., non phosphaturic variant are even rarer. The non phosphaturic variant is even harder to diagnose for its lack of symptoms because symptoms of osteomalacia more or less always precedes the clinical presentation of PMTs.<sup>12</sup>

Phosphaturic mesenchymal tumors are of the mixed epithelial, connective tissue type and mixed connective tissue type [MCT], of which MCT is the most common one.<sup>5,6</sup> Histopathologically, fibrous capsule, calcification and giant cell reaction is observed in soft-tissue PMT-MCT, while PMT-MCT of bone and multiple PMT-MCT showed an infiltrative growth pattern. Non-phosphaturic PMT also shows histopathological features of mixed connective tissue type.<sup>13-15</sup>

The most common location for PMT involves soft tissues, bones of the extremities followed by head and neck sites. Roughly 95% of PMTs is seen in the

extremities and appendicular skeleton, only 5% of the tumor is found in the head and neck region. Localization in the head and neck is very rare, with the paranasal sinuses and nasal cavity representing more than half of the cases.<sup>7,8,16</sup>

Regrettably, preoperative phosphate and serum FGF23 levels are not available for patients with “non-phosphaturic” variant of PMT so far. There have been incidence wherein clinically noteworthy osteomalacia was diagnosed only after the biopsy analysis of PMT was done, emphasizing for the pathologist the significance of identifying the histopathological features of this tumor, even when a history of TIO is not given.<sup>12</sup> Many other benign mesenchymal tumor types have been associated with TIO, such as enchondroma and hemangiopericytoma.<sup>10</sup> However, majority of the reports reviewed has shown that PMTs are misdiagnosed, due to the uncommonness of these tumors and lack of acquaintance and experience of the pathologists with their histopathological features.

Even though PMTs are rare tumors and even if there is no clinical symptoms of Osteomalacia it should be considered as differential diagnosis for tumors in head and neck region.

*Funding: No funding sources*

*Conflict of interest: None declared*

*Ethical approval: Not required*

## REFERENCES

1. Pal R, Bhadada SK, Shingare A, Bhansali A, Kamalanathan S, Chadha M, et al. Tumor-induced osteomalacia: experience from three tertiary care centres in India. *Endocr Connect*. 2019;pii:EC-18-0552.R1.
2. Zuo QY, Wang H, Li W, Niu XH, Huang YH, Chen J, et al. Treatment and outcomes of tumor-induced osteomalacia associated with phosphaturic mesenchymal tumors: retrospective review of 12 patients. *BMC Musculoskelet Disord*. 2017;18(1):403.
3. Yavropoulou MP, Poullos C, Foroulis C, Tournis S, Hytioglou P, Kotsa K, et al. Distant lung metastases caused by a histologically benign phosphaturic mesenchymal tumor. *Endocrinol Diabetes Metab Case Rep*. 2018;2018:18-23.
4. Sent-Doux KN, Mackinnon C, Lee JC, Folpe AL, Habeeb O. Phosphaturic mesenchymal tumor without osteomalacia: additional confirmation of the “nonphosphaturic” variant, with emphasis on the roles of FGF23 chromogenic in situ hybridization and FN1-FGFR1 fluorescence in situ hybridization. *Hum Pathol*. 2018;80:94-8.
5. Agaimy A, Michal M, Chiosea S, Petersson F, Hadravsky L, Kristiansen G, et al. Phosphaturic Mesenchymal Tumors Clinicopathologic, Immunohistochemical and Molecular Analysis of 22 Cases

- Expanding their Morphologic and Immunophenotypic Spectrum. *Am J Surg Pathol.* 2017;41(10):1371-80.
6. Wu H, Bui MM, Zhou L, Li D, Zhang H, Zhong D. Phosphaturic mesenchymal tumor with an admixture of epithelial and mesenchymal elements in the jaws: clinicopathological and immunohistochemical analysis of 22 cases with literature review. *Mod Pathol.* 2019;32(2):189-204.
7. Qari H, Hamao-Sakamoto A, Fuselier C, Cheng YS, Kessler H, Wright J. Phosphaturic Mesenchymal Tumor: 2 New Oral Cases and Review of 53 Cases in the Head and Neck. *Head and Neck Pathol.* 2016;10:192–200.
8. Pelo S, Gasparini G, Garagiola U, D'Amato G, Saponaro G, Doneddu P, et al. Phosphaturic mesenchymal tumor, an unusual localization in head and neck. *J Surg Case Rep.* 2018;2018(5):rjy091.
9. Folpe AL, Fanburg-Smith JC, Billings SD, Bisceglia M, Bertonni F, Cho JY, et al. Most Osteomalacia-associated Mesenchymal Tumors Are a Single Histopathologic Entity: An Analysis of 32 Cases and a Comprehensive Review of the Literature *Am J Surg Pathol.* 2004;28(1):1-30.
10. Ghorbani-Aghbolaghia A, Darrova MA, Wanga T. Phosphaturic mesenchymal tumor (PMT): exceptionally rare disease, yet crucial not to miss. *Autops Case Rep (São Paulo).* 2017;7(3):32-7.
11. Qiu S, Cao LL, Qiu Y, Yan P, Li Z, Du J, et al. Malignant phosphaturic mesenchymal tumor with pulmonary metastasis. *Medicine.* 2017;96:17(e6750).
12. Boland JM, Tebben PJ, Folpe AL. Phosphaturic mesenchymal tumors: what an endocrinologist should know? *J Endocrinol Invest.* 2018;41(10):1173-84.
13. Honda R, Kawabata Y, Ito S, Kikuchi F. Phosphaturic mesenchymal tumor, mixed connective tissue type, non-phosphaturic variant: Report of a case and review of 32 cases from the Japanese published work. *J Dermatol.* 2014;41:845–9.
14. Yamada Y, Kinoshita I, Kenichi K, Yamamoto H, Iwasaki T, Otsuka H, et al. Histopathological and Genetic Review of Phosphaturic Mesenchymal Tumours, Mixed Connective Tissue Variant. *Histopathology.* 2018;72(3):460-71.
15. William J, Laskin W, Nayar R, De Frias D. Diagnosis of Phosphaturic Mesenchymal Tumor (Mixed Connective Tissue Type) by Cytopathology. *Diagn Cytopathol.* 2012;40 Suppl 2:E109-13.
16. Woo VL, Landesberg R, Imel EA, Singer SR, Folpe AL, Econs MJ, et al. Phosphaturic mesenchymal tumor, mixed connective tissue variant, of the mandible: report of a case and review of the literature. *Oral Surg Oral Med Oral Pathol Oral Radiol Endod.* 2009;108(6):925-32.
17. Kobayashi H, Makise N, Ushiku T, Nobuaki Ito, Koga M, Shinoda Y, et al. Infiltrative nature of tumor-induced osteomalacia lesions in bone: Correlation between radiological and histopathological features. *J Orthop Sci.* 2019;pii:S0949-2658(19):30053-3.
18. Shi Z, Deng Y, Li X, Li Y, Cao D, Coossa VS. CT and MR imaging features in phosphaturic mesenchymal tumor-mixed connective tissue: A case report. *Oncol Lett.* 2018;15(4):4970-8.
19. Broski SM, Wenger DE, Folpe AL. Imaging features of phosphaturic mesenchymal tumors. *Skeletal Radiol.* 2019;48(1):119-27.
20. Lee JY, Park HS, Han S, Lim JK, Hong N, Park S, et al. Localization of Oncogenic Osteomalacia by Systemic Venous Sampling of Fibroblast Growth Factor 23. *Yonsei Med J.* 2017;58(5):981-7.
21. Xiao X, Sun X, Ni P, Huang Y, Xie T. Phosphaturic mesenchymal tumor and related wound problem. *Medicine (Baltimore).* 2018;97(40):e12507.
22. Walsh EM, Jacob J, Walsh EM, Jacob J, Lucas DR, Sargent EW. Phosphaturic Mesenchymal Tumor of the Cerebellopontine Angle. *JAMA Otolaryngol Head Neck Surg.* 2019;145(3):287-8.
23. Wasserman JK, Purgina B, Lai CK, Gravel D, Mahaffey A, Bell D, et al. Phosphaturic Mesenchymal Tumor Involving the Head and Neck: A Report of Five Cases with FGFR1 Fluorescence In Situ Hybridization Analysis. *Head Neck Pathol.* 2016;10(3):279-85.
24. Wang X, Gao J, Han S, Li Y. Spinal phosphaturic mesenchymal tumors: Case report and literature review. *J Clin Neurosci.* 2019;63:234-9.
25. Kurien R, Rupa V, Thomas M. Varied presentation of sinonasal phosphaturic mesenchymal tumor: report of a case series with follow-up. *Eur Arch Otorhinolaryngol.* 2019;276(6):1677-84.

**Cite this article as:** Cheereth RC, Augustine RP, Nazar HT. Phosphaturic mesenchymal tumor. *Int Surg J* 2019;6:3393-6.