

## Case Report

# Post traumatic hepatic artery pseudoaneurysm: a tertiary care centre experience

Prasanna Gopal<sup>1</sup>, Shankar Subbarayan<sup>1</sup>, Karthikeyan Mohan<sup>1</sup>, Amudhan Anbalagan<sup>1</sup>,  
Kalpana S.<sup>2</sup>, Rajendran Shanmugasundaram<sup>1</sup>, Naganath Babu Obla Lakshmana Moorthy<sup>1\*</sup>

<sup>1</sup>Institute of Surgical Gastroenterology, <sup>2</sup>Barnard Institute of Radiology, Madras Medical College, RGGGH, Chennai, Tamil Nadu, India

**Received:** 27 May 2019

**Revised:** 04 August 2019

**Accepted:** 06 August 2019

### \*Correspondence:

Dr. Naganath Babu Obla Lakshmana Moorthy,  
E-mail: [naganathbabu@gmail.com](mailto:naganathbabu@gmail.com)

**Copyright:** © the author(s), publisher and licensee Medip Academy. This is an open-access article distributed under the terms of the Creative Commons Attribution Non-Commercial License, which permits unrestricted non-commercial use, distribution, and reproduction in any medium, provided the original work is properly cited.

## ABSTRACT

In blunt trauma abdomen, liver is the most commonly injured organ after spleen. Management of blunt hepatic injury has shifted from operative to non-operative management NOM in hemodynamically stable patients. Main cause of failure of NOM is hemodynamic instability due to re-bleeding or secondary hemorrhage due to rupture of capsular hematoma. Post traumatic hepatic artery pseudoaneurysm HAP as a cause of failure of NOM is rare, reported in about 1.2%. HAP requires early intervention by angiographic embolisation or surgery to prevent catastrophic event. Here, we report our experience with four cases of HAP managed in our centre in past three years. Three patients were managed by selective angioembolisation and one patient was treated by surgery. All patients had uneventful recovery and are asymptomatic on follow-up. HAP is a rare life threatening complication which can present even after successful NOM as a delayed presentation. All symptomatic pseudoaneurysm has to be managed by angioembolisation or surgery depending on hemodynamic stability.

**Keywords:** Trauma, Liver, Pseudoaneurysm, Embolisation

## INTRODUCTION

In blunt trauma abdomen, liver is the most commonly injured organ after spleen. Management of blunt hepatic injury has shifted from operative to non-operative management (NOM) in hemodynamically stable patients. Main cause of failure of NOM is hemodynamic instability due to re-bleeding or secondary hemorrhage due to rupture of capsular hematoma. Post traumatic hepatic artery pseudoaneurysm HAP as a cause of failure of NOM is rare, reported in about 1.2%. Recognition and management of this rare pseudoaneurysm is important to prevent a life threatening event.<sup>1,2</sup> The objective of this retrospective study is to study the mode of presentation and treatment options in patients with HAPs.

## CASE REPORT

During 2016 to 2018, four patients were treated for HAPs in our Institute. Data were obtained from Institutional database register. Patient's data including demographic profile, mode of injury, clinical presentation, imaging findings and management outcomes were analysed. Of the four patients with HAP, one patient was managed by NOM in our Institute and three patients were referred to our Institute for management of HAP.

For NOM, our protocol is to manage patients in ICU with vitals monitoring, hemoglobin monitoring every 6 hours. CT scans are indicated for patients who develop sudden hypotension, tachycardia, with sudden Hb fall or fever.

For other patients who develop symptoms of HAP, we do UGI endoscopy and CT angiography.

Treatment depends on hemodynamic stability. For hemodynamically stable patients we prefer angio-embolisation, whereas for unstable patients, surgery is preferred (Figure 1).

All 4 patients who were treated for HAP were males. Mean age was 24.5 years (range: 18-34 years). All cases

presented after blunt abdominal trauma in road traffic accident RTA. Melena was the most common presenting complaint, followed by abdominal pain. No patient had jaundice. One patient developed pseudoaneurysm during hospital stay itself on day 9 of NOM, other patient presented 8 days after surgery for hemodynamic instability. Mean number of days from presentation to injury is 13.5 days (range: 7-30 days). Upper GI scopy revealed blood in one patient. CT angiography correctly identified HAP in all patients.

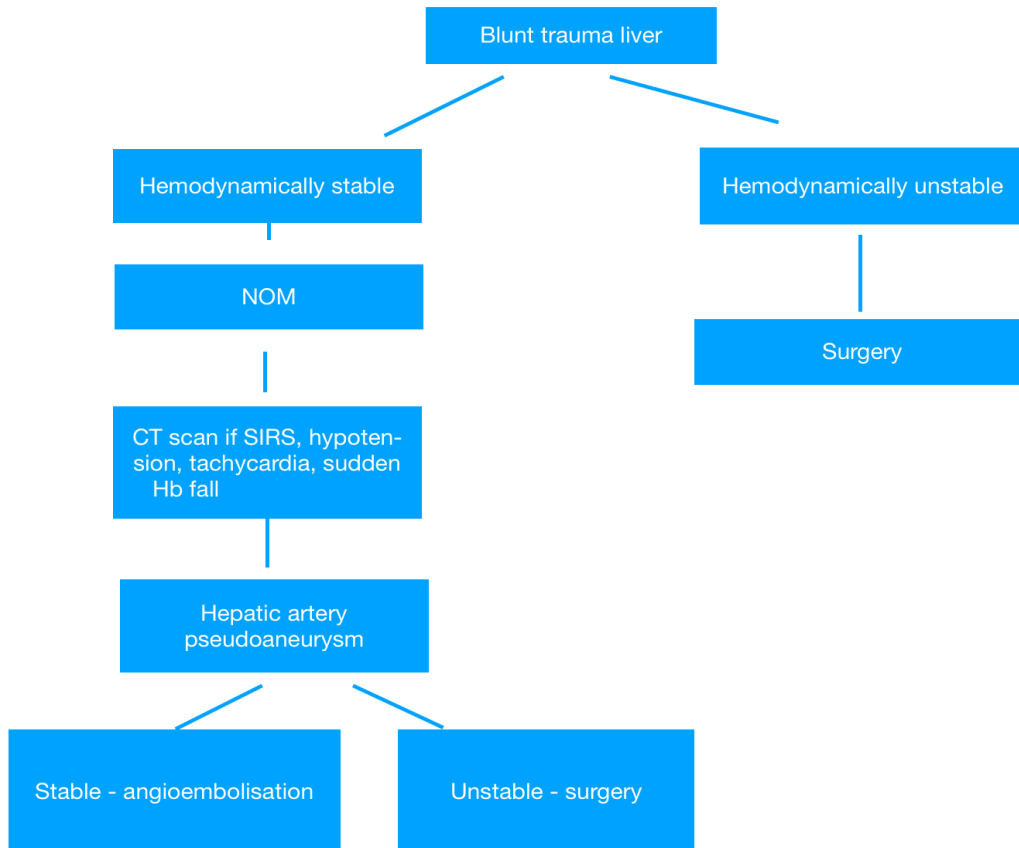


Figure 1: Algorithm for management of hepatic trauma.

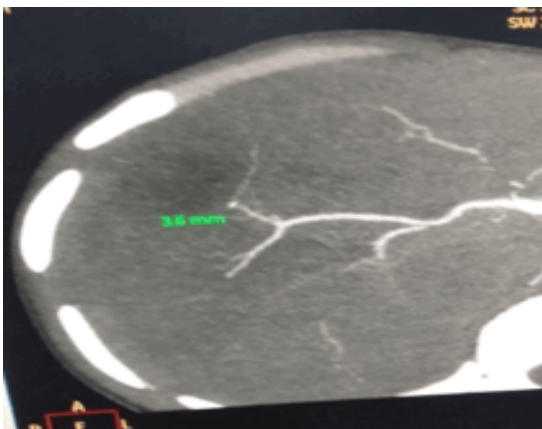


Figure 2: HAP in anterior branch of right hepatic artery.

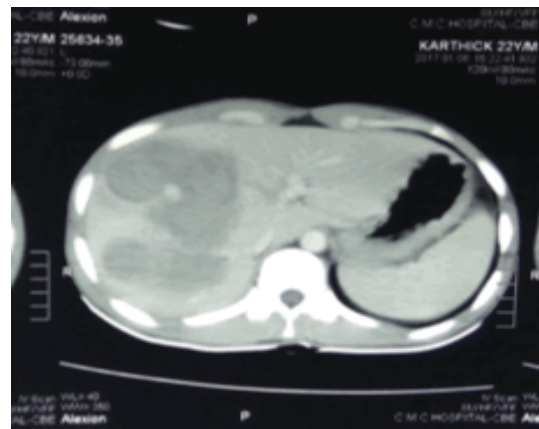
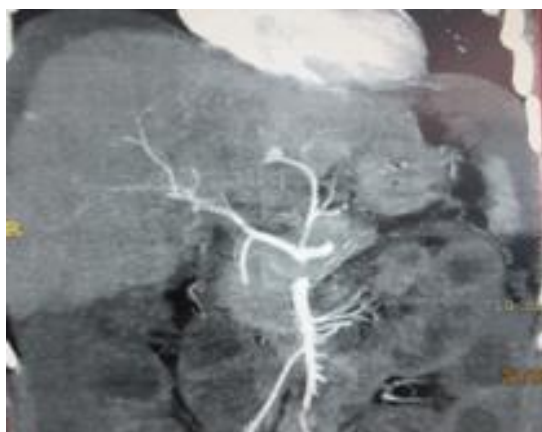

Figure 3: HAP within hematoma in segment 8, arising from right hepatic artery.



**Figure 4: HAP in replaced left hepatic artery.**

Two patients had HAP from right hepatic artery (Figures 2 and 3), one patient had HAP in anterior branch of right Hepatic Artery and the other patient had HAP in replaced

left hepatic artery arising from left gastric artery (Figure 4) (Michel's type 2).<sup>3</sup> Size of pseudoaneurysm ranges from 3.6 mm to 12 mm (mean 8.4 mm). Three patients were hemodynamically stable, who underwent angioembolisation and one patient was hemodynamically unstable, underwent surgery.

Angioembolisation was done by right femoral approach using seldinger method and bleeding vessel embolised using coils in all three cases. In one patient, who presented with hemodynamic instability, emergency laparotomy was done and left Hepatic artery which was arising from left gastric artery was ligated. Post procedure, all patients were managed in ICU. There were no rebleeding, no mortality. Post procedure LFT returned to normal levels within a week. Follow up scans were taken 1-2 months after discharge from hospital. Two patients had atrophy of corresponding liver lobe without any complications (Table 1).

**Table 1: Clinical features, imaging findings, managements and outcomes of 4 cases of HAP.**

	Case 1	Case 2	Case 3	Case 4
<b>Age (years)</b>	22	24	18	34
<b>Grade of liver injury</b>	Grade 4	Grade 3	Grade 4	Grade 3
<b>Day of presentation</b>	30 days	9 days	8 days	7 days
<b>Mode of Presentation</b>	Melena and abdominal pain	Fall in Hb level with hypotension and tachycardia	Melena	Post Laparotomy status, Blood in PCD
<b>CT abdominal angiogram</b>	Aneurysm in anterior branch of right hepatic artery 3.6 mm	Aneurysm in left hepatic artery which in turn arises from left gastric artery, 10 mm	Aneurysm arising from the right hepatic artery, 8 mm	Aneurysm in right Hepatic artery, 12 mm
<b>Management</b>	Angioembolisation of pseudoaneurysm	Emergency laparotomy and ligation of left gastric artery	Angioembolisation of pseudoaneurysm	Angioembolisation of pseudoaneurysm
<b>Post procedure</b>	Uneventful	Uneventful	Uneventful	Uneventful
<b>Follow up</b>	Till 6 months no recurrence	Till 6 months no recurrence	Till 4 months no recurrence	Till 2 months no recurrence

## DISCUSSION

Liver is the most common injured organ in abdominal trauma after spleen.

Management of hemodynamically stable patients with hepatic injury after blunt trauma has shifted from operative to non-operative management (NOM) in past three decades, with high success rates 82-100%. As more number of patients are being treated by NOM, we observe complications following NOM. Bleeding is the most common cause of NOM failure.<sup>4</sup>

Bleeding occurs due to rupture of capsular hematoma or due to pseudoaneurysm. Bleeding due to post traumatic Hepatic artery pseudoaneurysm is very rare with incidence ranging from 1.2-4%.<sup>5</sup>

In our series, the incidence is slightly higher, 8.3% probably due to referral bias. Our centre is tertiary referral centre for management of complex hepatobiliary problems in our state.

Of the four patients who were treated, one had NOM failure during hospital stay itself and other three had delayed presentation, presenting upto one year after injury. In literature, it has been found that HAP can even present one year after trauma as reported by Behnam sanei et al.<sup>5,6</sup>

Mode of presentation is melena in two patients, abdominal pain in one patient, hemodynamic instability in one patient and blood in percutaneous drain placed for bilioma in one patient. Pseudoaneurysm rupturing into biliary tree causing classical triad of hemobilia

(Quincke's triad) consisting of Abdominal pain, upper GI bleed and jaundice is not observed in our patients.<sup>7</sup>

Upper GI endoscopy is done in stable patients to look for evidence of bleeding in upper GI tract. Patients who have bleeding into the biliary tree can have fresh blood flowing out of ampulla or fresh bleeding into the duodenum. Upper GI endoscopy may also rule out other common causes of bleeding such as erosive gastritis, peptic ulcers, and esophageal and gastric varices. We did UGI endoscopy in three patients, all were normal.

Contrast enhanced computed tomography CECT abdomen is the investigation of choice for patients suspected to have hepatic artery pseudoaneurysm. Some authors advocate routine follow up CT scan between 7-10 days for patients on NOM, whereas others suggest CT scan only if there is persistent SIRS, unexplained drop in hemoglobin level, abdominal pain, and jaundice. In our institute CT scans are taken only if clinically warranted. One patient who was treated with NOM, developed sudden drop in hemoglobin, on CT scan it was found to have HAP arising from replaced left hepatic artery.<sup>8</sup>

Since there are only very few cases of pseudoaneurysm reported so far, the natural course of patients with HAP is not fully known. Considering high risk of rupture, all HAPs were treated by interventional radiology or surgery. Some authors describe conservative management for pseudoaneurysm <10 mm and take repeat imaging after 3-7 days, if Pseudoaneurysm remained without enlargement they were not embolised. In this study it was found that incidentally detected pseudoaneurysm which is less than 10 mm had spontaneous disappearance when followed up. In another case report by upendar shava et al, a symptomatic pseudoaneurysm of size 13 mm was managed without any intervention. In our series, all patients had symptomatic pseudoaneurysm, so all underwent intervention.<sup>9,10</sup>

Endovascular coil embolisation and percutaneous thrombin injection is also included in the armamentarium for management of patients with liver trauma by NOM and it significantly increases success rates with NOM. Angiography and embolisation is advised in patients showing blush on CT scan.<sup>11</sup>

In our series, we did angioembolisation for three cases with 100% success rate. Angioembolisation is safe and effective without any major complications. Since the major vascular supply to the liver is from the portal system, hepatic artery occlusion is unlikely to cause any significant hepatic ischemia. LFT levels return need to normal within a week. No post procedure hepatic ischemia or necrosis was noted in our study. Percutaneous thrombin injection can also be tried, when pseudoaneurysm is present at site inaccessible by angiography.<sup>12</sup>

Surgical treatment is indicated for patients with hemodynamic instability and failed embolisation. Surgery involves ligation of the offending hepatic artery. When bleeding continues even after ligating hepatic artery, hepatectomy may be warranted to control bleeding. In present study, one patient who had HAP in replaced left Hepatic artery with hemodynamic instability underwent surgical ligation of replaced left Hepatic artery, which controlled bleeding.<sup>13,14</sup>

In our series of patients with post traumatic HAP, we had 100% success rate by angioembolisation and surgery.

## CONCLUSION

Hepatic artery pseudoaneurysm is a rare life threatening complication following blunt trauma abdomen which can even present late after trauma. High index of suspicion and thorough radiological investigation is necessary. Routine follow-up CT is not necessary for all patients on NOM. All symptomatic pseudoaneurysm should undergo intervention. Angioembolisation should be used as first choice in stable patients, whereas surgery is reserved for patients who are hemodynamically unstable or had failed embolization.

*Funding: No funding sources*

*Conflict of interest: None declared*

*Ethical approval: Not required*

## REFERENCES

1. Piper GL, Peitzman AB. Current management of hepatic trauma. *Surgical Clinics*. 2010;90(4):775-85.
2. Malhotra AK, Fabian TC, Croce MA, Gavin TJ, Kudsk KA, Minard G, et al. Blunt hepatic injury: a paradigm shift from operative to non-operative management in the 1990's. *Ann Surg*. 2000;231:804Y813.
3. Michels NA. Blood supply and anatomy of the upper abdominal organs with a descriptive atlas. Philadelphia (Pa). 1955;7.
4. Coccolini F, Catena F, Moore EE, Ivatury R, Biffl W, Peitzman A, et al. WSES classification and guidelines for liver trauma. *World J Emerg Surg*. 2016;11(1):50.
5. Sanei B, Kolahdouzan M, Jafari HR. Intrahepatic Artery Pseudoaneurysm as a Delayed Presentation of Blunt Abdominal Trauma. *Archives Trauma Res*. 2017;6(2).
6. Batur A, Yavuz A, Toktas O, Bora A, Bulut MD. Hepatic artery pseudoaneurysm: delayed presentation after a blunt trauma. *Polish J Radiol*. 2015;80:334.
7. Croce MA, Fabian TC, Spiers JP, Kudsk KA. Traumatic hepatic artery pseudoaneurysm with hemobilia. *Am J Surg*. 1994;168(3):235-8.
8. Østerballe L, Helgstrand F, Axelsen T, Hillingsø J, Svendsen LB. Hepatic pseudoaneurysm after

- traumatic liver injury; is CT follow-up warranted? *J Trauma Manag Outcomes.* 2014;8(1):18.
9. Kittaka H, Yagi Y, Zushi R, Hazui H, Akimoto H. The investigation of posttraumatic pseudoaneurysms in patients treated with nonoperative management for blunt abdominal solid organ injuries. *PloS one.* 2015;10(3):e0121078.
  10. Shava U, Poddar U, Yachha SK, Kumar S, Lal R, Srivastava A. Post-traumatic hepatic pseudoaneurysm: is intervention a must in all cases? *Tropical Gastroenterol.* 2017;37(1):72-5.
  11. Misselbeck TS, Teicher EJ, Cipolle MD, Pasquale MD, Shah KT, Dangleben DA, et al. Hepatic angioembolization in trauma patients: indications and complications. *J Trauma Acute Care Surg.* 2009;67(4):769-73.
  12. Dambrin C, Marcheix B, Birsan T, Cron C, Muscari F, Suc B, et al. Posttraumatic pseudoaneurysm of the hepatic artery: treatment with ultrasound-guided percutaneous transhepatic thrombin injection. *J Trauma Acute Care Surg.* 2005;59(1):239-42.
  13. Patel MS, Shetty V, Shelake A, Deshpande AA. Early presentation of ruptured post-traumatic hepatic artery pseudoaneurysm. *J Postgraduate Med.* 2018;64(4):250.
  14. Ghariani MZ, Georg Y, Ramirez C, Lebied E, Gaudric J, Chiche L, et al. Long-term results of surgical treatment of aneurysms of digestive arteries. *Ann Vasc Surg.* 2013;27:954-8.

**Cite this article as:** Gopal P, Subbarayan S, Mohan K, Anbalagan A, Kalpana S, Shanmugasundaram R, Moorthy NBOL. Post traumatic hepatic artery pseudoaneurysm: a tertiary care centre experience. *Int Surg J* 2019;6:3438-42.