

Case Report

Bilateral breasts metastases from gall bladder adenocarcinoma: a rare presentation

Vaibhav R. Gopal^{1*}, Shailendra K. Yadav¹, Faraz Ahmad¹,
Surender Kumar¹, Saumya Shukla², Mithlesh Bhargav³

¹Department of Surgery, Surgery, King George's Medical University, Lucknow, Uttar Pradesh, India

²Department of Pathology, Ram Manohar Lohia Institute of Medical Sciences, ³Sanjay Gandhi Post Graduate Institute of Medical Sciences, Lucknow, Uttar Pradesh, India

Received: 17 May 2019

Accepted: 29 June 2019

*Correspondence:

Dr. Vaibhav R. Gopal,

E-mail: twinklke1@gmail.com

Copyright: © the author(s), publisher and licensee Medip Academy. This is an open-access article distributed under the terms of the Creative Commons Attribution Non-Commercial License, which permits unrestricted non-commercial use, distribution, and reproduction in any medium, provided the original work is properly cited.

ABSTRACT

Bilateral breasts metastasis from gallbladder adenocarcinoma is very rare and has never been reported. Overall incidence of breast metastasis from other primaries as reported in literature is 0.5-3%. A 38 year female presented with progressive abdominal distension followed by lumps in the left and right breasts consecutively. Abdominal examination revealed a huge right upper quadrant lump, hard in consistency and moving with respiration. CT abdomen suggested gallbladder lump infiltrating liver, colon, duodenum and pylorus. HRUSG of breasts revealed malignant lumps. Histopathology and immuno-histochemistry of breast biopsy confirmed it to be metastatic and not the primary (mammaglobin-, GATA 3 -, CK 19+, GCDFP-). Gallbladder biopsy showed adenocarcinoma with similar marker pattern. A diagnosis of gallbladder carcinoma with secondaries in bilateral breasts was made. Patient received one cycle of platinum based palliative chemotherapy and thereafter was lost to follow up. A proper clinical, radiological and histopathological examination is essential to distinguish primary and metastatic breast lesion due to the difference in the management of both. Overall prognosis is very poor and treatment should be directed towards palliative therapy of primary malignancy.

Keywords: Breast lump, Gallbladder cancer, Inflammatory breast cancer

INTRODUCTION

Gallbladder cancer is a highly aggressive disease with poor survival. Its spread to the adjoining structures and extra-abdominal organs such as the lung and brain is well established. Breast metastasis is very unusual in gallbladder cancer. Here we report a case of bilateral breasts metastases in a patient of gallbladder cancer. There are many reports of secondaries to the gall bladder from the breast primary but only single case of gall bladder cancer metastasis to unilateral breast has been described till date.¹⁻³ Hence our case will be the first to be reported having bilateral breasts metastases from gall bladder primary.

CASE REPORT

A 38 year old female presented in the OPD with complains of slowly progressive painless lump in the left breast followed by the right 10 days later, for 1 month. She also had off and on pain in the abdomen with progressive distension for one month. There was loss of appetite and weight. No other significant complains were elicited. Menstrual history was normal.

On examination, she had a left and right breast lumps of approximately 5×5 cm and 4×4 cm respectively both in upper inner quadrant. Both were hard in consistency and fixed to skin. A satellite nodule of 2×2 cm was identified

in the upper outer quadrant of left breast with similar consistency. Bilateral axillae were within normal limits. Further she had a huge abdominal lump with well-defined margins and hard consistency in right upper quadrant (Figure 1). It was moving well with respiration. Shifting dullness was present.

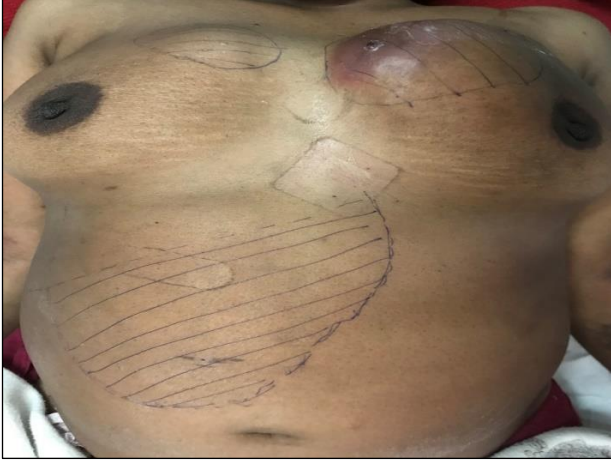

Figure 1: Bilateral breasts lumps with huge abdominal lump.

Investigations

128 slice contrast enhanced CT abdomen revealed 10*8*10 cm mass in gall bladder fossa infiltrating segment 4 and 5 of liver with abutment of pylorus and infiltration of duodenum and hepatic flexure (Figure 2).

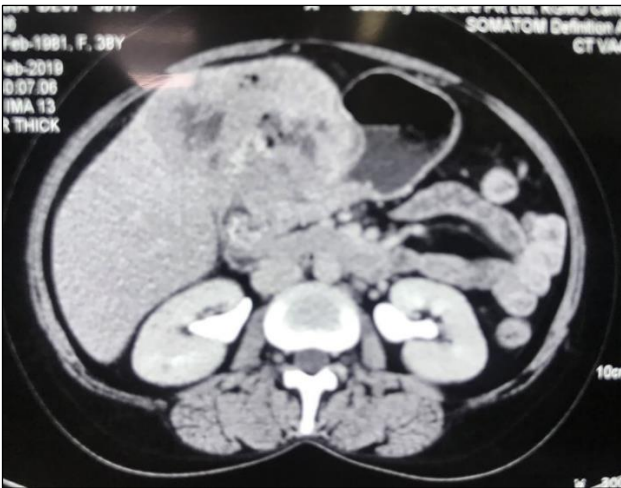

Figure 2: Gallbladder fossa mass infiltrating liver, duodenum and pylorus.

HR-USG of bilateral breasts showed hetero-echoic lesion of 6.5×6 cms in left breast infiltrating the muscle plane (BIRADS V category) and multiple hetero-echoic lesions in right breast largest measuring 4.2×2.4 cms (BIRADS IV A). Biopsy from bilateral breast lump revealed metastatic adenocarcinoma with immunohistochemistry

favouring gallbladder adenocarcinoma. (CK- 19+, GATA 3-, GCDFP-, Mammaglobin-) (Figure 3-7).

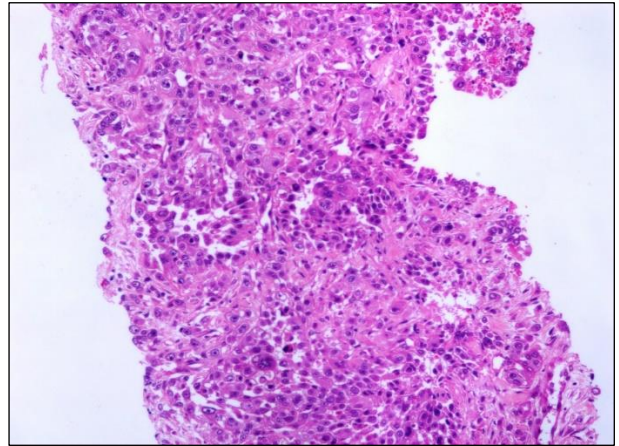


Figure 3: Histopathology of breast lump showing metastatic adenocarcinoma (H&E stain, 10X view).

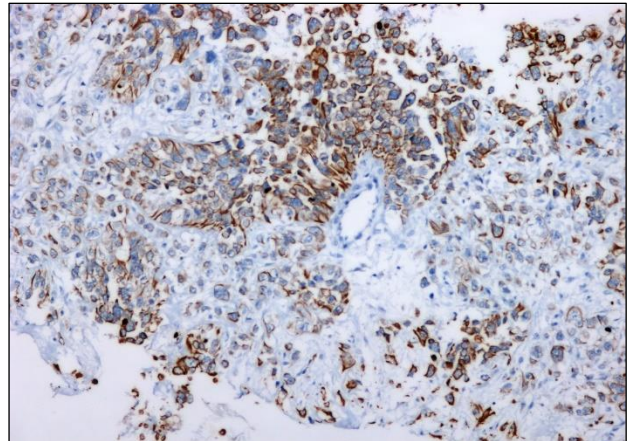


Figure 4: Immunohistochemistry depicting CK-19 positivity in breast tissue biopsy.

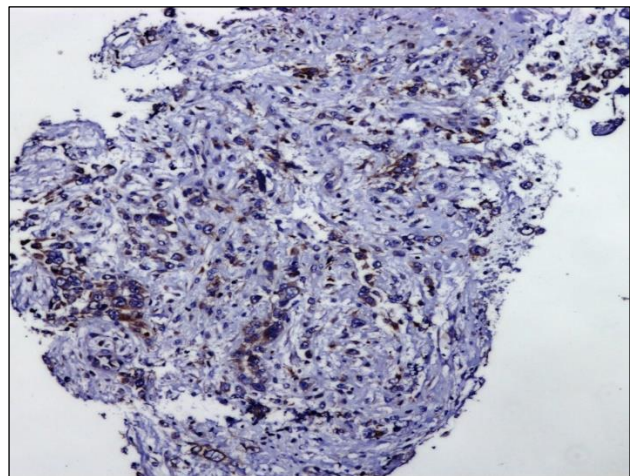


Figure 5: Breast tissue biopsy with negative immunostaining for GATA-3.

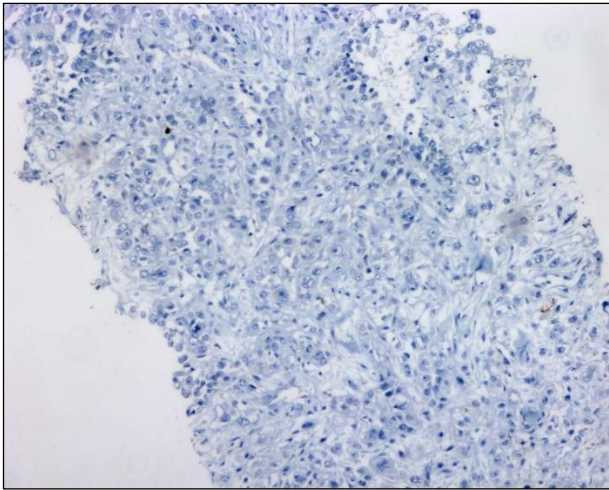


Figure 6: Breast tissue biopsy with negative immunostaining for GCDFP.

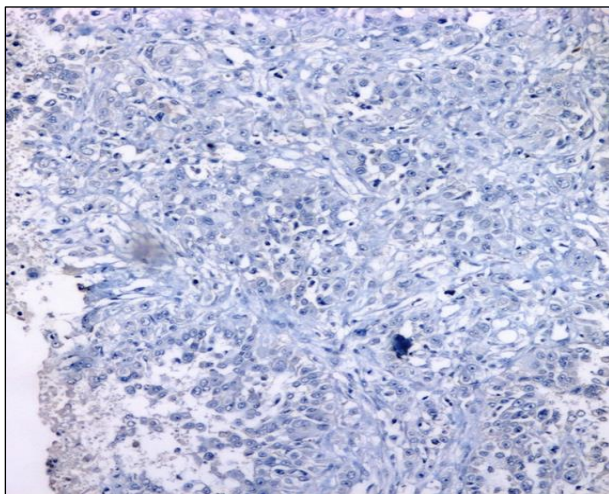


Figure 7: Breast tissue biopsy with negative immunostaining for mammaglobin.

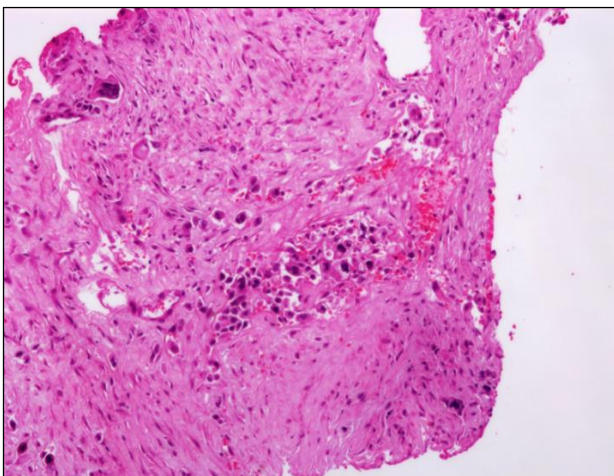


Figure 8: Biopsy from right upper quadrant abdominal lump showing gallbladder adenocarcinoma.

Biopsy from gall bladder lump suggested adenocarcinoma with similar immunohistochemistry profile (Figure 8 and 9).

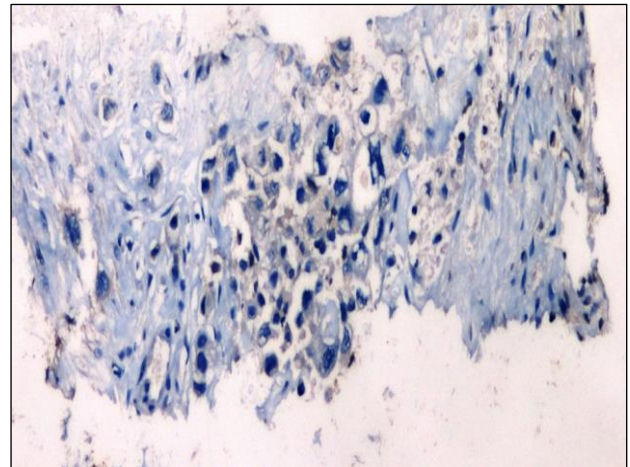


Figure 9: Gallbladder biopsy showing negative immunostaining for mammaglobin.

Diagnosis

Bilateral breasts metastasis from gallbladder adenocarcinoma.

Treatment and follow up

Platinum based palliative chemotherapy for metastatic gallbladder cancer was started. She was discharged after one cycle and was lost to follow up thereafter.

DISCUSSION

Breast has a very rich lymphatic and vascular supply and hence its primary malignancy spreads to the loco-regional and distant sites very easily. Incidence of metastasis to the breast is 0.5 to 3%. Zhou et al in their case series of 28 patients have described the secondaries in breast from various extra-mammary sites. These included lung, rectum, ovary, pancreas and even prostate.⁴ Secondaries from colon cancer in a breast has also been reported.^{5,6}

It is difficult to suspect a breast lump as metastatic from some other primary in the absence of symptoms and signs related to the later. Radiological tests do reveal the neoplastic nature of the breast lump but they hardly distinguish between primary or metastatic disease. Bitencourt et al, in their study have stated that on radiology, metastatic lesions in breast usually appear well circumscribed and lack micro-calcifications as compared to primary carcinoma breast. Moreover, lymphatic spread tends to cause diffuse breast involvement with skin changes (lymphedema, skin thickening) mimicking inflammatory breast cancer whereas haematogenous spread leads to well defined lumps with cystic areas and calcifications.⁷ Histopathology and immuno-histochemistry along with clinical correlation is necessary to

reach at proper diagnosis. Prognosis in such patients is also very guarded. Treatment should focus on the palliative therapy of the primary malignancy.

CONCLUSION

Breast metastasis from extra mammary sites is very rare and gallbladder cancer metastasis to bilateral breasts has never been reported earlier. Diagnosis of such a case needs thorough clinical, radiological and histopathological examination. Immunohistochemistry of breast specific markers is essential to exclude breast as the primary site. Prognosis is very bad and treatment should be directed towards palliative therapy of primary malignancy.

Funding: No funding sources

Conflict of interest: None declared

Ethical approval: Not required

REFERENCES

1. Zagouri F, Sergentanis TN, Koulocheri D, Nonni A, Bousiotou A, Domeyer P, et al. Bilateral synchronous breast carcinomas followed by a metastasis to the gallbladder: a case report. *World J Surg Oncol.* 2007;5(1):101.
2. Di Vita M, Zanghì A, Lanzafame S, Cavallaro A, Piccolo G, Berretta M, et al. Gallbladder metastases of breast cancer: from clinical-pathological patterns to diagnostic and therapeutic strategy. *Clin Ter.* 2011;162(5):451-6.
3. Malik AA, Wani ML, Wani SN, Malik RA, Malik TR. Breast metastasis from carcinoma of gall bladder. *Int J Health Allied Sci.* 2013;2(1):35-6.
4. Zhou S, Yu B, Cheng Y, Xu X, Shui R, Bi R, et al. Metastases to the breast from non-mammary malignancies: A clinicopathologic study of 28 cases. *Chinese J Pathol.* 2014;43(4):231-5.
5. Barthelmes L, Simpson JS, Douglas-Jones AG, Sweetland HM. Metastasis of primary colon cancer to the breast -leave well alone. *Breast Care (Basel).* 2010;5(1):23-5.
6. Tsung SH. Metastasis of Colon Cancer to the Breast. *Case Rep Oncol.* 2017;10(1):77-80.
7. Bitencourt AGV, Gama RRM, Graziano L, Negrão EMS, Sabino SMPS, Watanabe AHU, et al. Breast metastases from extramammary malignancies: multimodality imaging aspects. *Br J Radiol.* 2017;90(1077):20170197.

Cite this article as: Gopal VR, Yadav SK, Ahmad F, Kumar S, Shukla S, Bhargav M. Bilateral breasts metastases from Gall bladder adenocarcinoma: a rare presentation. *Int Surg J* 2019;6:3019-22.