

Original Research Article

Evaluation of different methods of laparoscopic treatment of common bile duct stones

Elghamry E. Elghamry*, Mohamed M. Elsheikh, Hamdy A. Mohamed

Department of General Surgery, Faculty of Medicine, Tanta University, Egypt

Received: 15 May 2019

Revised: 20 June 2019

Accepted: 29 June 2019

***Correspondence:**

Dr. Elghamry E. Elghamry,

E-mail: elghamry2@yahoo.com

Copyright: © the author(s), publisher and licensee Medip Academy. This is an open-access article distributed under the terms of the Creative Commons Attribution Non-Commercial License, which permits unrestricted non-commercial use, distribution, and reproduction in any medium, provided the original work is properly cited.

ABSTRACT

Background: Common bile duct (CBD) stones are the second most common complication of gall bladder stones. The best management of patients with CBD stones remains controversial. The aim of this study was to evaluate the methods of laparoscopic CBD exploration (LCBDE).

Methods: This prospective study was conducted on 30 patients with CBD stones through 2 years. CBD stricture was excluded. Authors used transcystic and transcholedochotomy approaches for LCBDE either with or without choledochoscope. Primary repair of the choledochotomy incision was done.

Results: The mean age was 48.90 ± 11.84 years. Biliary colic was the presentation in 63.3% of patients. The transcystic approach for CBD exploration was used in 16 cases without conversion, 11 cases were completed without choledochoscope, while 5 cases with choledochoscopic guided extraction. Choledochotomy approach had been used in 13 cases, 6 cases were completed with choledochoscope and 7 cases without it, two cases of them failed. One case failed from the beginning and was converted to open exploration. 5 ERCP previously inserted stents were removed. The mean operative time was 162.33 ± 74.67 min. Bile leakage occurred in 2 cases following the choledochotomy approach. The mean hospital stay was 3.37 ± 1.38 days.

Conclusion: LCBDE is a feasible, effective and safe approach to bile duct stones. Depending on proper training and gaining experience.

Keywords: Choledocoscope, Choledochotomy, Common bile duct stone, Laparoscopic common bile duct stone exploration

INTRODUCTION

The incidence of gallbladder stones in adults ranges from 6% to 10%.¹ Choledocholithiasis occurs in about 10% to 15% of patients with gall bladder stones and can lead to a lot of complications, such as obstructive jaundice, biliary colic, cholangitis and pancreatitis.² After worldwide acceptance of laparoscopic cholecystectomy as the gold standard for the management of gallbladder stone disease, extension of the benefits of the laparoscopic approach to the treatment of common bile duct stones becomes the

logical next step.³ The best management of patients with common bile duct stones has always been challenging, and it remains controversial.⁴ Progress in endoscopic technology and equipment and improvement in laparoscopic expertise established the principal minimally invasive techniques.⁵ However, managing CBD stones remains controversial, with the debate between a single-stage procedure in the form of laparoscopic common bile duct exploration (LCBDE) with cholecystectomy and two-stage procedure using endoscopic retrograde cholangio pancreatography

(ERCP) either before or after cholecystectomy.⁶ The utilization of LCBDE is gradually increasing and is being accepted for CBD clearance; it is associated with reduced hospital stay compared to preoperative ERCP followed by laparoscopic cholecystectomy.⁷ However, as LCBDE needs more advanced laparoscopic skills, and manipulation of the flexible choledochoscope, the preferred procedure in many hospitals remains to do ERCP either before or after laparoscopic cholecystectomy.⁸ The objectives of this work were to evaluate different methods of laparoscopic common bile duct exploration in treatment of common bile duct stones regarding to: feasibility, operative time, operative complications, failure rate, postoperative complications and hospital stay.

METHODS

This prospective study was conducted on 30 patients admitted with common bile duct stones to the GIT and laparoscopic surgery Unit, Department of General Surgery, Tanta University Hospitals during the period from December 2016 to December 2018.

All Patients with CBD stones were included in this study while cases with CBD strictures diagnosed by MRCP were excluded. Preoperatively, full laboratory investigations were done including serum levels of bilirubin, serum glutamic pyruvic transaminase (SGPT), serum glutamic oxaloacetic transaminase (SGOT), amylase and lipase levels. Abdominopelvic ultrasonography (US) and magnetic resonance cholangiopancreatography (MRCP) were performed with comment on common bile duct (CBD) diameter, number and size of stones Figure 1A. A History of previous (ERCP) and stenting, Figure 1B was carefully recorded.

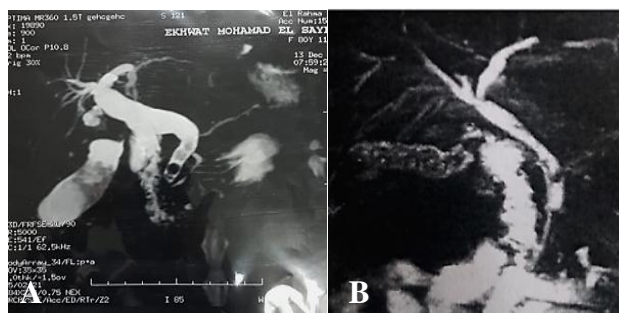


Figure 1: (A) MRCP showing dilated CBD and IHBR with multiple stones, (B) MRCP showing single CBD stone with stent inserted with previous ERCP and hepatic ducts dilatation.

Authors prepared a fluoroscopic unit, mobile C-arm unit, Olsen cholangiography fixation clamp, a 4 Fr cholangiography catheter, Ultavest (diluted 1:2 with normal saline), needle holders, stone retrieval baskets, size 3 Fr. Choledochoscopes (3 mm and 5 mm) were placed on a separate stand.

The Calot triangle was dissected, displaying the critical view of safety and exposing the cystic duct- CBD junction and /or the anterior surface of the CBD. This is to allow for the insertion of instruments and the removal of stones. The cystic artery is identified and secured with ties then divided. A tie was then applied to the cystic duct at the gall bladder neck to prevent stone migration into the CBD during surgery.

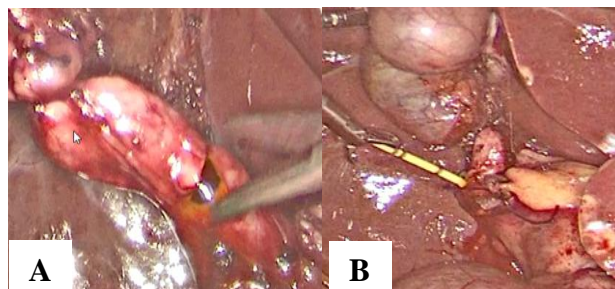


Figure 2: (A) Partial cut of cystic duct and (B) cannulation for IOC.

IOC was done through a small incision of the cystic duct using scissors Figure 2A and 2B; care was taken to avoid introduction of air bubbles during the performance of the IOC to avoid false results. Authors reviewed the images of the cholangiography for the presence of stones and their sites and size Figure 3A and 3B for deciding which approach will be used.

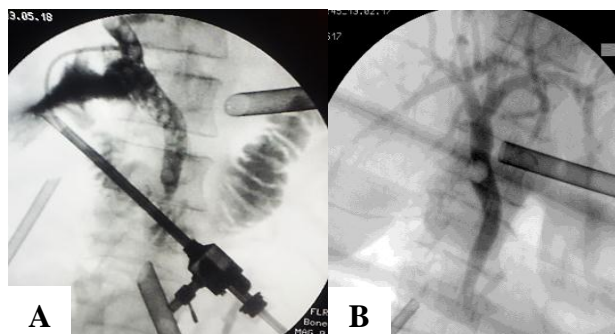


Figure 3: (A) Numerous CBD stones and (B) single CBD stone by IOC.

The transcystic approach began with flushing the CBD with warm saline via the catheter in the cystic duct. Small stones may be flushed by this way, especially after intravenous injection of hyoscine (buscopan). If flushing was inadequate to clear the small stones, Authors used fluoroscopic-guided stone retrieval basket Seigura or Dormia baskets (Boston Scientific®) for extraction of the CBD stones, inserted through the cholangiography catheter. This is the basket in catheter technique.⁹

Once the basket engaged a stone, it was then delivered. Authors used this maneuver in most of our cases. This was also capable of the removal and extraction of previously inserted ERCP stents Figure 4.

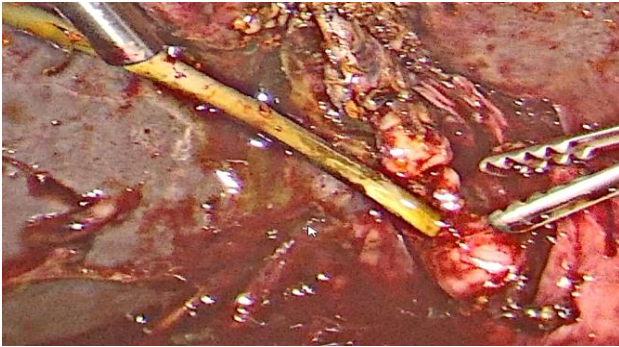


Figure 4: Transcystic extraction of previous ERCP stent with stone retrieval basket.

In some cases, Authors used a 3 mm choledochoscope (Karl Storz, Germany) for guiding the stone extraction, Figure 5A. A retrieval basket was inserted through the choledochoscope catching the stone (s) under vision followed by extraction, Figure 5B. Intrahepatic exploration can be achieved through 180-degree angulation and moving the tip of the choledochoscope up into the CHD to complete the inspection of the intrahepatic ducts and carry out stone extraction if necessary. This is the Wiper-Blade manouver.¹⁰

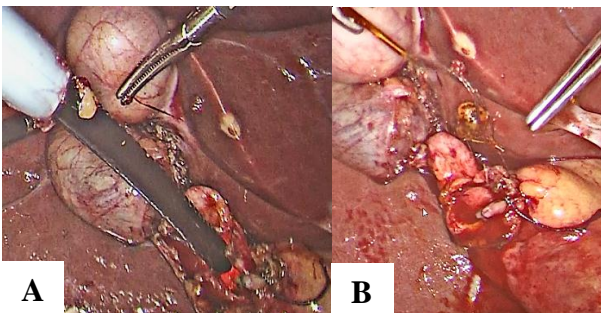


Figure 5: (A) Choledochoscopic guided transcystic CBDE and (B) transcystic stone retrieval by stone retrieval basket.

Post-procedure IOC is carried out for confirmation of clearance of the CBD. The cystic duct stump was occluded with ties (vicryl 2/0) or clips then divided. Cholecystectomy was then completed in the usual steps; intra-abdominal drain was inserted in most of our cases.

The choledochotomy approach was used in case of failed transcystic approach or in case of large stones or abnormal insertion of cystic duct into CBD. It began with Dissection of the peritoneal covering of the supraduodenal portion of the CBD. A longitudinal choledochotomy incision of about 1 cm in length was made using scissors.

Stone extraction was done either by directly grasping stones appearing at the incision, milking of the CBD from below upwards using blunt atraumatic graspers, by irrigation with warm saline through the choledochotomy or Stone extraction with a basket Figure 6A or by a 5 mm

choledochoscope through which a retrieval basket can be inserted under direct vision. Primary repair of the choledochotomy incision was done in our cases without stenting or drainage with simple interrupted sutures with 4/0 vicryl or PDS (Figure 6B). This was followed by completion IOC then cholecystectomy and drain insertion.

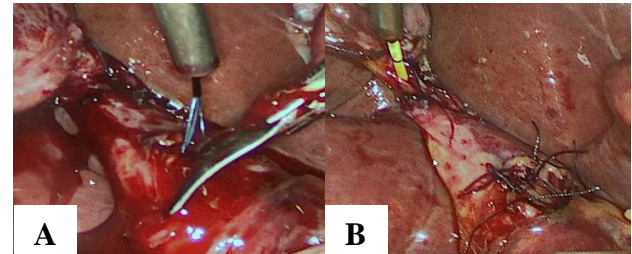


Figure 6: (A) CBD stone extraction with saline basket abd (B) primary closure of choledochotomy incision with vicryl 4/0.

All the patients included in this study were subjected to short term follow up 2 weeks and 2 months after operation using US for CBD diameter and any missed stones detection and total bilirubin. Data were analyzed using IBM SPSS software package version 20.0. (Armonk, NY: IBM Corp. Qualitative data were described using number and percent. Quantitative data were described using range (minimum and maximum), mean, standard deviation and median. Significance of the obtained results was judged at the 5% level.

RESULTS

There were 21 females (70%) with a mean age of 48.90±11.84 years. 9 (30%) patients had controlled hypertension, 3 (10%) patients had controlled DM and 1 (3.3%) had cardiac disease. Right hypochondrial pain in the form of biliary colic was the most common presentation in 19 patients Table 1.

Table 1: Distribution of the studied cases according to initial presentation.

Initial presentation	No.	%
Rt hypochondrial pain	19	63.3
Jaundice	6	20.0
Rt hypochondrial pain and jaundice	5	16.7

Serum total and direct bilirubin were elevated in 13 cases with a mean level of 2.74±2.80 mg/dl for total, serum amylase and lipase were in normal range in all cases while liver functions including SGOT and SGPT were elevated in 17 cases. All patients had pre-operative ultrasonography and MRCP. There was no significant statistical difference between the two modalities, regarding all items except CBD diameter. This was significantly higher in MRCP than in US with a p≤0.001, Table 2.

Pre-operative ERCP was done and failed in eight (26.7%) cases. Five cases had undergone stenting. IOC was done in all patients except one (3.3%) in which cystic duct

cannulation failed due to severe adhesions. 18 patients (62.1%) had single CBD stones while 11 cases (37.9%) had multiple stones.

Table 2: Distribution of the studied cases according to ultrasound and MRCP findings (n=30).

Findings	Ultrasound finding		MRCP findings		Test of significance	P value
	No.	%	No.	%		
Thickened wall of GB						
No	9	30.0	9	30.0	McN	1.000
Yes	21	70.0	21	70.0		
Number of stones in GB						
Single	2	6.7	2	6.7		
Multiple	28	93.3	28	93.7	McN	1.000
CBD diameter (mm)						
Min.-Max.	4.0-20.0		4.0-20.0			
Mean± SD.	11.30 ± 5.08		12.4 ± 5.22		Z=3.926*	<0.001*
Median	12.0		13.50			
CBD stones						
Single	18	60.0	18	60.0	McN	1.000
Multiple	12	40.0	12	40.0		
IHBR dilation						
No	12	40.0	12	40.0	McN	1.000
Yes	18	60.0	18	60.0		

McN: McNemar test, Z: Wilcoxon signed ranks test; *statistically significant at $p \leq 0.05$.

Table 3: Relation between operative time (min.) and approaches used (n=30).

Approaches used	N	Operative time (Min.)			U	P
		Min.-Max.	Mean± SD.	Median		
Trans cystic approach	16	8.0 -200.0	106.88± 32.55	95.0	7.50*	<0.001*
Choledochotomy approach	13	120.0- 300.0	223.08± 57.06	240.0		
Failed procedure	1#		260.0			

U: Mann Whitney test; p: p value for association between operative time (Min.) and different parameters; *statistically significant at $p \leq 0.05$; #: Excluded from the association due to small number of case (n=1).

The transcystic approach for CBDE was used in 16 cases (53.3%) without conversion to open surgery, 11 cases (36.7%) were completed without choledochoscopy, 6 cases with stone extraction basket and 5 cases with saline irrigation. 5 cases (16.7%) were completed with choledochoscopic guided extraction without failure. The Choledochotomy approach was used in 13 cases (43.3%), 6 cases were completed with choledochoscopy and 7 cases without it. Two cases failed and were converted to open surgery due to stone impaction at the ampulla with failure of all attempts to extract the stones. Open CBDE succeeded in one case with hepaticojejunostomy bypass. In addition, 3 of the 5 previously inserted stents were removed transcystically and 2 through the choledochotomy. Biliary drainage (T-tube) was not done in any choledochotomy cases. All were primarily repaired with sutures (11 cases). Completion cholangiography was done in the 27 laparoscopically completed cases without any abnormal finding. Authors placed a sub hepatic drain in 25 (83.3%) cases. The Operative time ranged from 80-300 min with a mean of 162.33 ± 74.67 min.

The operative time was longer in the choledochotomy approach than the transcystic exploration. This was statistically significant with $p \leq 0.001$ Table 3.

Wound (Port site) infection requiring antibiotics occurred in 2 patients (6.7%) and chest infection in 2 cases. In addition, bile leakage occurred in 2 cases of choledochotomy approach. It appeared on the second day in one case, with 200 cc bile in the drain bag which decreased gradually on conservative management till it disappeared on the 5th post-operative day.

The other case developed bile in the drain by the third day with 600 cc of bile which increased to 1000 cc by the fifth day. ERCP was done with a sphincterotomy revealing edema at the sphincter of oddi without residual stones. This case had 45 stones removed from the CBD. The bile leak stopped, the drain was removed, and the patient was discharged on the 8th day. Most intra-abdominal drains were removed on the 2nd or 3rd post-operative day except in the previous 2 complicated cases.

Serum bilirubin was measured on the 3rd day, after 2 weeks and after 2 months. Abdominal ultrasonography was carried out to measure diameter of CBD at the time of discharge, after 2 weeks and after 2 months. These revealed normal bilirubin levels and CBD diameter after 2 months. The post-operative hospital stay ranged from 2-8 days with a mean period of 3.37 ± 1.38 day. Finally, there was an increased duration of hospital stay in relation with increased operative time with $p < 0.0001$.

DISCUSSION

The present study included 63.3% of cases presented with right hypochondrial pain, 20% presented with jaundice while 16.7% presented with both right hypochondrial pain and jaundice. In the study of Mohamed et al., 87% presented with acute biliary pain with jaundice, 8% presented with acute pancreatitis while 6% presented only with jaundice.¹¹ Tan et al reported the initial presentations of 60.0% with right hypochondrial pain and 46.0% with jaundice. Acute cholangitis accounted for 32% of the emergency presentations, followed by acute pancreatitis in 10.0% and acute cholecystitis in 10.0%.¹²

70% of our cases had thickened gall bladder wall by both US and MRCP, 93.3% of cases had multiple gall bladder stones, dilated CBD with mean diameter of 11.30 ± 5.08 mm by US and 12.43 ± 5.22 mm by MRCP, which has statistically significant increase in the diameter of CBD by MRCP than US. The study of Grubnik et al, reported mean CBD diameter of 10.2 by US.¹³

The minimum diameter of the CBD at which laparoscopic CBD exploration by choledochotomy is feasible and safe is controversial. Crawford et al, reported that LCBDE is safer when the CBD is more than 8 mm in diameter.¹⁴ Verbese et al reported that choledochotomy should be avoided if the CBD is less than 1 cm in diameter for fear of CBD stricture.¹⁵

Authors selected the cases for either transcystic or transcholedochotomy approaches according to cystic duct diameter, CBD diameter and the number and size of stones in CBD. Our success rate in LCBDE was 90%. The success rate with choledochoscopy in either approach was 84.7% in choledochotomy approach and 100% in transcystic approach.

The total number of conversions to open surgery was 3 cases. Zhang et al, study reported that the stone removal success rate was 96.2% (228/237) and only 9 (3.8%) failed and needed endoscopic sphincterotomy or endoscopic papillary balloon dilation.¹⁶ Zhou et al, (72 cases) reported that 6 cases were converted to open operation due to impacted stones with a success rate of 91.7%.¹⁷ Feng et al revealed that stone clearance was achieved in 87.3% of patients in the choledochotomy approach and in 88.9% in the trans cystic approach. There was no significant difference between the two approaches. Conversion occurred in 7.5% of choledo-

chotomy cases and 10.9% of patients undergoing transcystic exploration.¹⁸ In the study by Tan et al, there were 8.0% conversions, while only 6% conversion was seen in the Bansel et al, study.¹⁹

The choledochotomy incision in the current study was done longitudinally for a length of 1 cm, extended in the presence of large stones in the supraduodenal portion of the CBD. On the other hand, Khaled et al, performed a transverse choledochotomy incision. They reported that a transverse choledochotomy is laparoscopically more accessible to closure and reduces the risk of duct stenosis.²⁰ Choledochotomy incision management after successful laparoscopic transcholedochal CBDE is a matter of debate. Our choledochotomy cases were managed by primary closure with interrupted absorbable sutures. 18% developed biliary leakage. Chen et al, observed that primary closure is safe after LCBDE (n = 194).²¹ Vidagany et al, did primary closure after LCBDE in 160 patients. Bile leakage was reported in only 6.8%. They concluded that primary closure after LCBDE is a safe technique with excellent results.²²

Podda and coworkers did a meta-analysis of all studies comparing primary duct closure and T-tube drainage after LCBDE (total 16 studies, 1770 patients). Primary duct closure showed a significant advantage over T-tube in terms of postoperative bile peritonitis, operative time, hospitalization, and median hospital cost (all $p < 0.00001$).²³

The mean operative time was 162.33 ± 74.67 minutes in the current study. This was consistent with most similar studies. Helmy et al, reported that operative time ranged from 90 to 220 minutes.²⁴ Chander et al reported 139.9 ± 26.3 min (90-205 mins).²⁵

Authors also noticed a significant reduction in time of the trans cystic approach (80-200 min) compared with the choledochotomy approach (120-300 min). It can be explained by the time needed for dissection of the CBD, intracorporeal suturing and knot tying. This agreed with the study of Quaresim et al, with a significant difference between transcystic and choledochotomy approaches.²⁶ In Tokumura et al, laparoscopic choledochotomy needed a longer operating time than the trans cystic approach.²⁷ The study done by Puhalla et al, reported an increased operative time with choledochotomy.²⁸ In Dong et al., study, the mean operative time was much shorter in trans cystic than in choledochotomy.²⁹

Bile leakage occurred in 2 cases in the choledochotomy approach in the current study. Helmy et al, reported the occurrence of post-operative complications in 3 patients (5%); 2 patients had minor bile leaks which stopped spontaneously in 2 and 4 days and one case of a missed stone.²⁴

In Dong et al, bile peritonitis was seen in two patients (2.22%) after T-tube removal, and the two patients recovered with expectant treatment.²⁵

The mean hospital stay was 3.37 ± 2 to 8 days. The patients with conversion to open procedures and those who developed complications had the longest stay. The hospital stay decreased with increasing experience, and it was longer in the early cases for fear of complications. Kadam et al reported hospital stay of 2 to 9 days.²⁶ Tekin et al reported 3 to 7 days.²⁷

When Authors analyzed correlations of length of hospital stay with other data, Authors noticed an increased hospital stay with the choledochotomy approach, hospital stay ranged from 3 to 8 days while in the transcystic approach, it ranged from 2 to 3 days. Hongjun et al, revealed significant differences in hospital stay between the transcystic LCBDE group 9.82 ± 3.48 day and transcholedochal LCBDE group 10.74 ± 5.34 day.²⁹ Grubnik et al reported shorter hospital stay in transcystic approach of 3.4 ± 1.7 than in choledochotomy approach 7.6 ± 2.5 .¹³ There was a significant increase in hospital stay with the occurrence of bile leakage, which was also reported in the studies of Karaliotas et al, Grubnik et al and Abella et al who reported increased length of hospital stay with bile leakage.^{4,13,28}

CONCLUSION

LCBDE is a feasible, effective and safe procedure, depending on several factors including, proper training and gaining experience, adequate equipment, and laparoscopic and choledochoscopic facilities, avoiding the drawbacks of ERCP as well as open CBD approach.

IOC is an important maneuver and should be done in any suspicious case to outline the biliary anatomy and help proper decision making. It is technically challenging to perform choledochoscopy, and if it is achievable, with practice and skills development, it facilitates the extraction of stones under direct visualization, and this of course increases the success rate of LCBDE. Choledocotomy is better to be done when there is a large stone from the start and with a CBD diameter more than 1 cm. It is safe to do primary interrupted closure of CBD in this case T-tube drainage is unnecessary for decompression of the biliary tree. ERCP still holds an important role in the management of choledocholithiasis and in complicated biliary surgery.

Funding: No funding sources

Conflict of interest: None declared

Ethical approval: The study was approved by the Institutional Ethics Committee

REFERENCES

1. Sharma A, Dahiya P, Khullar R, Soni V, Baijal M, Chowbey PK. Management of common bile duct

- stones in the laparoscopic era. Indian J Surg. 2012;74(3):264-9.
2. Shojaiefard A, Esmaeilzadeh M, Ghafouri A, Mehrabi A. Various techniques for the surgical treatment of common bile duct stones: a meta review. Gastroenterol Res Pract. 2009.
 3. Berthou J, Dron B, Charbonneau P, Moussalier K, Pellissier L. Evaluation of laparoscopic treatment of common bile duct stones in a prospective series of 505 patients: indications and results. Surg Endosc. 2007;21(11):1970-4.
 4. Karaliotas C, Sgourakis G, Goumas C, Papaioannou N, Lilis C, Leandros E. Laparoscopic common bile duct exploration after failed endoscopic stone extraction. Surg Endosc. 2008;22(8):1826-31.
 5. Memon MA, Hassaballa H, Memon MI. Laparoscopic common bile duct exploration: the past, the present, and the future. Am J Surg. 2000;179(4):309-15.
 6. Kenny R, Richardson J, McGlone ER, Reddy M, Khan OA. Laparoscopic common bile duct exploration versus pre or post-operative ERCP for common bile duct stones in patients undergoing cholecystectomy: is there any difference. Int J Surg. 2014;12(9):989-93.
 7. Lu J, Cheng Y, Xiong XZ, Lin YX, Wu SJ, Cheng NS. Two-stage vs single-stage management for concomitant gallstones and common bile duct stones. WJG. 2012;18(24):3156-66.
 8. Darrien JH, Connor K, Janeczko A, Casey JJ, Paterson-Brown S. The surgical management of concomitant gallbladder and common bile duct stones. HPB Surgery. 2015;2015:165068-73.
 9. Qandeel H, Zino S, Hanif Z, Nassar MK, Nassar AH. Basket-in-catheter access for transcystic laparoscopic bile duct exploration: technique and results. Surg Endosc. 2016;30(5):1958-64.
 10. Gough V, Stephens N, Ahmed Z, Nassar AH. Intrahepatic choledochoscopy during trans-cystic common bile duct exploration; technique, feasibility and value. Surg Endosc. 2012;26(11):3190-4.
 11. Mohamed MA, Bahram MA, Ammar MS, Nassar AH. One-session laparoscopic management of combined common bile duct and gallbladder stones versus sequential ERCP followed by laparoscopic cholecystectomy. J Laparoendoscopic Adv Surg Tech. 2015;25(6):482-5.
 12. Tan KK, Shelat VG, Liau KH, Chan CY, Ho CK. Laparoscopic common bile duct exploration: our first 50 cases. Ann Acad Med Singapore. 2010;39(2):136-42.
 13. Grubnik VV, Tkachenko AI, Ilyashenko VV, Vorotyntseva KO. Laparoscopic common bile duct exploration versus open surgery: comparative prospective randomized trial. Surgical Endoscopy. 2012;26(8):2165-71.
 14. Crawford DL, Phillips EH. Laparoscopic common bile duct exploration. World J Surg. 1999;23(4):343-9.

15. Verbese JE, Birkett DH. Common bile duct exploration for choledocholithiasis. *Surg Clin North Am.* 2008;88(6):1315-28.
16. Zhang W, Xu G, Huang Q, Luo K, Dong Z, Li J, et al. Treatment of gallbladder stone with common bile duct stones in the laparoscopic era. *BMC Surg.* 2015;15:7.
17. Zhou Y, Wu X, Fan R, Zhou G, Mu X, Zha W, et al. Laparoscopic common bile duct exploration and primary closure of choledochotomy after failed endoscopic sphincterotomy. *Int J Surg.* 2014;12(7):645-8.
18. Feng Q, Huang Y, Wang K, Yuan R, Xiong X, Wu L. Laparoscopic Transcystic Common Bile Duct Exploration: Advantages over Laparoscopic Choledochotomy. *PLOS ONE.* 2016;11(9):0162885.
19. Bansal VK, Misra MC, Garg P, Prabhu MA. Prospective randomized trial comparing two-stage versus single-stage management of patients with gallstone disease and common bile duct stones. *Surg Endosc.* 2010;24(8):1986-9.
20. Khaled YS, Malde DJ, de Souza C, Kalia A, Ammori BJ. Laparoscopic bile duct exploration via choledochotomy followed by primary duct closure is feasible and safe for the treatment of choledocholithiasis. *Surg Endosc.* 2013;27(11):4164-70.
21. Chen D, Zhu A, Zhang Z. Laparoscopic transcystic choledochotomy with primary suture for choledocholith. *JSLs.* 2015;19(1):e2014.00057.
22. Vidagany EN, Pozo C, Tomás PN, JÁ DA, Tarragón VA and Masson BF. Eleven years of primary closure of common bile duct after choledochotomy for choledocholithiasis. *Surg Endosc.* 2016;30(5):1975-82.
23. Podda M, Polignano FM, Luhmann A, Wilson MS, Kulli C, Tait IS. Systematic review with meta-analysis of studies comparing primary duct closure and T-tube drainage after laparoscopic common bile duct exploration for choledocholithiasis. *Surg Endosc.* 2016;30(3):845-61.
24. Helmy MZ, Ahmed AE. Safety and efficacy of laparoscopic versus open surgery in management of common bile duct stones: experience at the Sohag University Hospital, Egypt. *Int Surg J.* 2018;5(11):3727-32.
25. Dong ZT, Wu GZ, Luo KL and Li JM. Primary closure after laparoscopic common bile duct exploration versus T-tube. *J Surg Res.* 2014;189(2):249-54.
26. Kadam R, Saxena D, Rana AS, Chabra S, Ahmed Z, Vij V, et al. Laparoscopic common bile duct exploration versus ERCP/stenting and cholecystectomy: Is a single staged procedure better? *Int J HBP Dis.* 2016;6:57-63.
27. Tekin A, Ogetman Z. Laparoscopic exploration of the common bile duct with a rigid scope in patients with problematic choledocholithiasis. *World J Surg.* 2010;34(8):1894-9.
28. Isla AM, Morcillo IA, Abrisqueta J. Exploración laparoscópica de la vía biliar, lecciones aprendidas tras más de 200 casos. *Cirugía española: Organó oficial de la Asociación Española de Cirujanos.* 2014;92(5):341-7.
29. Hongjun H, Yong J and Baoqiang W. Laparoscopic common bile duct exploration: choledochotomy versus transcystic approach. *Surg Laparosc Percut Techn.* 2015;25(3):218-22.

Cite this article as: Elghamry EE, Elsheikh MM, Mohamed HA. Evaluation of different methods of Laparoscopic Treatment of Common Bile Duct Stones. *Int Surg J* 2019;6:2670-6.