

Review Article

Managing iatrogenic tracheal injury during esophagectomy

Niju Pegu, Joydeep Purkayastha*, Abhijit Talukdar, Bibhuti Borthakur, Dipjyoti Kalita, Gaurav Das, Srinivas Banno, Jitin Yadav, Dwipen Kalita, Pritesh Singh

Department of Surgical Oncology, Dr. B. Borooah Cancer Institute, Guwahati, Assam, India

Received: 10 May 2019

Revised: 18 June 2019

Accepted: 20 June 2019

*Correspondence:

Dr. Joydeep Purkayastha,

E-mail: drjoydeppurkayastha@gmail.com

Copyright: © the author(s), publisher and licensee Medip Academy. This is an open-access article distributed under the terms of the Creative Commons Attribution Non-Commercial License, which permits unrestricted non-commercial use, distribution, and reproduction in any medium, provided the original work is properly cited.

ABSTRACT

Iatrogenic tracheal injuries are uncommon, but potentially lethal and associated with significant morbidity. During esophagectomy the proximity of the trachea to esophagus makes it vulnerable to injury. The reported incidence of tracheal injury during esophagectomy ranges between 1-5%. Various methods for repairing tracheal injuries have been described in the literature. Most preferred mode of repair described is the reinforcement of the primary repair with flap cover. Most common autologous flaps used are pericardium, pleura, extra thoracic muscle flaps and intercostal muscle flaps. Other described methods for repairing tracheal injuries are primary repair without buttressing, and buttressing with gastric conduit serosal patch, graft and glue. In this study we reviewed different methods and outcome of repair described in the literature and our experienced of managing three cases.

Keywords: Iatrogenic tracheal injury, Esophagectomy, Autologous flap, Gastric conduit

INTRODUCTION

Iatrogenic tracheal injuries are rare, but potentially lethal and associated with significant morbidity.¹ The first report of an iatrogenic tracheal injury was by Goldstein in 1949.² Iatrogenic tracheal injuries may occur following endotracheal intubations, mediastinoscopy, percutaneous tracheostomy and mediastinal surgical interventions.³⁻⁵ The outcome depends on prompt recognition of the injury intra-operatively and immediate repair.⁶ The potential benefits of surgery are closure of the defect to facilitate effective ventilation, prevent mediastinitis due to contamination from non-sterile airways and prevent strictures and their complications of the tracheobronchial tree.

Various methods for repairing tracheal injuries have been described in the literature. Most preferred mode of repair described is the reinforcement of the primary repair with autologous flap cover. Most common autologous flaps

used are pericardium, pleura, extra thoracic muscle flaps and intercostal muscle flaps.⁷ Others described methods for repairing tracheal injuries are primary repair without buttressing, and buttressing with gastric conduit serosal patch, graft and glue.⁸⁻¹⁰ In this study we reviewed different methods and outcome of repair described in the literature and our experienced of managing three cases.

DISCUSSION

Unlike tracheobronchial injury that results from blunt trauma, most iatrogenic injuries to the airway involve longitudinal tears to the back of the trachea or tears on the side that pull the membranous part of the trachea away from the cartilage. During esophagectomy the proximity of the trachea to esophagus makes it vulnerable to injury. The reported incidence of tracheal injury during esophagectomy ranges between 1–5%.^{11,12} The incidence following double lumen intubations is between 0.12% to 0.26% in the literature.^{13,14}

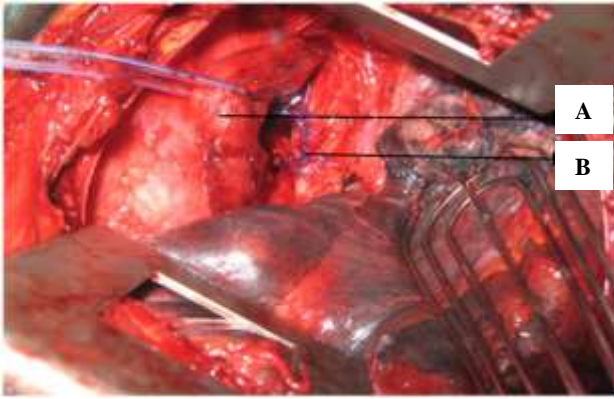


Figure 1: Thoracotomy (rent is repaired). (A) Esophagus (retracted with infant feeding tube), (B) carina repaired with interrupted prolene suture.

Different modes of injury to the trachea described in the literature are direct surgical injury, fistulisation due to local peritracheal infection, ischemic injury secondary to extensive dissection or endotracheal cuff.¹¹ We have experienced of 3 cases of iatrogenic tracheal injury in our institute following direct surgical injury in 2 cases (Figure 1) and endotracheal cuff injury during double lumen intubation in one case (Figure 2).

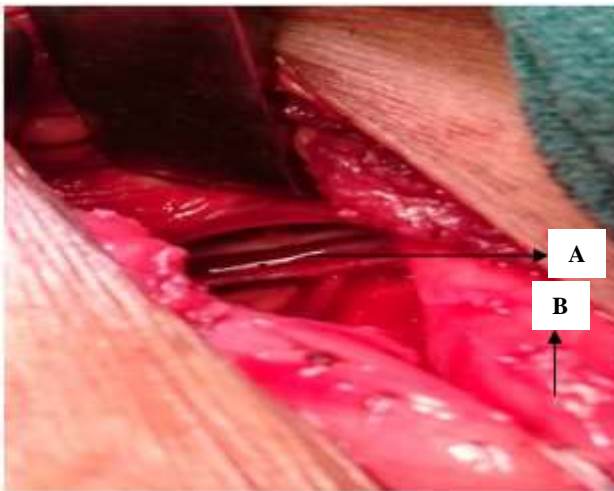

Figure 2: Neck exploration (ET tube visible). (A) Endotracheal tube (visible), (B) esophagus (retracted laterally).

Most of the injuries described in literature were in the range of 1-5 cm in size which was similar in our cases.¹⁵ Described risk factors for iatrogenic tracheal injuries in a carcinoma esophagus patient are preoperative chemoradiotherapy, extensive lymph node dissection, peritumoral infection and abscess formation, and advanced tumors located above or at the level of the carina and trans-hiatal esophagectomy (blunt esophagectomy).^{16,17} But two large trials did not show any difference when the incidence was compared between transhiatal esophagectomy and transthoracic oesophagectomy.^{1,15} In our study, two injuries occurs

during trans-hiatal esophagectomy and one injury during trans-transthoracic esophagectomy.

The described surgical approaches for managing iatrogenic tracheal injury are transcervical, transthoracic or median sternotomy.¹⁸ In our study, all the three cases are managed by thoracotomy approach in one case (Figure 1), sternotomy approach in one case and transcervical approach in one case (Figure 2).

Most commonly used method of repair described in the literature is reinforcement of the primary repair with some autologous flap cover. Most common autologous flaps described in literature are pericardium, pleura, extrathoracic muscle flaps and intercostal muscle flaps.¹⁵ Others described methods for repairing tracheal injuries are primary repair only without buttressing, and buttressing with gastric serosal patch, graft and glue.⁸⁻¹⁰

In our series, repaired was done using gastric conduit serosal patch buttressing in cervical tracheal injury, using pleural patch buttressing in one case and primary repair without buttressing (Figure 1) in one case. All surgical procedures proved to be effective in our study. There was no mortality or morbidity in the perioperative period. On follow up there was no signs of tracheobronchial stenosis.

CONCLUSION

In summary, iatrogenic tracheal injuries are rare complications following esophagectomy. Most commonly used method of repair is reinforcement of the primary repair with pericardium, pleura, extrathoracic muscle flaps and intercostal muscle flaps. Others described methods are primary repair without buttressing, and buttressing with gastric conduit serosal patch, graft or glue. In our experience of three cases we have found that the techniques are equally effective and successful both in primary repair without buttressing and using buttressing with gastric conduit serosal patch and pleural patch.

Funding: No funding sources

Conflict of interest: None declared

Ethical approval: Not required

REFERENCES

1. Hulscher JB, ter Hofstede E, Kloek J, Obertop H, De Haan P, Van Lanschot JJ. Injury to the major airways during subtotal esophagectomy: incidence, management, and sequelae. *J Thorac Cardiovasc Surg.* 2000;120:1093–6.
2. Goldstein P. Fatal interstitial and mediastinal emphysema following accidental needle perforations of the trachea during jugular venipuncture. *Am J Dis Child.* 1949;78:375–83.
3. Schipper P. Lymph nodes are important. *World J Surg.* 2009;33:785–6.
4. Lemaire A, Nikolic I, Petersen T, Haney JC, Toloza EM, Harpole DH, et al. Nine-year single center

- experience with cervical mediastinoscopy: complications and false negative rate. *Ann Thorac Surg.* 2006;82:1185–9.
5. Tezel C, Okur E, Baysungur V. Iatrogenic tracheal rupture during intubation with a double-lumen tube. *Thorac Cardiovasc Surg.* 2010;58:54–6.
 6. George SV, Samarasam I, Mathew G, Chandran S. Tracheal Injury during esophagectomy-incidence, treatment and outcome. *Trop Gastroenterol.* 2011;32(4):309-13.
 7. Sippel M, Putensen C, Hirner A, Wolf M. Tracheal rupture after endotracheal intubation: experience with management with 13 cases. *Thoracic Cardiovas Surg.* 2006;54(1):51-6.
 8. Gitter R, Daniel TM, Kesser BW, Reibel JF, Tribble CG. Membranous Tracheobronchial Injury repaired with gastric serosal patch. *Ann Thoracic Surg.* 1999;67(4):1159-60
 9. Millikan KW, Pytynia KB. Repair of tracheal defect with Goretex graft during resection of carcinoma of the esophagus. *J Surg Oncol.* 1997;66:134–7.
 10. Kram HB, Shoemaker WC, Hino ST, Chiang HS, Harley DP, Fleming AW. *J Thorac Cardiovasc Surg.* 1985;90 (5):771-5.
 11. Bartels HE, Stein HJ, Siewert JR. Tracheobronchial lesions following oesophagectomy: prevalence, predisposing factors and outcome. *Br J Surg.* 1998;85:403–6.
 12. Celiker V, Bağcı E, Aykut T. Tracheal rupture during esophagectomy. *Ulus Travma Acil Cerrahi Derg.* 2005;11:157–61.
 13. Orringer MB, Marshall B, Chang AC, Lee J, Pickens A, Lau CL. Two thousand transhiatal esophagectomies: changing trends, lessons learned. *Ann Surg.* 2007;246:363–72.
 14. Ceylan KC, Kaya SO, Samancilar O, Usluer O, Gursoy S, Ucvet A. Intraoperative management of tracheobronchial rupture after double-lumen tube intubation. *Surg Today.* 2013;43:757-62.
 15. Borasio P, Ardisson F, Chiampo G. Post-intubation tracheal rupture. A report on ten cases. *Eur J Cardiothorac Surg.* 1997;12:98-100.
 16. Gupta V, Gupta R, Thingnam SK, Singh RS, Gupta AK, Kuthe S, et al. Major airway injury during esophagectomy: experience at a tertiary care center. *J Gastrointest Surg.* 2009;13:438–41.
 17. Knauer M, Haid A, Ammann K, Lang A, Offner F, Türtscher M, et al. Complications after oesophagectomy with possible contribution of neoadjuvant therapy including an EGFR antibody to a fatal outcome. *World J Surg Oncol* 2007;5:114.
 18. Bhat MA, Singh S, Lone, Dar M, Mir. Management of Intra-operative Tracheal Injuries during Transhiatal Esophagectomy for Carcinoma Esophagus. *Webmed Central.* 2012;3:2-5.

Cite this article as: Pegu N, Purkayastha J, Talukdar A, Borthakur B, Kalita D, Das G, et al. Managing iatrogenic tracheal injury during esophagectomy. *Int Surg J* 2019;6:2652-4.