

Case Report

An uncommon vascular swelling in a child: post traumatic pseudoaneurysm

Vivek Parameswara Sarma*

Department of Paediatric Surgery, S.A.T Hospital, Government Medical College, Thiruvananthapuram, Kerala, India

Received: 06 May 2019

Revised: 16 October 2019

Accepted: 18 October 2019

*Correspondence:

Dr. Vivek Parameswara Sarma,
E-mail: vivsarma@gmail.com

Copyright: © the author(s), publisher and licensee Medip Academy. This is an open-access article distributed under the terms of the Creative Commons Attribution Non-Commercial License, which permits unrestricted non-commercial use, distribution, and reproduction in any medium, provided the original work is properly cited.

ABSTRACT

Pseudo aneurysms of the superficial temporal artery (STA) are very rare (less than 1% of aneurysms), and usually occur after blunt head injury. It usually presents as a slow growing, pulsatile mass in the temporal area. Other symptoms that may occur are headache, ear pain, facial palsy or haemorrhage. Arteriography is the diagnostic investigation and computed tomography angiography will exclude other conditions such as arteriovenous malformation and fistula and confirm the diagnosis. Surgery with ligation of the proximal and the distal parts of the vessel and resection of the aneurysm is the treatment of choice. We report the case of a 10-year-old child, with a pseudo aneurysm of the STA secondary to trauma, who underwent surgical resection of the lesion with good outcome.

Keywords: Post-traumatic, Pseudo aneurysm, Superficial temporal artery

INTRODUCTION

Pseudo aneurysms of the superficial temporal artery (STA) are very rare (less than 1% of aneurysms), and usually occur after blunt head injury.¹ It usually presents as a slow growing, pulsatile mass in the temporal area.^{1,2} Other symptoms that may occur are headache, ear pain, facial palsy or hemorrhage. Arteriography is the diagnostic investigation and computed tomography (CT) angiography will exclude other conditions such as arteriovenous (AV) malformation and fistula and confirm the diagnosis.¹⁻³ Surgery with ligation of the proximal and the distal parts of the vessel and resection of the aneurysm is the treatment of choice.^{2,3} Pseudo aneurysms are rare lesions in children, and are usually reported after trauma or iatrogenic arterial injury.⁴ Pseudo aneurysms of the STA are very rare (less than 1% of aneurysms), and usually occur after blunt head injury.^{4,5} We report the

case of a 10-year-old child, with a pseudo aneurysm of the STA secondary to trauma.

CASE REPORT

A 10-year-old female presented with swelling on the right side of forehead since 4 months. There was a history of blunt trauma to the forehead few months back, with gradual increase in size of the lump. The child was otherwise asymptomatic. There was no history of any congenital lesion or skin discoloration at the site. Physical examination revealed a 3 × 3 cm pulsatile swelling on the right temporal region (Figure 1). A clinical diagnosis of AV malformation or pseudoaneurysm was made, and the child was evaluated.

Ultrasound Doppler revealed a vascular lesion suggestive of Aneurysm; there was no thrombus in the lesion. CT angiography demonstrated a localized cystic dilatation of

the anterior branch of the right temporal artery with no intracranial extension and no other aneurysm. A radiological diagnosis of pseudoaneurysm was proposed (Figure 2 and 3). The child underwent surgical exploration and ligation and division of the feeding vessel with excision of the aneurysm. The postoperative recovery was uneventful. The histopathological report was pseudoaneurysm. The final clinical diagnosis made was traumatic pseudoaneurysm.

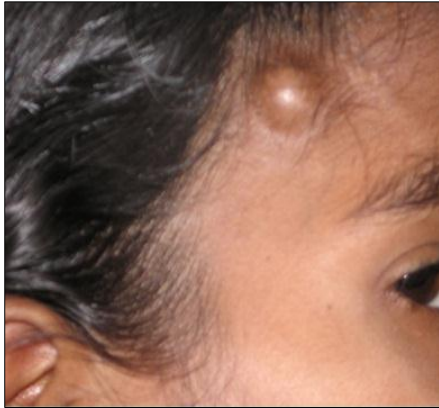

Figure 1: Clinical presentation of scalp swelling.

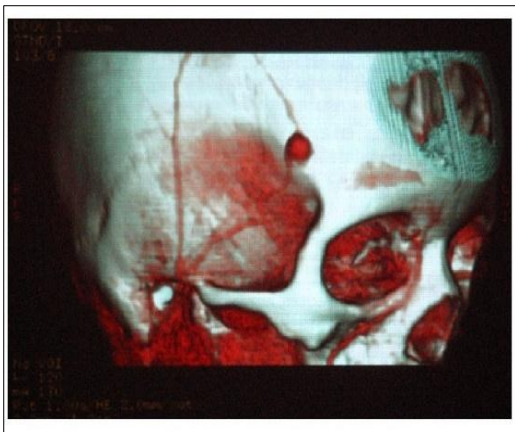

Figure 2: The picture on CT angiography.

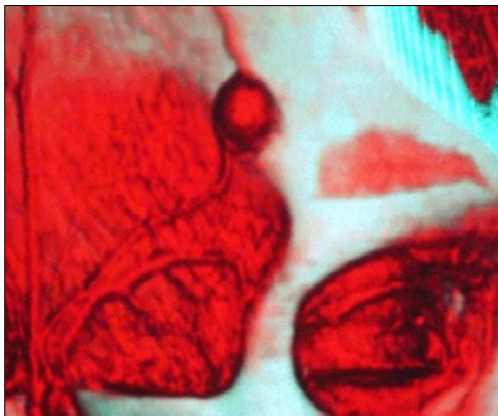


Figure 3: Superficial temporal artery aneurysm on CT angiography.

DISCUSSION

Aneurysm is defined as localised or diffuse dilatation of an artery to >1.5 times its normal diameter.¹ They are classified as true (contains all 3 layers of arterial wall) or false (single layer of fibrous tissue as wall of sac) or AV. Etiology can be congenital, acquired, traumatic, degenerative or infective.^{1,2} Shape is described as fusiform, saccular or dissecting. Complications include pressure effects, thrombosis, embolisation, infection or rupture.^{3,4}

Traumatic pseudoaneurysm: the most commonly affected artery is the STA, which is at risk due to its superficial course and being sited directly against the skull (in the area between the frontalis and temporalis muscles) with less protection of trauma.¹⁻⁴ The STA is the terminal branch of the external carotid and usually has an anterior (frontal) branch and a posterior (parietal) branch.^{1,2}

The etiology of the lesion is commonly traumatic (80%) or iatrogenic. Pseudo aneurysms develop due to complete or partial disruption of arterial intima from trauma induced necrosis of part of the arterial wall.^{5,6} Blood extravasates from the injured artery with formation of a hematoma and a pseudo capsule around it. The hematoma capsule then expands and the clot reabsorbs resulting in a cavity leading to pseudo aneurysm formation.^{1,2,5,6}

It usually presents as a slow growing, pulsatile mass in the temporal area. Other symptoms that may occur are headache, ear pain, facial palsy or hemorrhage.^{2,3,5,6} The volume of the mass and the pulsation can be reduced with local compression near the auditory canal. A systolic murmur and palpable thrill may also be present.^{1,2,5,6}

Doppler study demonstrates vessel dilatation in direct continuity with the STA, with turbulent flow, and it can show a parietal thrombus within the aneurysm. Contrast CT scan or MRI may demonstrate extra cranial mass and intracranial pathology, but both are not diagnostic.^{5,6} Arteriography is the diagnostic investigation and CT angiography will exclude other conditions such as AV malformation and fistula and confirm the diagnosis.^{1,2,6}

Conservative treatment is not advised. Surgery with ligation of the proximal and the distal parts of the vessel and resection of the aneurysm is the treatment of choice.^{1,6,7} Treatment is required to avoid the risk of hemorrhage in case of rupture, to relieve symptoms like headache or cosmetic defect and the compression of adjacent structures and risk of erosion of the underlying bone.^{6,7} Reconstruction of the vessel is not necessary, as the region has abundant blood supply.^{7,8} Other treatment options are embolization (using particles, micro coils, balloons, or liquids such as alcohol, isobutyl-2-cyanoacrylate and iophendylate) or ultrasound guided percutaneous thrombin injection.^{7,9}

CONCLUSION

Traumatic pseudoaneurysm of the STA is an uncommon lesion, and therefore, the clinical diagnosis requires a high index of suspicion, to avoid potentially catastrophic complications. The clinical and radiological characteristics are helpful to clinch the diagnosis. The treatment is essentially surgical with resection of the lesion and ligation of the proximal and distal parts of the STA.

Funding: No funding sources

Conflict of interest: None declared

Ethical approval: Not required

REFERENCES

1. Zarins CK, Hill BB, Wolf YG. Aneurysmal vascular disease. Textbook of surgery. Philadelphia: Saunders; 2001: 1371.
2. Peick AL, Nichols WK, Curtis JJ, Silver D. Aneurysms and pseudoaneurysms of the superficial temporal artery caused by trauma. J vascular surg. 1988;8(5):606-10.
3. Jidane S, Zerhouni H, Belyamani L, Oubejja H, Ettayebi F. Post Traumatic Pseudoaneurysm of the Superficial Temporal Artery in Child: A Case Report and Review of the Literature. Ann Clin Anesth Res. 2017;1(1):1003.
4. Sardana V, Sundar IV, Jaiswal M, Gupta P, Chopra S. Traumatic pseudoaneurysm of the superficial temporal artery: a case report and review of literature. Indian J Neurotrauma. 2012;9(1):56-8.
5. Rubio-Palau J, Ferrer-Fuertes A, García-Díez E, Garcia-Linares J, Martí-Pagès C, Sieira-Gil R. Traumatic pseudoaneurysm of the superficial temporal artery: case report and review of the literature. Oral Surg, Oral Med, Oral Pathol Oral Radiol. 2014;117(2):112-4.
6. Qureshy FA, Choi S, Buma B. Traumatic pseudoaneurysm of the superficial temporal artery in a pediatric patient: a case report. J Oral Maxillofacial Surg. 2008;66(1):133-5.
7. Wiart T, Lebas D, Modiano P. Superficial temporal artery pseudoaneurysm: 2 cases. Ann Dermatol Venereol. 2018;145(4):257-60.
8. Lemonnier C, Melki J, Benadiba L, Janvresse A. Traumatic pseudoaneurysm of the superficial temporal artery: a case report. J Mal Vasc. 2010;35:263-5.
9. Mizouni H, Hedhli M, Zainine R, Sahtout S, Besbes G, Menif E. Post-traumatic pseudoaneurysm of the superficial temporal artery: a rare cause of facial mass. Euro J Radiol Extra. 2011;79(1):33-5.

Cite this article as: Sarma VP. An uncommon vascular swelling in a child: post traumatic pseudoaneurysm. Int Surg J 2019;6:4127-9.