

Review Article

The approach to a neonate with suspected intestinal obstruction: the pediatric surgical perspective

Vivek Parameswara Sarma*, Sunil S. Menon

Department of Paediatric Surgery, SAT Hospital, Government Medical College, Thiruvananthapuram, Kerala, India

Received: 05 May 2019

Revised: 16 October 2019

Accepted: 17 October 2019

*Correspondence:

Dr. Vivek Parameswara Sarma,
E-mail: vivsarma@gmail.com

Copyright: © the author(s), publisher and licensee Medip Academy. This is an open-access article distributed under the terms of the Creative Commons Attribution Non-Commercial License, which permits unrestricted non-commercial use, distribution, and reproduction in any medium, provided the original work is properly cited.

ABSTRACT

In this article, the possible pitfalls while evaluating a new-born with intestinal obstruction are reviewed and a diagnostic algorithm is proposed. The difficulties include the finding of an otherwise well child in most of the surgical problems and the fact that many signs are subtle. The diagnosis of distal bowel obstruction rests on proper radiological interpretation. The new-born with features of intestinal obstruction poses a diagnostic challenge to the neonatologist and paediatric surgeon. But, the systematic interpretation of history, physical examination, radiograph and contrast imaging in select cases will enable a proper and timely diagnosis.

Keywords: Atresia, Intestinal obstruction, Malrotation, Midgut volvulus, Neonatal

INTRODUCTION

The cardinal presenting features of neonatal intestinal obstruction are: bilious vomiting, abdominal distension, delay or non passage of meconium. The main concerns of a pediatrician or neonatologist dealing with a neonate having suspected intestinal obstruction or abdominal distension are the following: Is it physiological or pathological? Is the cause medical or surgical? What could be the danger signs in the child? How should the child be evaluated? How should the investigations be interpreted? What mandates an early surgical referral?

In the evaluation and assessment of the child, the following pattern can be helpful. In this review article, we have attempted to analyse the clinical presentation (antenatal and postnatal), differential diagnosis (medical and surgical), radiological interpretation and diagnostic algorithm in neonatal intestinal obstruction.

The review was based on the analysis of clinical records of all patients with neonatal obstruction and a review of current literature. The analysis is done under the

following considerations as analysis of history, physical examination, differential diagnosis which is medical and surgical, assessment of the neonate, radiological interpretation and common clinical scenarios.

ANALYSIS OF HISTORY

The following factors should be considered in the analysis of the history of the child which includes timing of onset and sequence of symptoms (the initial symptom, if bilious vomiting, suggest a proximal obstruction; while early abdominal distension suggest a distal obstruction) presence of bilious vomiting or nasogastric tube aspirate; history of delay in passage of meconium or non-passage of meconium; blood in stools [can occur in neonatal necrotizing enterocolitis (NNEC) or advanced malrotation of gut with midgut volvulus (MGV)]; antenatal history of polyhydramnios- in congenital gut obstruction like duodenal or jejunal atresia; maternal hypothyroidism (very common medical cause of intestinal obstruction in neonate) or diabetes mellitus or drug intake or infections can present with functional intestinal obstruction.^{1,2}

PHYSICAL EXAMINATION

The following findings should be analysed in the physical examination of a child with neonatal intestinal obstruction which includes general examination for cry and activity; nature of vomitus or nasogastric tube aspirate; presence of any postnatal complications (predisposing to NNEC or sepsis); abdominal examination for dilated veins, abdominal wall erythema, shiny or tense abdominal wall; hernial orifices and genitalia; anal orifice assessment; gentle per rectal examination with small thermometer or feeding tube, nature of meconium staining and examination of any associated anomaly.

There will be little or no abdominal distension or any abdominal sign in proximal bowel obstruction like malrotation of gut with MGCV or duodenal stenosis or proximal atresia.³ Deterioration can be rapid with extensive bowel ischemia in MGCV. If significant suspicion of intestinal obstruction, proceed with X-ray abdomen erect-(AXR)- neck to knees. A proper radiograph is diagnostic in most cases; assessment of the pattern of gas on AXR aids diagnosis.

Any bilious emesis in a previously well newborn or infant is considered to be malrotation of gut with MGCV, unless proven otherwise. Antenatal sonological finding of polyhydramnios suggests congenital bowel obstruction.⁴ Upper GI contrast study is reserved for partial upper GI obstruction (duodenal stenosis or MGCV) and contrast enema is commonly used for lower GI obstruction [ileal atresia/meconium ileus/Hirschsprung's disease (HD)].^{4,5}

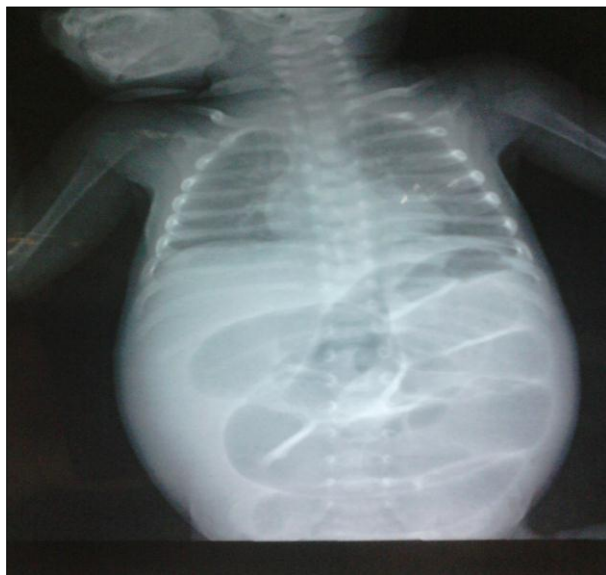

Figure 1: A supine radiograph showing dilated small bowel loops with absent colonic gas in distal small bowel obstruction.

The possible pitfalls include the finding of an otherwise generally well-baby in most of the surgical problems and

the fact that all signs are subtle. There will be little or no abdominal distension or any abdominal sign in proximal bowel obstruction like malrotation of gut with MGCV/duodenal stenosis or proximal atresia.^{4,5} The deterioration in these children can be rapid, especially in conditions like extensive bowel ischemia in MGCV. The diagnosis of distal bowel obstruction rests on proper radiological interpretation (Figure 1).

Differential diagnosis of neonatal intestinal obstruction

- Medical causes include septicemia, metabolic ileus, maternal diabetes mellitus- neonatal small left colon syndrome, maternal hypothyroidism, meconium plug syndrome and NNEC.^{4,5}
- Surgical causes include duodenal atresia or stenosis, malrotation of gut with MGCV, intestinal atresia, meconium peritonitis, meconium ileus, NNEC, congenital band obstruction (most commonly Meckel's band), HD and anorectal malformations.^{5,6}

ASSESSMENT OF THE NEONATE

The general condition and activity of the child gives a clue to possible medical or surgical cause. The physician has to rule out common benign causes like Improper feeding and burping and maternal drug induced ileus by proper interpretation of history (Table 1).

One has to be alert about associated 'red flag' symptoms like bilious vomiting or blood in stools. Systemic complications like dyselectrolytemia or circulatory failure or DIC are more common in NNEC or other medical causes.^{6,7} If significant suspicion of intestinal obstruction, proceed with X-ray abdomen erect (neck to knees).

A proper radiograph is diagnostic in most cases and assessment of the pattern of gas on AXR aids diagnosis. Any bilious emesis in a previously well newborn or infant is considered to be malrotation of gut with MGCV, unless proven otherwise.

The antenatal sonological finding of polyhydramnios suggests congenital bowel obstruction. Upper gastrointestinal contrast study is reserved for partial upper GI obstruction (duodenal stenosis or MGCV) and Contrast enema is used for lower gastrointestinal obstruction (ileal atresia/meconium ileus/ HD).

Interpreting the plain X-ray in Intestinal obstruction of neonate

The gas pattern is assessed to be of uniform nature or if there is paucity of distal gas (suggest obstruction); presence of any dilated loops is assessed. Air-fluid levels (in an erect film) are suggestive of significant obstruction. A supine film gives a clue about the level of obstruction while an erect film confirms the diagnosis of

obstruction. In supine film, level up to which gas is present, suggests the level of obstruction.

The findings of pneumatosis intestinalis and portal venous gas are common in NNEC. Fixed loop sign on

serial radiographs is suggestive of NNEC, Calcification is seen in meconium peritonitis, soap bubble sign in meconium ileus and pneumoperitoneum is seen in complicated intestinal obstruction with perforation (NNEC/HD or atresia or meconium ileus).^{7,8}

Table 1: The classical clinical presentation of various causes of neonatal intestinal obstruction.

Feature	Duodenal atresia	Malrotation of gut with MGTV	Jejunioleal atresia	Meconium ileus	NNEC	HD
Antenatal polyhydramnios	++	-	+	-	-	-
Bilious emesis	++	++	+	+	+	+/-
Delay or non-passage of meconium	+	-	+	+	-	++
Abdominal distension	-	- (Late sign)	+	+	+	++
Timing of presentation	Early	Variable	Early	Early	Beyond first week	Variable
Other features	Duodenal stenosis can present later in life.	Acute onset of symptoms in an otherwise well child.	White meconium may be seen.	Can be complicated or uncomplicated.	Usually sick child.	Non classical types can also occur.

The absence of knee ossification centers suggest hypothyroidism. In non-surgical causes like sepsis, classically; there will be no single dilated loop, no paucity of distal gas, there will be uniformly dilated loops, no large air-fluid levels and no pneumoperitoneum.

Radiological interpretation in individual cases

- Duodenal atresia is characterized by the classical double bubble sign with no distal gas.
- Duodenal stenosis presents with double bubble sign with sparse distal gas.
- Malrotation of gut with MGTV typically has dilated stomach and duodenum with paucity of distal gas and gasless abdomen in progressive stage.
- Jejunioleal atresia shows multiple air-fluid levels with no distal gas (Figure 3).
- Meconium ileus is characterized by dilated small bowel loops, no air fluid levels, soap bubble sign (Neuhauser sign).
- Meconium peritonitis demonstrated the classical 'football' sign (pneumoperitoneum) and calcification.^{8,9}
- In the neonatal small left colon syndrome, X ray findings are similar to HD with contrast enema showing narrow left colon with abrupt change near splenic flexure, with no actual transition zone, which helps distinguish the entity from HD.
- Ileal atresia demonstrates the typical 'unused' microcolon on contrast enema.
- In HD, the X ray showing dilated loops with absent rectal or pelvic gas; contrast enema shows narrow rectum, conical transition at rectosigmoid and dilated proximal colon in the classical HD (Figure 2).

- The total colonic aganglionosis variant of HD shows the classical narrow colon with 'question mark' sign on Contrast enema.^{7,9}

The common clinical situations and the likely diagnosis on the basis of radiological interpretation are narrated below:

- A neonate with early onset bilious vomiting, no abdominal distension, antenatal sonological finding of polyhydramnios and double bubble sign on AXR is likely to have duodenal atresia. There is also a significant association with Down syndrome (Figure 4).
- Any bilious emesis in a previously well newborn or infant is considered to be malrotation of gut with MGTV, unless proven otherwise. Paucity of distal gas with dilated stomach and duodenum on AXR is evidence enough to proceed with emergency surgery. Upper GI contrast study can be done to confirm the diagnosis when the child is stable.
- A neonate with bilious vomiting of delayed onset and paucity of distal gas on AXR, needs an Upper GI contrast study to arrive at a diagnosis of Duodenal stenosis. Malrotation of gut has a very significant association with Duodenal stenosis, and exclusion at surgery is required in each case.
- A neonate with bilious vomiting, abdominal distension, antenatal history of polyhydramnios and multiple air-fluid levels on AXR is likely to have an Intestinal atresia. A jejunal atresia will have fewer proximal loops ('Triple bubble' sign) while ileal atresia will have multiple air-fluid levels. A contrast enema will demonstrate the unused microcolon.

- A neonate with delayed onset bilious emesis, abdominal distension, non-passage of meconium and radiological evidence of distal small bowel obstruction with 'Soap bubble' sign and without air-fluid levels is likely to have Meconium ileus. A contrast enema with water soluble contrast will be diagnostic and even therapeutic in early and uncomplicated cases.
- A neonate with delayed onset bilious emesis, abdominal distension, delayed or non-passage of meconium and radiological evidence of distal colonic obstruction with absent rectal or pelvic gas is likely to have the classical HD. A contrast enema and rectal biopsy will confirm the diagnosis.
- In a neonate with clinical and radiological features of distal small bowel obstruction, three possibilities are ileal atresia, meconium ileus and total colonic aganglionosis variant of HD. A contrast enema will clinch the diagnosis in these cases to guide the appropriate management.^{9,10}
- A pre-term neonate with history of complicated perinatal and postnatal period requiring aggressive medical therapy, who developed features of intestinal obstruction with bilious nasogastric aspirate, abdominal distension, blood in stools and radiological evidence of bowel dilatation and pneumatosis intestinalis, is likely to have NNEC. Presence of portal vein gas, pneumoperitoneum and 'fixed loop' sign demonstrate advanced disease.¹⁰
- A sick newborn with features of systemic sepsis having abdominal distension but radiologic findings of no single dilated loop, no paucity of distal gas, uniformly dilated loops, no large air-fluid levels and no pneumoperitoneum, is likely to have abdominal distension secondary to the sepsis and no surgical pathology.

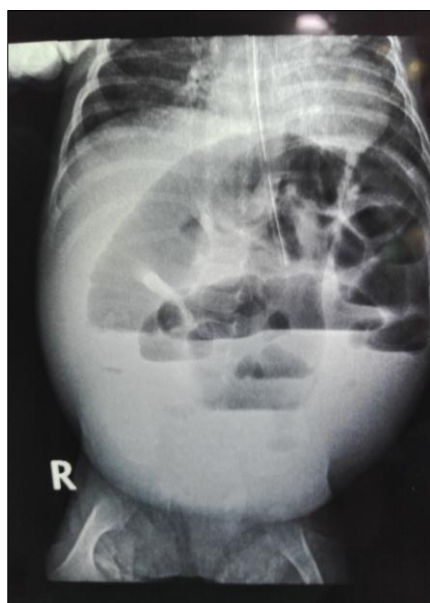


Figure 2: An erect radiograph in a new-born with HD demonstrating dilated bowel and absent pelvic gas.

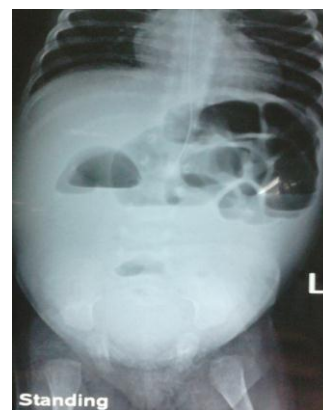

Figure 3: An erect radiograph in a neonate with ileal atresia showing multiple air fluid levels with no gas beyond.

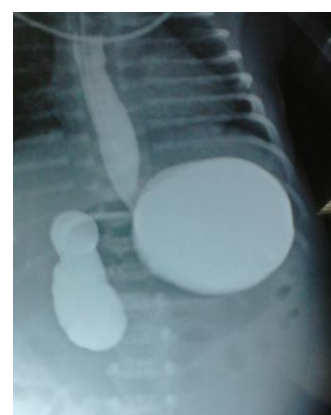


Figure 4: Upper gastrointestinal contrast study in a new-born with antenatal history of polyhydramnios demonstrating duodenal atresia.

DISCUSSION

In the evaluation of a newborn with suspected intestinal obstruction, there is a need for detailed history, thorough physical examination and proper radiological interpretation for arriving at a proper and early diagnosis. While the diagnosis of entities like duodenal atresia or ileal atresia are relatively straightforward, the prompt diagnosis of conditions like malrotation of gut (with MGTV) and HD requires more precise assessment. Exclusion of medical causes like septicemia and hypothyroidism also requires consideration. A systematic and stepwise approach to diagnosis and consideration of all possibilities would help arrive at a prompt and proper diagnosis.

CONCLUSION

The newborn with features of intestinal obstruction poses a diagnostic challenge to the neonatologist and pediatric surgeon. But, the systematic interpretation of history, physical examination, radiograph and contrast imaging in select cases will enable a proper and timely diagnosis.

Funding: No funding sources

Conflict of interest: None declared

Ethical approval: Not required

REFERENCES

1. Juang D, Snyder CL. Neonatal bowel obstruction. *Surgical Clin*. 2012;92(3):685-711.
2. Adams SD, Stanton MP. Malrotation and intestinal atresias. *Early Human Development*. 2014;90(12):921-5.
3. Carroll AG, Kavanagh RG, Ni Leithin C, Cullinan NM, Lavelle LP, Malone DE. Comparative effectiveness of imaging modalities for the diagnosis of intestinal obstruction in neonates and infants: a critically appraised topic. *Acad Radiol*. 2016;23(5):559-68.
4. Reid JR. Practical imaging approach to bowel obstruction in neonates: a review and update. *Semin Roentgenol*. 2012;47(1):21-31.
5. Vinocur DN, Lee EY, Eisenberg RL. Neonatal intestinal obstruction. *Am J Roentgenol*. 2012;198(1):1-0.
6. Schulman M H. Imaging of neonatal gastrointestinal obstruction. *Radiol Clin North Am*. 1999;37:1163-86.
7. Buonomo C. Neonatal gastrointestinal emergencies. *Radiol Clin North Am*. 1997;35:845-64.
8. Berrocal T, Lamas M, Gutierrez J, Torres I, Prieto C, del Hoyo ML. Congenital anomalies of the small intestine, colon, and rectum. *Radiographics*. 1999;19:1219-36.
9. Kiely EM, Puri P. Newborn surgery. Meconium ileus. Oxford: Butterworth-Heinemann; 1996: 324-327.
10. Dillon PW, Cilley RE. Newborn surgical emergencies. Gastrointestinal anomalies, abdominal wall defects. *Pediatr Clin North Am*. 1993;40(6):1289-314.

Cite this article as: Sarma VP, Menon SS. The approach to a neonate with suspected intestinal obstruction : the pediatric surgical perspective. *Int Surg J* 2019;6:4198-202.