

Case Report

Giant abdominal aortic aneurysm treatment with open surgery in a risky patient post CABG with stenotic coronaries

İbrahim Özsöyler, Hakan Özgen, Mahmut Çetinoğlu, Hasan Uncu, Funda Tor Ocak*

Department of Cardiovascular Surgery, Adana Numune Eğitim ve Araştırma Hastanesi, Adana, Turkey

Received: 28 June 2014

Accepted: 20 July 2014

***Correspondence:**

Dr. Funda Tor Ocak,

E-mail: funda_tor@yahoo.com

Copyright: © the author(s), publisher and licensee Medip Academy. This is an open-access article distributed under the terms of the Creative Commons Attribution Non-Commercial License, which permits unrestricted non-commercial use, distribution, and reproduction in any medium, provided the original work is properly cited.

ABSTRACT

A 70 year-old syrian refugee male was admitted with history of a heavy smoking, post operative CABG operation of which 2 years ago with an open RCA graft but LAD %100 proximally plaque stenosis, %90 CX and multiple branch occlusions without angina with normal ejection fraction and normal valve functions. At the angiography no other grafts were observed and no epicrisis was obtained. He could not take any food because of vomiting and lose of weight day by day recently and with complaints of exceeding abdominal discomfort, increasing back pain and physical mobility discomfort in recent months duration. Physical examination revealed a giant, prominently visible, expansile, pulsatile, well-defined, nontender abdominal mass in the whole abdominal area. Computed Tomographic (CT) and angiography revealed a large infrarenal aortic giant aneurysm with a maximum transverse diameter of 13.6 cm without iliac extensions. Anatomy of the aneurysm did not permit Endo-Vascular Aneurysm Repair (EVAR). The patient underwent open surgical inclusion repair using an, aorto-bi-femoral 16 mm × 8 mm collagen-impregnated bifurcated Dacron graft. Postoperative recovery was uncomplicated and he discharged at the 10th day from the hospital with no complaints and with good health. Histopathologic study is non significant.

Keywords: Aortic, Aneurysm, Giant

INTRODUCTION

AAAs (abdominal aortic aneurysms) occur in up to 9% of adults older than 65 years of age. The most important risk factors for the development of AAA are smoking, male sex, and advancing age.¹ Aneurysm size is the strongest predictor of the risk of rupture with 30% to 50% annual risk of rupture for AAAs >8.0 cm in size, and there may be a high risk of AAA rupture after coronary artery bypass grafting or other major surgeries.^{2,3} According to the United States preventive services task force, men who are at the ages 65 to 75 with a history of smoking should be screened one time for AAA by abdominal ultrasonography.⁴

CASE REPORT

A 70 year-old syrian refugee male was admitted with history of heavy smoking, CABG operation was 2 years ago. He could not take any food because of vomiting and lose of weight day by day recently and with complaints of exceeding abdominal discomfort, increasing back pain and physical mobility discomfort in recent months duration. Physical examination revealed a giant, prominently visible, expansile, pulsatile, well-defined, nontender abdominal mass in the whole abdominal area. Bilateral femoral pulses were intact. He was hypertensive with cardiac sinus rhythm. There was no evidence of valve pathology in echocardiographic measurements. Ejection fraction was normal. Computed Tomographic (CT) and

angiography revealed a large infrarenal aortic giant aneurysm with a maximum transverse diameter of 136 mm without iliac extensions. Infra renal neck diameter was 28 mm and 26 mm in length (Figure 1).

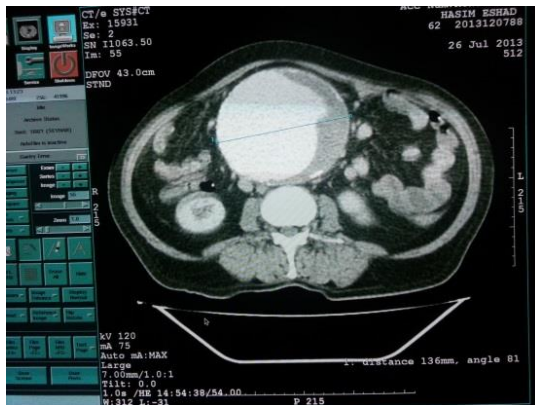

Figure 1: Preoperative CT imagine.

Coronary angiogram was planned to determine the condition of coronary arteries and whether the grafts are intact. Angiogram resulted with an open RCA graft but %100 LAD proximally plaque stenosis, %90 CX and multiple branches occlusions without angina and no other grafts were observed and no epicrisis was obtained. Laboratory findings were normal and no other problem coincided with. But clinically patient was in a very distressed position because of the abdominal mass. He was not able to eat, walk and move comfortably and losing weight day by day. An immediate open surgical intervention was planned by using an aorto-bi-femoral 16 mm × 8 mm collagen-impregnated bifurcated Dacron graft. After patient taken into surgery room under general anesthesia both femoral area was prepared. Both sided femoral arteries were pulsatile and intact. Abdomen was opened and giant aortic aneurysm dissected (Figure 2).

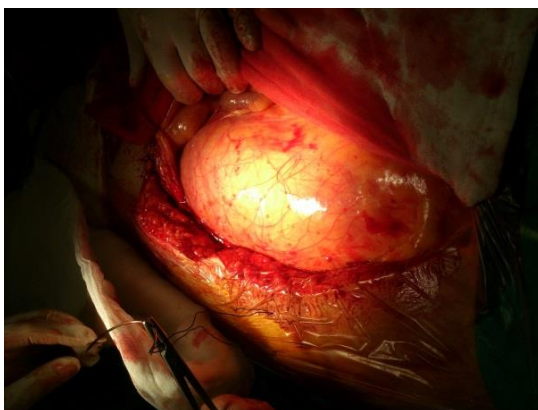


Figure 2: Peroperative giant abdominal aorta.

Neck was found and clamped from the left side with satinsky klempe. After opening aorta blood and thrombus was removed, lumbar arteries sutured inguinal arteries tied and proximal side of the graft sutured with 3/0 prolene to the aorta and clamp removed distally. Distal

legs of the graft were tunneled to the femoral arteries and subsequently intervened. After obtaining distal pulses and hemorrhage control operation ended uneventfully. Postoperative recovery was uncomplicated and he discharged from cardiovascular surgery service on the 10th day with no complaints in good health (Figure 3). Histopathologic study was clear.

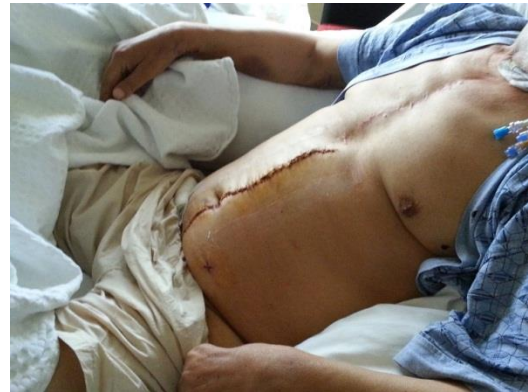

Figure 3: Postoperative imagine.

DISCUSSION

The combination of modern surgical technique, improved anesthetic management, and sophisticated monitoring has undoubtedly contributed to a lowering of the operative mortality associated with AAA repair. Aneurysm repair poses a significant stress of the myocardium, which may be accentuated by the presence of CAD. In an attempt to minimize cardiac causes of operative mortality, Hertzner has recommended routine coronary and angiography for all patients prior to AAA repair.⁵ As pointed out by Goldman, routine coronary angiography is not indicated for patients with stable angina because the risks of catheterization and CABG may be greater than the risk of undergoing a noncardiac surgical procedure.⁶

Funding: No funding sources

Conflict of interest: None declared

Ethical approval: Not required

REFERENCES

1. Baxter BT, Terrin MC, Dalman RL. Medical management of small abdominal aortic aneurysms. *Circulation*. 2008;117(14):1883-9.
2. Brewster DC, Cronenwett JL, Hallett JW Jr, Johnston KW, Krupski WC, Matsumura JS, et al. Guidelines for the treatment of abdominal aortic aneurysms. Report of a subcommittee of the joint council of the American association for vascular surgery and society for vascular surgery. *J Vasc Surg*. 2003;37(5):1106-17.
3. Blackbourne LH, Tribble CG, Langenburg SE, Mauney MC, Buchanan SA, Sinclair KN, et al. Optimal timing of abdominal aortic aneurysm repair after coronary artery revascularization. *Ann Surg*. 1994;219(6):693-6.

4. U.S. Preventive Services Task Force. Screening for abdominal aortic aneurysm: recommendation statement. *Ann Intern Med.* 2005;142:198-202.
5. Hertzner N. Fatal myocardial infarction following abdominal aortic aneurysm resection. *Ann Surg.* 1980;192(5):667-73.
6. Goldman L. Cardiac risks and complications of non-cardiac surgery. *Ann Surg.* 1983;198(6):780-91.

DOI: 10.5455/2349-2902.isj20140809

Cite this article as: Özsöyler İ, Özgen H, Çetinoğlu M, Uncu H, Ocak FT. Giant abdominal aortic aneurysm treatment with open surgery in a risky patient post CABG with stenotic coronaries. *Int Surg J* 2014;1:88-90.