

## Case Report

# Spindle cell tumor presenting as RIF mass

**Thakut Gowtham\***, Sheetal Ashok Murchite, Vaishali Vinayak Gaikwad,  
Abhay D. Chougale, Rakesh Kumar Ranjan, Vishwas Thimmegowda

Department of Surgery, Dr D Y Patil Medical College and Hospital Research Center, Kolhapur, Maharashtra, India

**Received:** 23 April 2019

**Revised:** 06 July 2019

**Accepted:** 08 July 2019

### \*Correspondence:

Dr. Thakut Gowtham,

E-mail: [gowtham887@gmail.com](mailto:gowtham887@gmail.com)

**Copyright:** © the author(s), publisher and licensee Medip Academy. This is an open-access article distributed under the terms of the Creative Commons Attribution Non-Commercial License, which permits unrestricted non-commercial use, distribution, and reproduction in any medium, provided the original work is properly cited.

### ABSTRACT

Spindle cell sarcoma is a rare tumor that arises most commonly from the peripheral and deep soft tissues. It usually occurs in the extremities but rarely present as a large abdominal mass, and in this case it was a recurrent tumor involving whole of rectus muscle on right side. We report the case of a 42 year old male who presented with abdominal swelling and distention. CT scan showed a mass occupying the whole of the abdomen and pelvis. Exploration of abdomen revealed a hard mass about 13×10×11 cm in size. Complete excision was done, the huge defect was closed by transposition of left side rectus abdominus muscle with prolene mesh, which was a challenging task in this case. On histopathology and immunochemistry a high grade spindle cell carcinoma was confirmed.

**Keywords:** RIF mass, Spindle cell sarcoma, Transposition flap, Immunochemistry

### INTRODUCTION

Spindle cell tumours are low grade fibromyxoid soft tissue sarcoma (LGFMS). The name is descriptive of its microscopic appearance with features of both mesenchymal and neuroendocrine differentiation. Cytogenetic studies of spindle cell tumour show two cell lines containing balanced trans-location between chromosomes 7 and 16.<sup>1</sup> A small subset of both LGFMS and hyalinizing spindle tumour (HSCT) displays areas of increased cellularity and atypical which qualify as intermediate to high grade sarcoma.<sup>2</sup> Spindle cell carcinomas are rare presentation in the esophagus as well.<sup>3</sup> These tumors rarely metastasized, but pulmonary and lymph nodes metastases are reported in the literature.<sup>4,5</sup>

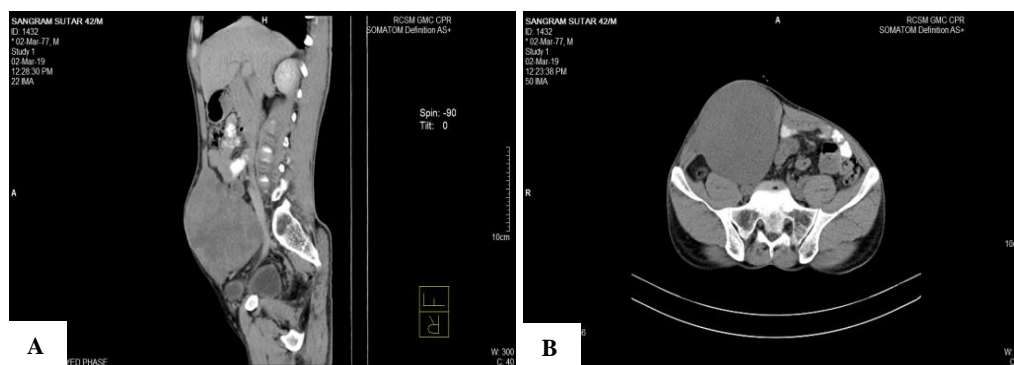
### CASE REPORT

A case of 42-year-old male, labourer by occupation, presented through the outpatient department with 9 years history of abdominal swelling and distention, weight loss

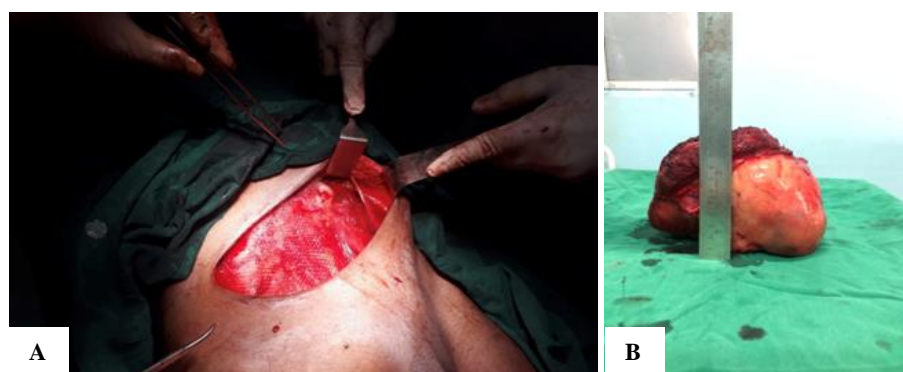
and intermittent constipation. His vitals were within normal limits. Patient had an similar history of RIF mass excision in 2009. On examination, abdomen was distended, dilated veins on right lower quadrant of abdomen with a hard non-tender mass almost occupying the whole of the abdomen measuring 13×10×11 cm reaching up to the pelvis with smooth surface. Ultrasound showed a well defined heterogeneously hypo-echoic lesion measuring 11×11×9 cm abdomino-pelvic lesion in RIF. CT scan showed a heterogeneous soft tissue mass occupying the whole of abdomen and pelvis 10.2×12×13 cm in size. Posteriorly the mass was seen indenting and displacing the large bowel loops with maintained fat planes. The mass was reported most likely to be a neoplastic lesion. Elliptical incision was taken over the maximum prominent point of swelling which showed a 13×10×11 cm mass in the abdominal cavity and extending in to the pelvis. It was smooth in surface and globular in shape (Figure 2) mass was separated from surrounding structures by sharp dissection, and excised completely. Rectus abdominis muscle is cut around the tumor, leaving a defect of 13×13 cm, peritoneum was

closed and 15×15 cm prolene mesh was placed over it (Figure 2) and fixed. The left rectus abdominus muscle transected 3cm above the umbilicus, this muscle is transpositioned to right side to cover the mesh and fixed

as transposition flap. The tumor had to be meticulously dissected away from the small bowel and omentum at the same time achieving adequate hemostasis. Weight of the mass was 1.7 kg, measured after the operation.



**Figure 1 (A and B): CT scan showing heterogeneous mass.**



**Figure 2 (A and B): The mesh placement and specimen.**

Histopathology confirmed the diagnosis of recurrent spindle cell tumour undifferentiated pleomorphic sarcoma (rt.ilic fossa).

On cut section the tumour is well encapsulated, grey white and shows whorled and lobulated appearance. Focal cystic areas noted. This mass was approximately 20×15×9 cm in size smooth in surface and globular in shape. Mass was separated from the surrounding structure and excised completely. Postoperative follow-up in the ward was uneventful except draining about 70-100 ml serosanguinous fluid daily through the drain up to 7 days.

## DISCUSSION

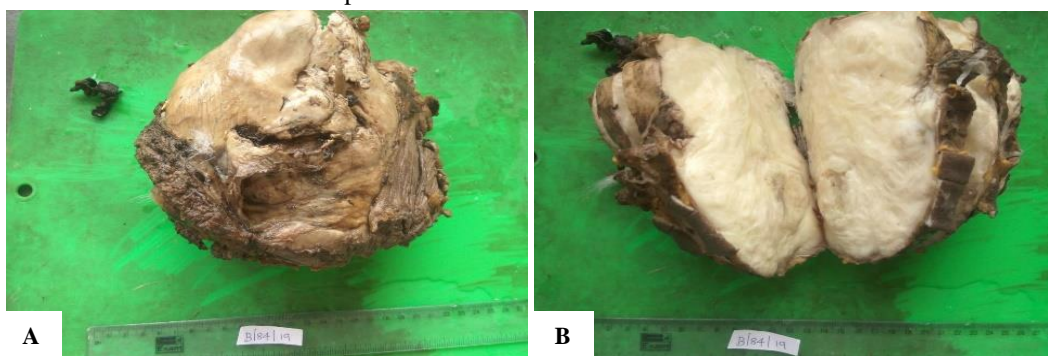
Spindle cell sarcoma is a type of connective tissue cancer in which the cells are spindle-shaped when examined microscopically Spindle cell sarcoma is a rare cause of large abdominal mass.<sup>6</sup> Cytological diagnosis of spindle cell tumor is difficult as compared to other soft tissue tumors.<sup>7</sup> These tumors generally begin in layers of connective tissue such as that under the skin, between muscles, and surrounding organs, and will generally start as a small lump that grows gradually.

At first the lump is self-contained as the tumor exists in earlier stages, and will not necessarily expand beyond its encapsulated form. However, it may develop malignant processes that can only be detected through microscopic examination. As such, at this level the tumor is usually treated by excision that includes wide margins through healthy-looking tissue, followed by thorough biopsy and additional excision if necessary. In high grade lesions, prognosis is grim and chemotherapy and radiation are the only methods of controlling the cancer.

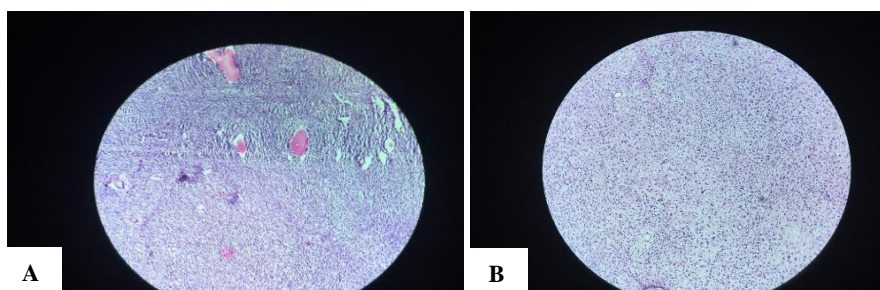
Spindle cell sarcoma can develop for a variety of reasons, including genetic predisposition but it also may be caused by a combination of other factors including injury and inflammation in patients that are already thought to be predisposed to such tumors. Spindle cell tumors are usually diagnosed on histopathology based on picture comprising of elongated spindle cells arranged in interlacing fascicles and bundles with herring bone pattern at places. These bundles intersect each other at wide angles at places showing storiform pattern with eosinophilic cytoplasm and cigar shaped nuclei (Figure 4). Occasionally ghost cells in the center and multinucleated giant cell may present, grading is suggested in soft tissue sarcoma in order to improve the management, prognosis and to prevent the recurrence,

based on nuclear atypia, nuclear overlap, mitotic figures, and necrosis these tumors are given grades.<sup>8,9</sup> Treatment of spindle cell tumor is its complete excision.<sup>10</sup> Radiotherapy has minimal in the abdomen was a rare case. The size upto which it

progressed posed a great challenge during surgery as the tumor mass was hard and friable, the tumor had to be meticulously dissected away from the small bowel and omentum at the same time achieving adequate hemostasis.



**Figure 3: (A) Gross; (B) gross cut section.**



**Figure 4 (A and B): Histopathology showing Storiform pattern.**

#### **Declaration of patient consent**

The authors certify that they have obtained all appropriate patient consent forms. In the form, the patient has given his consent for his images and other clinical information to be reported in the journal. The patients understand that name and initials will not be published and due efforts will be made to conceal identity, but anonymity cannot be guaranteed.

#### **CONCLUSION**

Spindle cell tumor involving anterior abdominal wall muscle is a rare entity, can be treated by resection and reconstruction with opposite rectus abdominis muscle, with additional support of prolene mesh. Abdominal wall support is maintained by opposite internal oblique and transverse abdominis muscle

#### **ACKNOWLEDGEMENTS**

I would like to thank my parents, department, my teachers for their constant support in drafting this unusual case report.

*Funding: No funding sources*

*Conflict of interest: None declared*

*Ethical approval: Not required*

#### **REFERENCES**

1. Reid R, de Silva MV, Paterson L, Ryan E, Fisher C. Low grade fibromyxoid sarcoma and hyalinizing spindle cell tumor with giant rosettes share a common t(7;16)(q 34;p11) translocation. Am J Surg Pathol. 2003;27:1229-36.
2. Yang S, Liu C, Chai C, Chien S, Wang C. Hyalinizing spindle cell tumor with giant rosettes: a case report. Kaohsiung J Med Sci. 2009;25:583-6.
3. Yakoob J, Abbas Z, Jaffery W, Azad SN. Esophageal polypoidal mass: presentation of an uncommon pleomorphic carcinoma. J Pak Med Assoc. 2009;59:756-9.
4. O Sulvian MJ, Sirgi KE, Dehner LP. Low grade fibrosarcoma (Hyalinizing spindle cell tumour with giant rosettes) with pulmonary metastases at presentation: case report and review of the literature. Intern J Surg Pathol. 2002;10:211-6.
5. Loya A, Prayaga AK, Arora A, Sundaram C, Rao SI, Uppin SG, et al. Lymph node metastasis of soft tissue tumours: a cytomorphologic study. Acta Cytol. 2007;51:153-160.
6. Bills V, Iqbal R, Haqqani M, Clague JE. Spindle cell sarcoma: a rare cause of a large abdominal mass. Age Ageing. 2005;34:88-9.

7. Prayaga A. Cytology of soft tissue tumours: Malignant spindle cell tumours. *J Cytol.* 2008;25:87-8.
8. Mathur S, Kapila K, Verma K. Accuracy of cytologic grading of spindle cell sarcomas. *Diagn Cytopathol.* 2003;29:79-83.
9. Jones C, Liu K, Hirschowitz S, Klipfel N, Layfield LJ. Concordance of histopathologic and cytologic grading in musculoskeletal sarcomas; Can grade obtained from analysis of fine needle aspirates serve as the basis for the therapeutic decisions? *Cancer.* 2002;96:83-91.
10. Fras AP, Grazio SAF. Hyalinizing spindle cell tumour with giant rosettes of the broad ligament. *Gynecologic Oncol.* 2001;83:405-8.

**Cite this article as:** Gowtham T, Murchite SA, Gaikwad VV, Chougale AD, Ranjan RK, Thimmegowda V. Spindle cell tumor presenting as RIF mass. *Int Surg J* 2019;6:2955-8.