

Case Report

Parathyroid microadenoma as a cause of chronic intractable cough

Deepak K. Diwakar¹, Nikita Wadhvani^{1*}, Nisha Rana², Shivani Paruthy¹

¹Department of General Surgery, ²Department of Pathology, Vardhman Mahavir Medical College and Safdarjung Hospital, New Delhi, India

Received: 06 April 2019

Accepted: 18 May 2019

***Correspondence:**

Dr. Nikita Wadhvani,

E-mail: nikiw3012@gmail.com

Copyright: © the author(s), publisher and licensee Medip Academy. This is an open-access article distributed under the terms of the Creative Commons Attribution Non-Commercial License, which permits unrestricted non-commercial use, distribution, and reproduction in any medium, provided the original work is properly cited.

ABSTRACT

Chronic non-productive cough is one of the most common non-specific symptom with multiple etiologies and is treated non-surgically. Rarely, it can be caused by anatomical causes. We present a case of parathyroid microadenoma presenting with chronic intractable cough and dysphagia, diagnosed after a battery of tests and failed treatments and cured by a simple parathyroidectomy.

Keywords: Endocrine surgery, Chronic cough, Parathyroid adenoma

INTRODUCTION

Primary hyperparathyroidism is most commonly caused by parathyroid adenoma. Most cases are asymptomatic or have non-specific symptoms. Infrequently, parathyroid adenomas can present with symptoms due to pressure effect on surrounding structures and are usually characteristic of giant adenomas i.e. weight ≥ 3 grams.¹ We present a rare case of chronic cough caused by the adenoma, weighing merely 2 grams, due to anatomic proximity to recurrent laryngeal nerve and was treated surgically.

CASE REPORT

67 year old woman presented to the outpatient department with complaints of chronic cough and dysphagia. She developed dry cough 1.5 years ago insidiously with a gradually progressive course. It was not relieved by over the counter medications and was troublesome for her. Dysphagia was present for the solids for the past 6 months, causing uncomfortable sensation in her neck. However, her appetite was normal. There was no history of fever, dyspnea, loss of weight, change in

voice, palpitations, heat intolerance, abdominal pain and genitourinary complaints.

Her medical history was significant for hypertension for which she was on calcium channel blocker and thiazide therapy. She had no history of tuberculosis, asthma or any prior surgical interventions. She had received a course of antibiotics for possible atypical pneumonia, which did not improve her symptoms. She is non-smoker and non-alcoholic.

On examination of her neck, there was no swelling seen or palpable. Ear, nose and throat examination revealed normal findings. There was no cervical lymphadenopathy. Rest of the systemic examination was normal.

Complete blood count (CBC), kidney function test (KFT) and liver function test (LFT) were within normal limits. Chest X-ray was normal. Barium swallow, ordered in view of dysphagia and revealed normal findings.

She was prescribed proton pump inhibitors, due to possible gastro-esophageal reflux, for 2 weeks, which

failed to provide relief. Thereafter, Contrast Enhanced Computed Tomography (CECT) chest and neck was ordered which revealed a well defined 12×13.8×17.2 mm oval enhancing lesion in right inferior tracheo-esophageal groove behind thyroid parenchyma, suggestive of parathyroid adenoma. This was followed up by thyroid function tests and parathyroid hormone assay. Thyroid profile was within normal limits. However, PTH levels were raised (-387 pg/ml). Serum Calcium levels were slightly raised (-11.1 mg/dl).

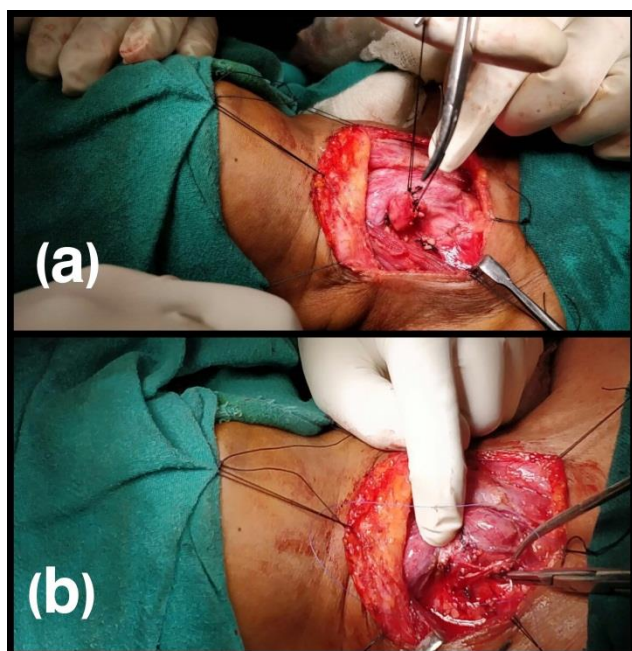


Figure 1: (a) Right inferior parathyroid adenoma posterior to right lobe of thyroid and compressing the right recurrent laryngeal nerve; (b) recurrent Laryngeal Nerve seen on the base after removal of parathyroid adenoma.

Following this, she was referred to the department of Surgery. Signs and symptoms of hypercalcemia were ruled out-No abdominal / genitourinary / cardiac / neurological complaints were present. USG of abdomen and pelvis was within normal limits. Bone Mineral Density was normal for age and sex. ECG and echocardiography was normal. Sestamibi scan showed visualization of right inferior parathyroid adenoma. After careful review of her records, parathyroid adenoma was diagnosed as the possible cause of her cough, due to pressure effect on surrounding structures. Surgery was decided as the plan of action following informed consent from the patient.

Right inferior parathyroidectomy was performed. An enlarged right inferior parathyroid gland was present posterior to right lobe of thyroid and compressing the right recurrent laryngeal nerve, running directly inferior to the adenoma (Figure 1a). The adenoma (Figure 1b) was carefully dissected while preserving the recurrent laryngeal nerve (Figure 2a). This was followed by exploration and preservation of other parathyroids and

adequate vascular control was secured. PTH levels were drawn within 10 mins of excision of adenoma and showed a 91% reduction from preoperative baseline (-34 pg/ml).

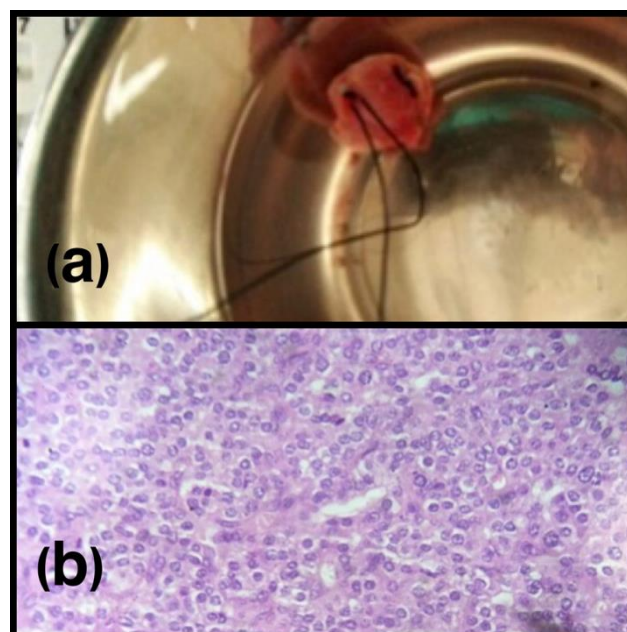


Figure 2: (a) Pathological assessment of the adenoma specimen revealed a 1.6×0.6×0.2 cm mass weighing 2 grams and grey-white cut surface with (b) features of parathyroid adenoma on histology.

Pathological assessment of the adenoma specimen revealed a 1.6×0.6×0.2 cm mass weighing 2 grams and features of parathyroid adenoma on histology (Figure 2b). Post-operatively, serum calcium levels were monitored. Mild hoarseness in voice was appreciable on Post Operative Day (POD)-2. She was discharged on POD 4. At one month follow-up, she had no complaints of cough or hoarseness. She remains asymptomatic after 4 months of surgery.

DISCUSSION

Primary hyperparathyroidism has an annual incidence of 0.2% in patients >60 years, with an estimated prevalence, including undiscovered asymptomatic patients, of ≥1%.² Primary hyperparathyroidism is more common in elderly women with a female to male ratio of 3-4:1.¹ Eighty to 85 percent of primary hyperparathyroidism is caused by parathyroid adenoma.³

Patients with primary hyperparathyroidism may present with clinical evidence of elevated serum calcium levels which include non-specific symptoms such as fatigue, pain and weakness as well as polydipsia, polyuria, nephrolithiasis and gastrointestinal symptoms like constipation, nausea, and vomiting.³

Asymptomatic primary hyperparathyroidism is the most prevalent form of the disease and is defined as biochemically confirmed hyperparathyroidism with the absence of signs and symptoms typically associated with more severe hyperparathyroidism such as features of renal or bone disease.² Despite high PTH levels, our patient did not have classical symptoms, which was confirmed with bone mineral density assessment, renal ultrasound and KFT along with clinical assessment.

Infrequently, parathyroid adenomas can present with rare symptoms due to pressure effect on surrounding structures, e.g. esophagus causing dysphagia or trachea causing dyspnea or chronic cough due to pressure on recurrent laryngeal nerve, in present case. These symptoms are usually characteristic of giant adenomas weighing more than 3 grams, due to their large size.⁴ However, the rare presentation of chronic dry cough caused by the adenoma, weighing 2 grams, in our patient was because of pressure on recurrent laryngeal nerve due to anatomic proximity. Due to an uncommon cause, our patient underwent various tests and treatments. Therefore, sensory neuropathy of the recurrent laryngeal nerve or superior laryngeal nerve should be considered in the workup for chronic cough.⁵

Surgical excision of the abnormal parathyroid tissue is the definitive therapy for this disease. Medical surveillance without operation can be preferred for patients with mild, asymptomatic disease, especially elderly.² In present case, patient had intractable cough that impaired her quality of life and was, therefore, taken for surgery.

Post-operative period should be monitored for hypocalcemia. Because of intra-operative handling of recurrent laryngeal nerve, our patient had mild hoarseness following surgery but recovered soon along with resolution of her cough. In conclusion, one should keep anatomical causes in mind as a cause of chronic intractable cough, especially with history of failed treatments.

In conclusion, anatomical causes should be kept in mind when evaluating chronic intractable cough, especially

with history of failure of various treatment. Infrequently, parathyroid adenomas can present with rare signs and symptoms due to pressure effect on surrounding structures, e.g. esophagus causing dysphagia or trachea causing dyspnea or chronic cough due to pressure on recurrent laryngeal nerve. These symptoms are usually characteristic of giant adenomas, parathyroid adenomas weighing more than 3 grams. However, they can be caused by smaller adenomas depending on the anatomy. Surgical excision, i.e. parathyroidectomy is the definitive treatment for such cough.

Funding: No funding sources

Conflict of interest: None declared

Ethical approval: Not required

REFERENCES

1. Bringham FR, Demay MB, Krane SM, Kronenberg HM. Bone and mineral metabolism in Health and Disease In: Kasper D, Fauci A, Hauser S, Longo D, Jameson J, Loscalzo J, eds. Harrison's Principles of Internal Medicine. 19th ed. Vol 2. Philadelphia: McGraw-Hill Education; 2015.
2. Araujo Castro M, López AA, Fragueiro LM, García NP. Giant parathyroid adenoma: differential aspects compared to parathyroid carcinoma. *Endocrinol Diabetes Metab Case Rep.* 2017;2017:17-41.
3. Kumar SN. 2015. Atypical presentation of a giant parathyroid adenoma: a case report. *Intern J Curr Res.* 2015;7(7):18462-4.
4. Wieneke JA, Smith A. Parathyroid Adenoma. *Head Neck Pathol.* 2008;2(4):305-8.
5. Quinn CE, Udelsman R. The Parathyroid Glands. In: Townsend M, Beauchamp DR, Evers MB, Mattox KL eds. *Sabiston Textbook of Surgery: the biological basis of modern surgical practice.* 20th ed. Philadelphia: Elsevier; 2017: 931-966.

Cite this article as: Diwakar DK, Wadhvani N, Rana N, Parathy S. Parathyroid microadenoma as a cause of chronic intractable cough. *Int Surg J* 2019;6:2228-30.