

Case Report

Lymphangioma an unusual adult scrotal lump: case report and review

Irpatgire Ravindra*, Kale Dinkar, Warad B. S.

Department of General Surgery, MIMSR Medical College, Latur, Maharashtra, India

Received: 03 August 2016

Accepted: 03 September 2016

***Correspondence:**

Dr. Irpatgire Ravindra,

E-mail: rirpatgire@rediffmail.com

Copyright: © the author(s), publisher and licensee Medip Academy. This is an open-access article distributed under the terms of the Creative Commons Attribution Non-Commercial License, which permits unrestricted non-commercial use, distribution, and reproduction in any medium, provided the original work is properly cited.

ABSTRACT

Cystic lymphangiomas are congenital lymphatic malformations that most commonly develop in the neck, axilla, mediastinum and retroperitoneum. They occur usually in children but occasionally in adults. The scrotum is a very rare site for this tumor and only few cases have been reported in the literature. We report the case of a scrotal lymphangioma in a 24-year-old male patient who developed painless scrotal swelling. Typical sonography and MRI findings are shown. Surgical excision and histopathology confirmed the diagnosis.

Keywords: Cystic lymphangioma, Hydrocele, Lymphatic malformation, Scrotum

INTRODUCTION

Lymphangiomas are malformations of the lymphatic system characterized by lesions that are thin-walled cysts. These cysts can be macroscopic, as in a cystic hygroma, or microscopic. Lymphangiomas are the result of the failure of lymphatic drainage from sequestered lymphatic channels. They are classified into i) capillary - characteristically located in the epidermis. ii) cavernous - composed of dilated lymphatic channels; cavernous lymphangiomas characteristically invade surrounding tissues. iii) cystic hygromas - large, macrocystic lymphangiomas filled with straw-colored, protein-rich fluid.

Cystic hygromas commonly seen in the neck (75%) and axilla (20%), with the remaining 5% found in rare sites such as the mediastinum, retroperitoneum, kidney, colon, bone, liver, spleen and scrotum.¹ The scrotum is a very rare site for lymphangioma and only few cases have been reported in the literature.^{2,3} Scrotal lymphangioma usually presents as cystic scrotal mass. They are frequently misdiagnosed on clinical examination as hydrocele, haematocele, varicocele, inguinal hernia we report a case of lymphangioma of the scrotum in an adult who presented with huge painless scrotal swelling.

CASE REPORT

A 24-year-old young male presented with gradually increasing, painless, soft swelling in the left side of scrotum since 3-4 years with no other complaints. No history of trauma. Clinical examination revealed a large nontender, extra testicular, soft swelling with slight compressibility.

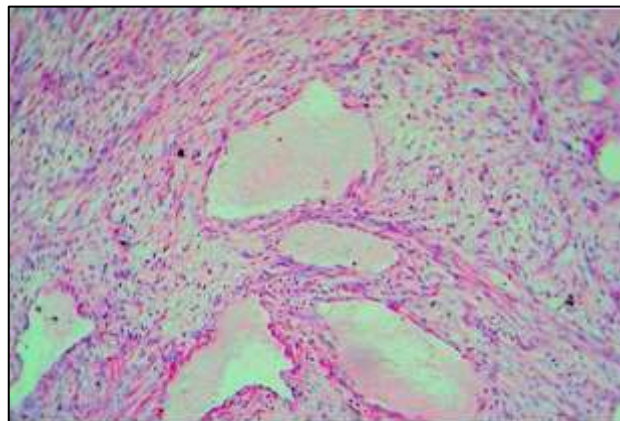


Figure 1: MRI image of lymphangioma, separated from testis.

Ultrasonography of scrotum revealed a well defined, compressible, cystic mass with multiple septae and locules located in the left scrotal sac. MRI of the scrotum revealed low intensity by T1WI and high intensity by T2WI, suggesting a protein-rich component lesion suspicious of lymphangioma which is separate from the normal appearing testis and epididymis (Figure 1).

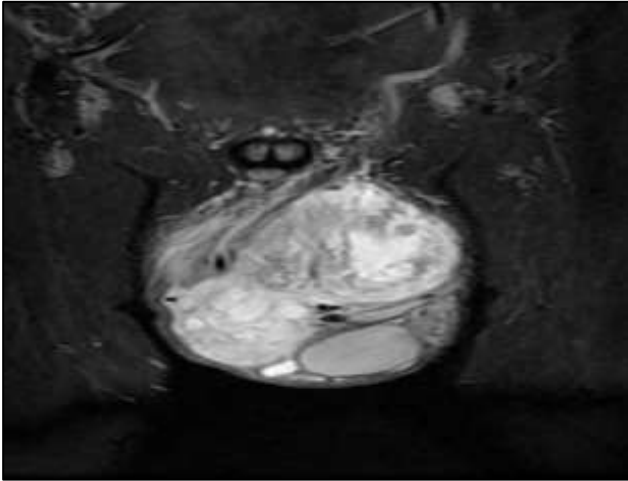


Figure 2: Intraoperative image of lymphangioma separated from testis.

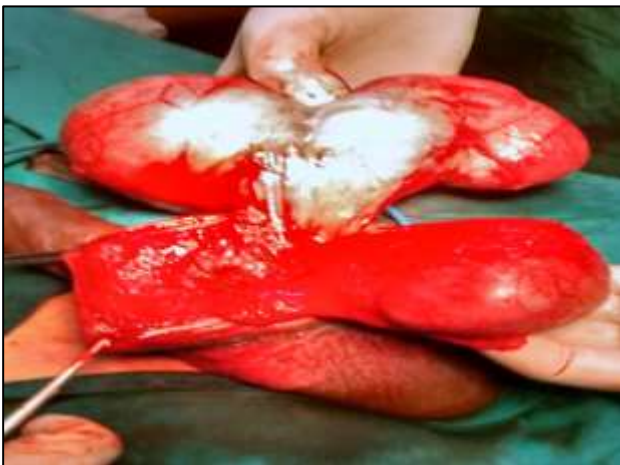

Figure 3: Microscopic section showing dilated lymphatic spaces some filled with eosinophilic lymph fluid separated by fibrous septa. Some septa show lymphoid aggregates.

Laboratory tests were within normal limits. Surgical exploration was performed via a left inguinal incision revealed a large cystic mass with multiple septae located in the left scrotal sac, densely adherent to the tunica but easily separable from the left testis and epididymis (Figure 2). Complete excision of the mass was performed. Postoperative period was uneventful. Histopathology examination confirms the diagnosis of a cystic lymphangioma. On the section, the tissue was spongy and extruded minimal lymph like fluid. Microscopically, the tissue comprised numerous

cavernous spaces lined by a single layer endothelium. The intervening stroma consisted of nondescript loose connective tissue. No evidence of inflammatory infiltrate or cellular atypia was seen (Figure 3). Eight months follow-up period was unremarkable.

DISCUSSION

Intra-scrotal cystic lymphangioma is a rare intra-scrotal mass. Cystic lymphangiomas of scrotum are congenital lymphatic malformations of unknown etiology. Lymphangioma occurs as a result of the failure of lymph to drain from sequestered lymphatic vessels with consequent dilatation of the ducts and formation of a cystic, multiseptate mass. Majority of the lesions are congenital but may also occur secondary to infection, inflammation or degeneration 50% lymphangiomas present at birth and 90% of them are developed by first 2 years of life.³ They have no sex predilection. Out of the three forms, capillary, cavernous and cystic varieties, the cystic are the commonest.⁴ Lymphangiomas most commonly occurs in the neck (75%) or axilla (20%) and remaining 5% are seen in mediastinum, retroperitoneum, mesentery, bone and thighs.¹ Perineal and Scrotum region are the least common sites. Hurwitz et al. reviewed the literature on scrotal lymphangioma and estimated that around 40 cases have been reported. Additionally, they reported 7 more cases with scrotal lymphangioma treated in 5 institutions over a 12 years duration.⁵ Loberant et al estimated that less than fifty cases of scrotal cystic lymphangioma have been reported in literature till 2002.⁶ Yasir S. Jamal reviewed the literature up to 2008 and found 7 more cases.⁷

These lesions usually present as painless scrotal masses which progressively enlarges over time but may sometimes be associated with acute scrotum due to sudden rapid enlargement. This occurs following infection or internal hemorrhage within cyst.⁸ They are commonly mistaken for other common and uncommon extratesticular condition such as a hernia, hydrocele, varicocele, spermatocele, lipoma and dermoid of the spermatic cord, hydatid of morgagni which may result in incomplete therapy with a risk of recurrence. Although benign, they are frequently infiltrative. They may arise in the scrotum or extend into or from the retroperitoneum, perineum, or abdominal wall.^{9,10}

Clinical diagnosis is easier if lymphangioma is present in usual locations but imaging is useful in diagnosis at uncommon and rare locations; especially in the scrotum. Ultrasound is the first choice of diagnostic imaging. It is useful in differentiating solid versus cystic lesions, to confirm origin, and to define the extent of disease. Lymphangiomas have been classically described as lobulated, multicystic, multiseptated, or multilocular masses.^{2,3,5} CT and MRI are more useful to define the important features like, the extent of the lymphangioma and its relations to adjacent soft tissue, muscle and vascular structure.^{2,3} This is useful in planning the

appropriate approach for the complete surgical excision to avoid the recurrence which commonly due to incomplete excision.

Complete surgical excision is the treatment of choice for scrotal lymphangioma. Incomplete excision can result in recurrence. Spontaneous regression is infrequent.¹¹ Treatment modalities like injection of sclerosing agents, cryotherapy and fulguration for cystic lymphangioma are tried but they are associated with high recurrence rates.¹¹ In adult longstanding cases complete orchidectomy may be indicated. In such cases infection and fibrosis make the lesion inseparable which results in incomplete excision and recurrence.¹²

CONCLUSION

Although scrotal cystic lymphangioma are rare, it should be included in the list of differential diagnosis of benign appearing painless multiloculated extratesticular lesions in a young male. Ultrasound is the initial choice of diagnostic imaging. CT and MRI are important in defining extent and relations with surrounding structures. Complete surgical excision is mandatory as incomplete excision results in recurrence. Accurate diagnosis of this disease pre-operatively is necessary for planning of appropriate treatment.

Funding: No funding sources

Conflict of interest: None declared

Ethical approval: Not required

REFERENCES

1. Mosca RC, Pereira GA, Mantesso A. Cystic hygroma: characterization by computerized tomography. Oral Surg Oral Med Oral Pathol Oral Radiol Endod. 2008;105(5):65-9.
2. Mingorance AM, Tello SLC, Casado SCJ, Mendias JC, Meca S. Scrotal lymphangioma in children. Urol Int. 1998;61:181-2.
3. Hamada Y, Yagi K, Tanano A, Kato Y, Takada K, Sato M, Hioki K. Cystic Lymphangioma of the scrotum. Pediatr Surg Int. 1998;13:442-4.
4. Vikicevic J, Milobratovic D, Vukadinovic V, Golubovic Z, Krstic Z. Lymphangioma scroti. Pediatr Dermatol. 2007;24:654-6.
5. Hurwitz RS, Shapiro E, Hulbert WC, Diamond DA, Casale AJ, Rink RC. Scrotal cystic lymphangioma: the misdiagnosed scrotal mass. J Urol. 1997;158:1182-5.
6. Loberant N, Chernihovski A, Goldfeld M. Role of doppler sonography in the diagnosis of cystic lymphangioma of the scrotum. J Clin Ultrasound. 2002;30:384-7.
7. Jamal YS, Halim AR, Moshref SS, Kurdi MO, Sandugji HI. Cystic lymphangiomas of spermatic cord: a case report and literature review. JKAU Med Sci. 2009;16:103-111.
8. Weidman ER, Cerdrón M, Schned AR, Harris RD. Scrotal lymphangioma: an uncommon cause for a scrotal mass. J Ultrasound Med. 2002;21:669-72.
9. Budhiraja S, Rattan KN, Gupta S, Pandit SK. Abdomino-scrotal lymphangioma. Indian J Pediatr. 1997;64:720-4.
10. Johansen TL, Sondergaard G, Ebling A. Lymphangioma of the scrotum. Scand J Urol Nephrol. 1999;33:205-6.
11. Alqahtani A, Nguyen LT, Flageole H, Shaw K, Laberge JM. 25 years' experience with lymphangiomas in children. J Pediatr Surg. 1999;34:1164-8.
12. Grossgold ET, Kusuda L. Scrotal lymphangioma in an adult. Urology. 2007;70(3):590-2.

Cite this article as: Ravindra I, Dinkar K, Warad BS. Lymphangioma an unusual adult scrotal lump: case report and review. Int Surg J 2016;3:2314-6.