

Case Report

Hobnail variety of papillary cell carcinoma thyroid mimicking a thyroglossal cyst: a rare presentation

K. S. Ravishankar, Atreya M. Subramanian*

Department of Surgery, Sree Balaji Medical College and Hospital, Chennai, Tamil Nadu, India

Received: 10 March 2019

Accepted: 16 May 2019

***Correspondence:**

Dr. Atreya M. Subramanian,
E-mail: atreya11@gmail.com

Copyright: © the author(s), publisher and licensee Medip Academy. This is an open-access article distributed under the terms of the Creative Commons Attribution Non-Commercial License, which permits unrestricted non-commercial use, distribution, and reproduction in any medium, provided the original work is properly cited.

ABSTRACT

The hobnail variant of papillary thyroid carcinoma (HVPTC) is a newly described aggressive variant relative to that of the classical PTC. There have been genetic markers like the BRAF V600E mutation associated with more aggressiveness and a higher rate of recurrence and mortality. Here we discuss a case of thyroid swelling which clinically resembled a thyroglossal cyst due to movement of the swelling with tongue protrusion. Imaging indicated a multilobulated cystic swelling arising from the thyroid gland. FNAC was suggestive of colloid goitre. Total thyroidectomy was done and histopathology revealed HVPTC. HVPTC is an aggressive variant and if diagnosed preoperatively may warrant more extensive surgery. One must also have a high index of suspicion for thyroid swellings that are large with variable clinical presentations (including multiple septations) as they may appear benign on FNAC but may prove to be malignant on histopathology.

Keywords: Hobnail variant, Papillary thyroid carcinoma

INTRODUCTION

Hobnail variant of papillary thyroid carcinoma (HVPTC) was first described as a new aggressive variant in 2009 characterized by tumor cells harboring hobnail features¹. All the studies have suggested that HVPTC behave more aggressively than classical PTC (CPTC). Recently, one study reported that the hobnail variant was observed in more aggressive thyroid tumors, such as poorly differentiated thyroid carcinomas, and suggested that hobnail features may be an indication of higher-grade transformation.²

A high BRAF V600E mutation frequency (74%, range 40-80%) was observed.³

BRAF V600E, a PTC-associated genetic abnormality, is the most prevalent mutation found in CPTC, and has been found to be associated with more aggressiveness and

higher risk of recurrence and mortality in a couple of large-cohorts.⁴

Besides the nuclear features of conventional PTC on histology, the tumor cells in the hobnail variant have characteristic features with the nucleus located in the apex of cytoplasm. The hobnail features usually appears with micropapillary growth pattern so this type of tumor is also called the hobnail/micropapillary variant.^{1,5} The definition of this variant originally required that at least 30% of the tumor cells had hobnail features. However, a later study by the same group of pathologists showed that PTCs with even a smaller percentage of cells with hobnail features could be associated with an aggressive behaviour.⁶ Here, we discuss a case of a thyroid swelling clinically resembling a thyroglossal cyst which eventually turned out to be the hobnail variant of papillary thyroid carcinoma.

CASE REPORT

A 47 yr old male presented with a midline neck swelling for a duration of 2 months which was initially small in size and gradually progressed to the present size of about 5x3cm. The swelling moved with deglutition suggesting it to be a thyroid swelling. It also appeared to move with tongue protrusion (though not very significantly) indicating the possibility of a thyroglossal cyst.



Figure 1: ???

Basic blood investigations, including thyroid function tests were normal. An ultrasound of the neck showed a large multilobulated cystic lesion of about 7x4 cm arising from the isthmus extending up to the sternum and posteriorly behind the left lobe. Provisionally a diagnosis of a colloid cyst or a thyroglossal cyst was suspected.

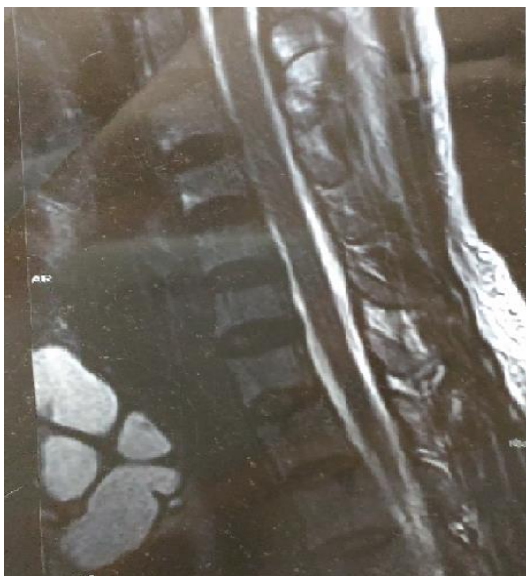

Figure 2: ???

Fine needle aspiration cytology was suggestive of either a colloid goitre or a thyroglossal cyst. Due to the diagnostic dilemma and to rule out the possibility of a thyroglossal tract, an MRI was taken which showed a multilobulated cystic lesion with thick internal septations of size 6.5x6x4 cm extending from the manubrium up till the isthmus and involving the thyroid gland; reducing the likelihood of a thyroglossal cyst. Hence, total thyroidectomy was planned along with removal of the entire cyst.

Intraoperatively we noted a large multilobulated swelling arising from the thyroid isthmus which was adherent to the strap muscles. Total thyroidectomy was done with complete excision of the cyst. The post-operative period was uneventful. The drain was removed on post-operative day 3 and sutures were removed on post-operative day 8.

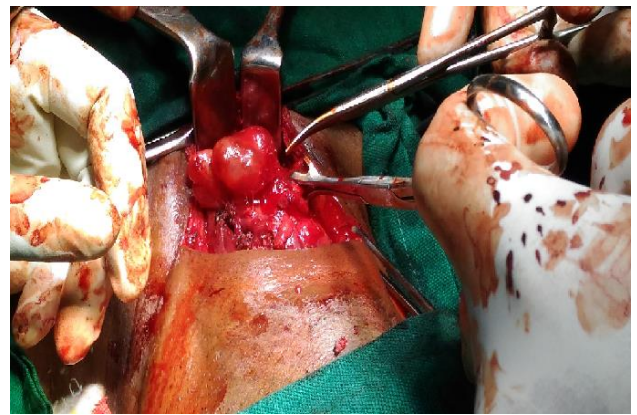


Figure 3: ???

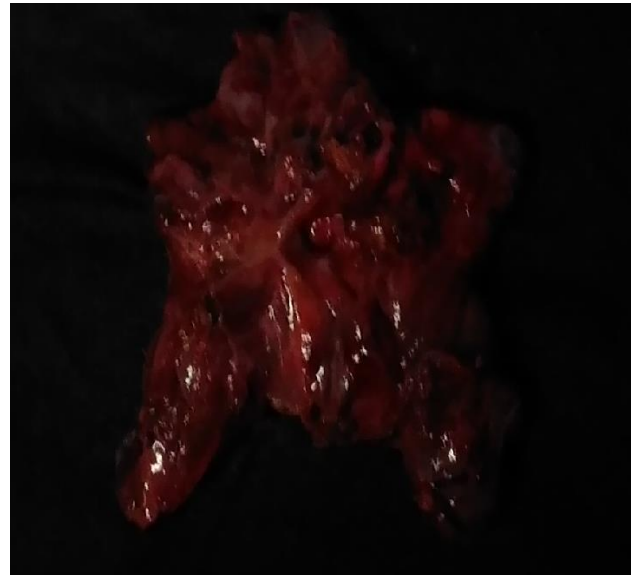

Figure 4: ???

The histopathology revealed a papillary carcinoma thyroid of the hobnail variety (apically placed nuclei in the background of eosinophilic cytoplasm) as the extent of involvement was greater than 30% in the tumour area.

The patient was followed up with a radio-iodine thyroid uptake scan which did not show any distant spread.

DISCUSSION

In 2012, Bellevicine et al retrospectively reviewed the cytologic features of a PTC with prominent hobnail features.⁷ They described hobnail features as comet-like cell features and predicted that the preoperative recognition of PTC with prominent hobnail features on FNA would warrant more extensive neck surgery. Papillary thyroid carcinomas are the most common endocrine cancer and are usually associated with good survival. There are multiple variants with aggressive behaviour including the tall cell variant of papillary thyroid carcinoma which is the most common aggressive variant. The columnar variant can also be aggressive, particularly in older patients, with larger tumors showing a diffusely infiltrative growth pattern and extrathyroidal extension. The hobnail variant of papillary thyroid carcinoma is new to the fourth edition of the WHO Classification of tumours of endocrine organs, and is usually a moderately differentiated papillary thyroid carcinoma variant with aggressive clinical behavior with significant mortality.⁸ All of these variants are histologically unique and important to recognize due to their aggressive behavior.

Considering the nature of the disease one must be extra cautious when dealing with the hobnail variety due to its aggressive nature and if identified pre-operatively must consider more extensive surgery.

Funding: No funding sources

Conflict of interest: None declared

Ethical approval: Not required

REFERENCES

1. Motosugi U, Murata S, Nagata K, Yasuda M, Shimizu M. Thyroid papillary carcinoma with micropapillary and hobnail growth pattern: a histological variant with intermediate malignancy? *Thyroid*. 2009;19:535–7.
2. Amacher AM, Goyal B, Lewis JS, Jr, El-Mofty SK, Chernock RD. Prevalence of a hobnail pattern in papillary, poorly differentiated, and anaplastic thyroid carcinoma: a possible manifestation of high-grade transformation. *Am J Surgical Pathol*. 2015;39:260–5.
3. Lubitz CC, Economopoulos KP, Pawlak AC, Lynch K, Dias-Santagata D, Faquin WC. Hobnail variant of papillary thyroid carcinoma: an institutional case series and molecular profile. *Thyroid*. 2014;958–65.
4. Li C, Lee KC, Schneider EB, Zeiger MA. BRAF V600E mutation and its association with clinicopathological features of papillary thyroid cancer: a meta-analysis. *J Clin Endocrinol Metabol*. 2012;97:4559–70.
5. Asioli S, Erickson LA, Righi A, Lloyd RV. Papillary thyroid carcinoma with hobnail features: histopathologic criteria to predict aggressive behavior. *Hum Pathol*. 2013;44:320-8.
6. Bellevicine C, Cozzolino I, Malapelle U, Zeppa P, Troncone G. Cytological and molecular features of papillary thyroid carcinoma with prominent hobnail features: a case report. *Acta Cytol*. 2012;56:560-4.
7. Nath, Erickson MC, Lori A. Aggressive Variants of Papillary Thyroid Carcinoma: Hobnail, Tall Cell, Columnar, and Solid. *Advances In Anatomic Pathol*. 2018;25(3):172–9.

Cite this article as: Ravishankar KS, Subramanian AM. Hobnail variety of papillary cell carcinoma thyroid mimicking a thyroglossal cyst: a rare presentation. *Int Surg J* 2019;6:2198-200.