

## Original Research Article

# Comparative study on surgical outcomes of needle port assisted two port laparoscopic appendicectomy verses conventional three-port laparoscopic appendicectomy

Rajiv Sonarkar<sup>1</sup>, Ashutosh Ghuge<sup>2\*</sup>, Murtaza Akhtar<sup>3</sup>

<sup>1</sup>Associate Professor, Department of Surgery, NKP Salve Institute of Medical Science and Research Center, Nagpur, Maharashtra, India

<sup>2</sup>Junior Resident, NKP Salve Institute of Medical Science and Research Center, Nagpur, Maharashtra, India

<sup>3</sup>Head, Department of Surgery, NKP Salve Institute of Medical Science and Research Center, Nagpur, Maharashtra, India

**Received:** 09 March 2019

**Revised:** 13 May 2019

**Accepted:** 15 May 2019

**\*Correspondence:**

Dr. Ashutosh Ghuge,

E-mail: [ashm0781@gmail.com](mailto:ashm0781@gmail.com)

**Copyright:** © the author(s), publisher and licensee Medip Academy. This is an open-access article distributed under the terms of the Creative Commons Attribution Non-Commercial License, which permits unrestricted non-commercial use, distribution, and reproduction in any medium, provided the original work is properly cited.

### ABSTRACT

**Background:** Conventional three port laparoscopic appendicectomy is fast becoming a procedure of choice for appendicitis. Needle port assisted two port laparoscopic appendicectomy is the procedure with similar technique as conventional procedure but has its distinctive advantages. The present study aims to compare the results of needle port assisted two port and conventional three port laparoscopic appendicectomy.

**Methods:** In comparative non-randomized study patients with acute appendicitis, recurrent appendicitis and patients posted for interval appendicectomy of age >18 years, both gender without co-morbidity were enrolled as subjects. Non-consenting patients were excluded. The study factor was needle port assisted two port and conventional three port laparoscopic appendicectomy procedure. The allocation to each procedure was done at random. The outcome factors were compared between both groups.

**Results:** A total of 91 patients with a mean age of 29.77 years and F:M ratio of 1.67:1 were enrolled, of them 31 underwent needle port assisted two port laparoscopic appendicectomy. The mean operative time for two port was 53.38±7.97 min as compared to conventional three port was 44.65±5.86 min which was statistically significant but cosmetic outcome was better as well as statistically significant with two port procedure. The post-operative pain, intra-operative and post-operative complications were compared between these groups but were statistically not significant.

**Conclusions:** Needle port assisted two port laparoscopic appendicectomy appears to give better cosmetic results and can be a good surgical alternative modality for uncomplicated appendicitis.

**Keywords:** Conventional three-port laparoscopic appendicectomy, Needle port assisted two-port laparoscopic appendicectomy

### INTRODUCTION

Appendicectomy is one of the most commonly performed surgical procedure of the abdomen in the world. This surgical procedure has been performed for over 100

years. McBurney's procedure represented the gold-standard for acute appendicitis until 1981, when a German Gynaecologist Kurt Semm performed the first laparoscopic appendicectomy in 1983.<sup>1,2</sup> Recent EAES (European Association of Endoscopic Surgery)

guidelines states that laparoscopic appendicectomy has a small but definite advantage like decreased post-operative pain, fewer post-operative complications, shorter hospitalization, earlier mobilization, earlier return to work, and better cosmesis over open appendicectomy.<sup>3,4</sup>

In this era of minimal access surgery, attempts are continuously being made to make laparoscopic surgeries even lesser invasive and better cosmetically. The most prominent techniques representing scar-less surgery are trans-umbilical single-incision laparoscopic surgery (SILS) and natural orifice transluminal endoscopic surgery (NOTES). The present study aims to compare the results of needle port assisted two port laparoscopic appendicectomy technique and conventional three port laparoscopic appendicectomy.

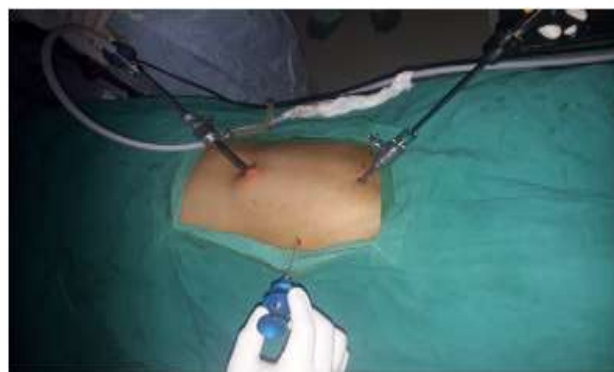## METHODS

This is a comparative study conducted at NKP SIMS and RC, Nagpur a tertiary care teaching hospital from December 2016 to November 2018. The subjects of both genders with age more than 18 years which are diagnosed to have acute appendicitis, recurrent appendicitis or patients posted for interval appendicectomy were enrolled in the study. The exclusion criteria were patients with complicated appendicitis like appendicular abscess, perforated appendicitis or appendicular lump. Patients which were converted to open appendicectomy procedure were also excluded from this study.

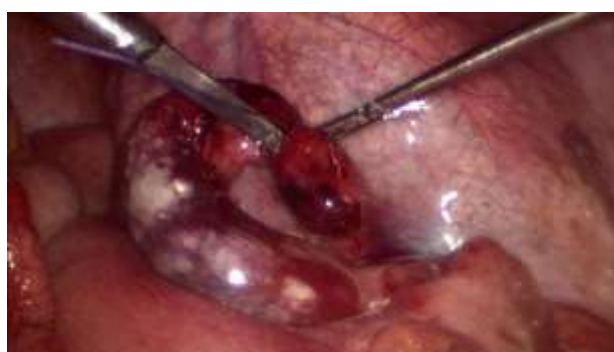The study factors were two surgical procedures, needle port assisted two port laparoscopic appendicectomy (Figure 1-3) and conventional three port laparoscopic appendicectomy. Patients were allocated to the two groups non-randomly i.e. two surgical units carried out needle port assisted two port laparoscopic appendicectomy and rest three units did conventional three port procedure. From a cosmetic viewpoint, the conventional three-port laparoscopic appendicectomy technique has the umbilical and supra-pubic port sites which are hidden by natural camouflages, the right iliac fossa (RIF) port is the only visible external sign of surgery. In conventional three port laparoscopic appendicectomy umbilical and supra-pubic port site are hidden by natural camouflage and only right iliac fossa port is visible. This was omitted in needle port assisted two port laparoscopic appendicectomy.



**Figure 1: Needle suture grasper.**



**Figure 2: Needle suture grasper in right iliac fossa.**



**Figure 3: Appendix held by needle suture grasper and used as traction.**

The outcome factors evaluated were operative time, intra-operative and post-operative complications, post-operative pain on first day and cosmetic score and cosmetic satisfaction after one month. Descriptive statistics like mean, standard deviation and table were used for demographic and clinical data. The baseline features of the two groups were compared to ascertain the equality of the two groups. The continuous variables were analysed by student t-test or Mann-Whitney U test and depending on the normality of the data and categorical variables by Fischer exact test or Chi-square test. The study had ethical clearance from IEC of the institution.

## RESULTS

Of the 91 patients enrolled in the study, the mean age of the patients was  $29.77 \pm 6.77$  years with female: male ratio was 1.67:1 out of which majority (79.11%) of the patients were observed in 3<sup>rd</sup> and 4<sup>th</sup> decade of life. The mean operative time in needle port assisted two port laparoscopic appendicectomy was  $53.38 \pm 7.97$  min and conventional three port laparoscopic appendicectomy required  $44.65 \pm 5.86$  min. This was statistically significant (Table 1).

Post-operative VAS pain score on first day was  $3.09 \pm 0.39$  and  $3.3 \pm 0.56$  in two-port and three-port laparoscopic appendicectomy groups respectively. The

intra-operative and post-operative complications in both groups were also statistically not significant. The cosmetic score and cosmetic satisfaction evaluation was done after one month by using Ramon Vilallonga scale

(2012).<sup>5</sup> Patients undergoing needle port assisted two port appendectomy procedure had better mean cosmetic score of 8.09±1.01 as compared to conventional three port appendectomy patients with 7.2±0.89 (Table 2).

**Table 1: Comparison of operative time group according to operative procedures.**

Operating time	Operative procedures			
	Group I		Group II	
	No. of subjects	%	No. of subjects	%
≤30	0	0	1	1.67
>30-60	30	96.77	59	98.33
>60	1	3.23	0	0
<b>Total</b>	31	100	60	100
<b>Mean operative time</b>	53.38±7.97 min		44.65±5.86 min	
<b>p-value</b>	0.0001 (HS)			

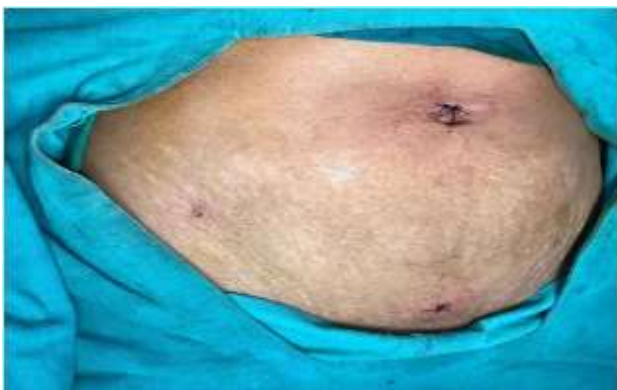
**Table 2: Mean cosmetic score in both groups.**

Cosmetic score	Group I	Group II
<b>Mean cosmetic score</b>	8.09	7.2
<b>S.D</b>	1.01	0.89
<b>Range</b>	5-10	5-9
<b>P-value</b>	0.0001 (HS)	

About 80.64% (25) of patients were highly satisfied with two port laparoscopic appendectomy procedure, whereas only 61.66% (37) of patients were highly satisfied with their three port procedures. These findings were statistically significant (Table 3 and Figure 4).

**Table 3: patients with cosmetic satisfaction in both groups.**

Cosmetic satisfaction	Group I	Group II	Total
<b>Highly satisfactory</b>	25 (80.64%)	37 (61.66%)	62 (68.14%)
<b>Satisfactory</b>	5 (16.13%)	16 (26.67%)	21 (23.07%)
<b>Not satisfactory</b>	1 (3.23%)	7 (11.67%)	8 (8.79%)
<b>Total</b>	31 (100%)	60 (100%)	91 (100%)



**Figure 4: Cosmetic scar.**

**DISCUSSION**

Appendectomy is probably the most common surgery performed in surgical practice. Laparoscopic appendectomy has proven its edge over open procedure for better cosmesis, lesser pain and shorter hospital stay.

According to the Cochrane review and the EAES guidelines, there is a small but certain advantage of laparoscopic appendectomy over open appendectomy.<sup>6,7</sup> Routinely, Conventional laparoscopic appendectomy uses three ports, 5-10mm ports in the umbilical and RIF, right hypochondrial or left iliac fossa regions often leaves clearly visible scars. There is also an increasing trend towards single incision laparoscopic surgery (SILS) with use of a special multiport umbilical trocar. In this era of minimal access surgery, attempts are continuously being made to make laparoscopic surgeries even lesser invasive and better cosmetically.

The most prominent techniques representing scar-less surgery are trans-umbilical single-incision laparoscopic surgery (SILS) and natural orifice transluminal endoscopic surgery (NOTES). In Single Incision Laparoscopic Surgery (SILS) using a special multiport umbilical trocar and specialized instruments three ports can be avoided, but difficulties like steep learning curve, swording of instruments, decreased maneuverability, requiring technical expertise.<sup>8,9</sup> Likewise, Natural orifice

transluminal endoscopic surgery (NOTES) has complications like failed sutures, lack of fully developed instrumentation, complication of opening hollow viscera as well as adding a financial burden to the patients due to requirement of specialized instruments, making its use limited.<sup>10,11</sup>

In present study we have adopted Needle port assisted two-port laparoscopic appendectomy method which is virtually scar-less by the omission of RIF port which was the only visible external sign of laparoscopic surgery; making it less-invasive and cosmetically better surgery.

The mean age in the present study was 29.77±7.31 years which is consistent with the literature.<sup>12,13</sup> Majority of patients (79.11%) were observed in 3<sup>rd</sup> and 4<sup>th</sup> decade which is also consistent with literature.<sup>14,15</sup> Female: Male ratio was 1.67:1 suggesting the female preponderance in present study as well as literature.<sup>14,15</sup> About half of all patients (50.54%) were diagnosed as cases of recurrent appendicitis and 34.06% of patients were of acute appendicitis and 15.38% of patients were posted as interval appendectomy in the present study, which are consistent with literature.<sup>13</sup> The position of the appendix is extremely variable, in present study majority (85.72%) of patients had appendix located in retro-cecal position, followed by pelvic (10.99%) and sub-hepatic (3.29%) locations, consistent with reported study.<sup>15</sup>

The mean operative time required for needle port assisted two port laparoscopic appendectomy and conventional three port laparoscopic appendectomy procedure were 53.38±7.97 min and 44.65±5.86 min respectively, which is statistically significant and indicates time required for two port procedure was more than conventional three port, which is consistent with some studies.<sup>14,15</sup> The operative time decreases significantly once the surgeon gets accustomed with the new technique. This could be explained by "learning curve" effect associated with any new technique, which was also shown in studies by Rammohan.<sup>14</sup> Mhatre reported a series of 58 cases performed in a single institution in which a 'learning curve' effect was present with respect to shorter operating times and the inclusion of more technically difficult patients as the surgeons gained experience with the procedure.<sup>15</sup> The present study also shows that there was no statistically significant difference between the two procedures in terms of post-operative pain, intra-operative and post-operative complications, which is similar to some reported studies.<sup>15-17</sup>

The mean cosmetic score of both the groups was 8.09±1.01 and 7.2±0.89 respectively suggesting a better cosmetic outcome with needle port assisted laparoscopic appendectomy procedure which is highly significant and also consistent with reported literature studies.<sup>5,18</sup> Many surgeons have attempted to reduce incisional morbidity and improve cosmetic outcomes in laparoscopic appendectomy by using fewer and smaller ports. Study by Kollmar described moving laparoscopic

incisions to hide them in the natural camouflages like the suprapubic hairline and improve cosmesis.<sup>18</sup>

## CONCLUSION

Needle port assisted two port laparoscopic appendectomy could be a safe and feasible procedure, which while being cosmetically acceptable has an economic advantage and acts as an ideal bridge before SILS appendectomy or even NOTES appendectomy.

## ACKNOWLEDGEMENTS

Authors would like to thanks Dr. Kajal Mitra, Dean NKPSIMS, Nagpur for granting permission to publish this article. Authors would also acknowledge and thank Dr. Ughade Asst. Prof of Biostatistics for statistical support.

*Funding: No funding sources*

*Conflict of interest: None declared*

*Ethical approval: The study was approved by the Institutional Ethics Committee*

## REFERENCES

1. Addiss DG, Shaffer N, Fowler BS, Tauxe R V. The epidemiology of appendicitis and appendectomy in the united states. *Am J Epidemiol.* 1990;132(5):910-25.
2. Semm K. Endoscopic Appendectomy. *Endoscopy.* 1983;15(02):59-64.
3. Li X, Zhang J, Sang L, Zhang W, Chu Z, Li X. Laparoscopic versus conventional appendectomy - a meta-analysis of randomized controlled trials. *BMC Gastroenterol.* 2010;10(1):129.
4. Yagnik VD, Rathod JB, Phatak AG. A retrospective study of two-port appendectomy and its comparison with open appendectomy and three-port appendectomy. *Saudi J Gastroenterol.* 2010;16(4):268-71.
5. Vilallonga R, Barbaros U, Nada A. Single-port transumbilical laparoscopic appendectomy: a preliminary multicentric comparative study in 87 patients with acute appendicitis. *Minim Invasive Surg.* 2012;2012:492-409.
6. Guller U, Hervey S, Purves H, Muhlbaier LH, Peterson ED, Eubanks S, et al. Laparoscopic Versus Open Appendectomy. *Ann Surg.* 2004;239(1):43-52.
7. Cox MR, McCall JL, Toouli J. Prospective randomized comparison of open versus laparoscopic appendectomy in men. *World J Surg.* 1996;20:263-6.
8. Udwardia TE. Single-incision laparoscopic surgery: An overview. *J Minim Access Surg.* 2011;7(1):1-2.
9. Rao PP, Rao PP, Bhagwat S. Single-incision laparoscopic surgery-current status and controversies. *J Minim Access Surg.* 2011;7(1):6-16.

10. Chamberlain RS, Sakpal SV. A comprehensive review of single-incision laparoscopic surgery (SILS) and natural orifice transluminal endoscopic surgery (NOTES) techniques for cholecystectomy. *J Gastrointest Surg.* 2009;13(9):1733-40.
11. Romanelli JR, Earle DB. Single-port laparoscopic surgery: an overview. *Surg Endosc.* 2009;23(7):1419-27.
12. Husain M, Sahu S, Sachan P. Two-Port Laparoscopic Appendectomy. *Int J Surg.* 2010;27(2).
13. Gupta R, Singal R, Sharda VK, Singh B, Ahluwalia JS, Bhatia G, et al. Two port laparoscopic assisted appendectomy versus three port laparoscopic appendectomy: A prospective study of 50 cases. *TJMR J.* 2015;18(1):1.
14. Rammohan A, Jothishankar P, Manimaran AB, Naidu R M. Two-port vs. three-port laparoscopic appendectomy: A bridge to least invasive surgery. *J Min Access Surg.* 2012;8:140-4.
15. Mhatre HP, Kanake VB, Nandu VV. a new technique in laparoscopic appendectomy. 2015;1(5):215-9.
16. Sutariya P, Chavda J. two ports versus three port laparoscopic appendectomy- a step further towards minimal invasiveness. *Int J Res Med.* 2015;4(1):98-101.
17. Mujawar P, Patel N, Gouhar R, Mishra A. Comparative study between laproscopic appendectomy and Laproscopic assisted appendectomy. *Global J Res Analysis.* 2018;7(9):227-8160.
18. Kollmar O, Z'graggen K, Schilling MK, Buchholz BM, Buchler MW. The suprapubic approach for laparoscopic appendectomy. *Surg Endosc.* 2002;16:504-8.

**Cite this article as:** Sonarkar R, Ghuge A, Akhtar M. Comparative study on surgical outcomes of needle port assisted two port laparoscopic appendectomy verses conventional three-port laparoscopic appendectomy. *Int Surg J* 2019;6:2088-92.