

Original Research Article

Complications of appendicitis in a tertiary care centre

Nanditha Gudi, John M. Francis*, Shivananda, Thinagaran K.

General Surgery, PESIMSR, Kuppam, Andhra Pradesh, India

Received: 25 February 2019

Revised: 05 August 2021

Accepted: 09 August 2021

***Correspondence:**

Dr. John M. Francis,

E-mail: drjohnmf63@gmail.com

Copyright: © the author(s), publisher and licensee Medip Academy. This is an open-access article distributed under the terms of the Creative Commons Attribution Non-Commercial License, which permits unrestricted non-commercial use, distribution, and reproduction in any medium, provided the original work is properly cited.

ABSTRACT

Background: Acute appendicitis is the most common surgical emergency. An appendicectomy is considered the gold standard of treatment for acute appendicitis because of the potential risk of disease progression to perforation, gangrene and peritonitis. The aim of this study was to determine the incidence of complications in patients diagnosed with acute appendicitis.

Methods: A total number of 70 patients were studied with various symptoms of acute appendicitis and their complications, all patients were presented to PESIMSR, Kuppam from December 2016 to June 2018. Clinical assessment, investigations like WBC counts, X-ray erect abdomen, USG abdomen and pelvis and management were recorded. The incidence of complications were studied. The cases of appendicular mass was treated conservatively, except for those who do not respond to antibiotics.

Results: During this study period, among 70 patients aged between 5-45 years, male were 53 and female patients were 17 and 11 patients belong to pediatric age group and 59 patients aged more than 18 years. The commonest complication was postoperative surgical site infection (20%) found in perforated appendix patients in our study. Around 76% of the patients developed complications. Among the female patients diagnosed with acute appendicitis, appendicular perforation being the most common complication and it was the postoperative surgical site infections in males.

Conclusions: Acute appendicitis is the most common surgical emergency. Open appendicectomy is the most commonly done procedure in our hospital. The commonest complication is postoperative surgical site infection (20%) found in perforated appendix patients in our study.

Keywords: Appendicitis, Ultrasound, Postoperative surgical site infections, Appendicular perforation, Appendicectomy

INTRODUCTION

Acute appendicitis is the most common surgical cause of emergency laparotomy. Simple appendicitis can progress to perforation, which is associated with a much higher morbidity and mortality and surgeons have therefore been inclined to operate when the diagnosis is probable rather than wait until it is certain.¹ The surgical principle about acute appendicitis when in doubt, take it out, is not correct in view of the number of major and minor

complications following appendicectomy. The classical signs and symptoms of acute appendicitis were first reported by Fitz. The Alvarado score was described in 1986 and has been validated in adult surgical practice. The use of an objective scoring system such as the Alvarado system can reduce the negative appendicectomy rate to 0-5%.

METHODS

All patients with acute appendicitis who presented to PESIMSR, Kuppam were included in the study. Only patients of age between 5-45 years were included in this study.

Detailed history was taken from the patient or patient's attenders. A complete general and systemic examination was done and clinical findings were documented. Clinical parameters of Alvarado score was used in diagnosis of acute appendicitis. Blood investigations and urinary analysis was done in all patients erect X-ray abdomen, USG abdomen and pelvis was done for the condition being evaluated. Blood investigations (WBC counts) and urinary analysis helped in evaluation of patients with acute appendicitis. USG and erect X-ray abdomen helped in evaluation of appendicular perforation.

The patients subjected to emergency surgery were adequately prepared. Whenever vomiting persisted, Ryle's tube aspiration was done. Parenteral fluids, electrolyte supplementation broad spectrum antibiotics were administered. Hourly temperature, pulse and respiratory chart were maintained.

Surgery was done under general anaesthesia or spinal anaesthesia. When diagnosis of acute appendicitis was certain, grid-iron incision was used. Right paramedian incision was used when diagnosis was uncertain or when frank peritonitis was suspected. Before resection the appendix was assessed. The specimen sent for histopathological examination and the reports analyzed. Then a study of the complications was done in each case.

Study design

This was a hospital based prospective study.

Study period

The study duration was from December 2016 to June 2018.

Place of study

The study was conducted in the department of general surgery, PESIMR, Kuppam, Andhra Pradesh, India.

Study population

Patients diagnosed with acute appendicitis who presented to emergency room were included.

Sample size

The sample size was 70.

Sampling technique

The sampling technique used was a convenient sampling technique.

Inclusion criteria

Patients aged 5-45 years, patients who consented for the study, patients presenting with non-traumatic acute abdominal pain and patients needing surgical intervention within 24-48 hours were included in the study.

Exclusion criteria

Patients with traumatic acute abdomen, with acute abdomen due to urological or gynaecological disorders and aged less than 5 years were excluded from the study.

Method of data collection

After explaining about the study and obtaining informed consent from the patient, detailed history regarding the presenting complaint was collected from the patient or their attenders. Clinical findings were documented in a pre-defined proforma. Later, all the patients were subjected to blood investigations, ultrasound examination and the findings are noted. Finally, for every patient, intra operative findings and postoperative follow up details were collected and noted.

Investigations done

Complete hemogram and other necessary blood investigations, USG abdomen and pelvis, erect X-ray abdomen investigations were done.

Analysis of data

The data were entered into MS excel 2007 version and further analyzed using SSPS version 20. For descriptive analysis, the categorical variables were analyzed by using percentages.

RESULTS

In our study of 70 patients diagnosed with appendicitis, overall complications were seen in 57 patients. Among them, postoperative surgical site infections was the most common complication found 20%, that is, seen in 19 patients of appendicular perforation (Figure 4).

Our study included patients aged 5 to 45 years (Table 1). Of them maximum number of patients N=59, that is, 84.29% were more than 18 years of age.

In our study, with 70 patients diagnosed with acute appendicitis, postoperative surgical site infection (20%), found in perforated appendix patients in our study (Figure 2).

Table 1: Age wise ratio of the patients included in the study.

Age (in years)	No. of patients	Percentage %
<18	11	15.71
>18	59	84.29
Total	70	100

Table 2: Age wise distribution of complications.

Complications	No. of patients (<18 years)	No. of patients (>18 years)
Nil complication	6	17
Appendicular mass	1	7
Appendicular abscess	1	13
Appendicular perforation	3	8
Peritonitis	2	7
Small bowel obstruction	2	2
Gangrenous appendix	Nil	3
Postoperative wound infection	Nil	19
Intraabdominal abscess	Nil	3

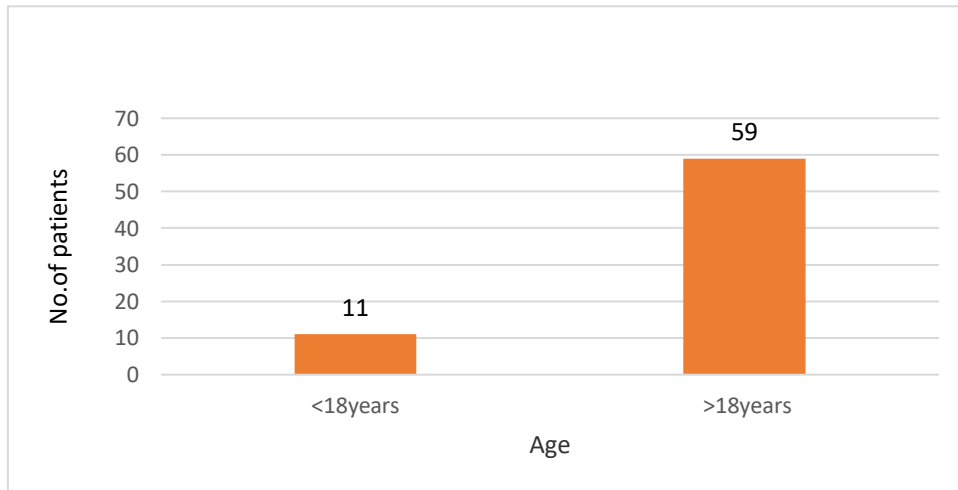


Figure 1: Age wise ratio of the patients included in the study.

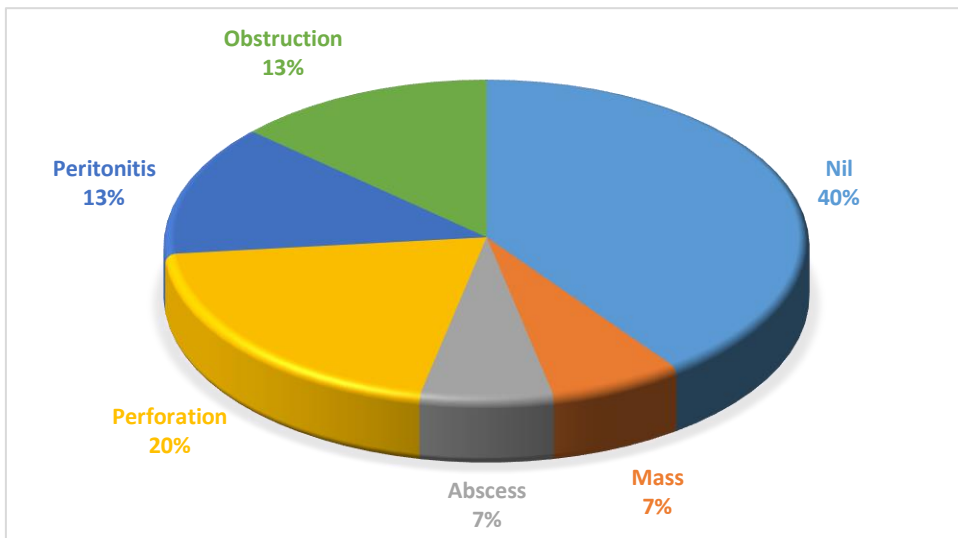


Figure 2: Complications in patients age less than 18 years.

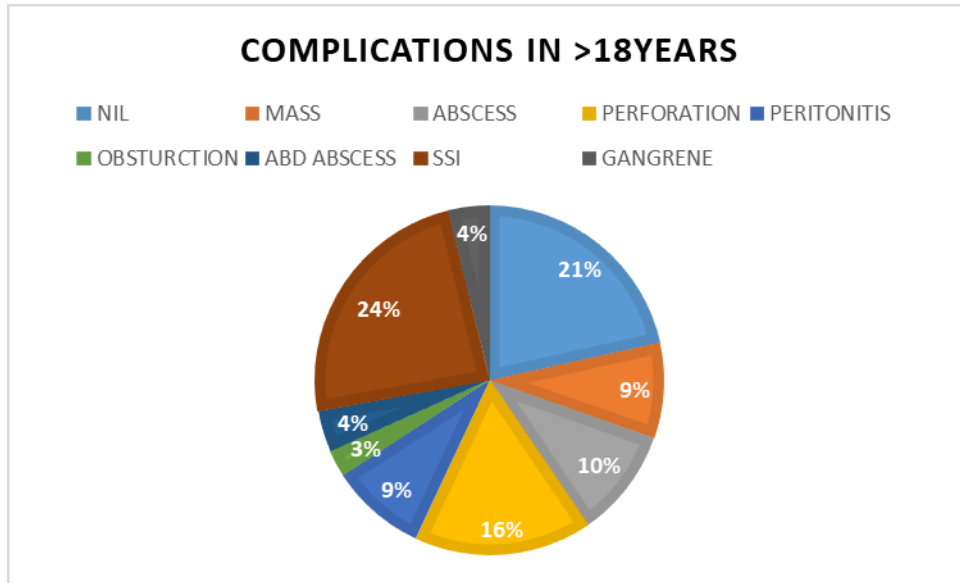


Figure 3: Complications in age more than 18 years.

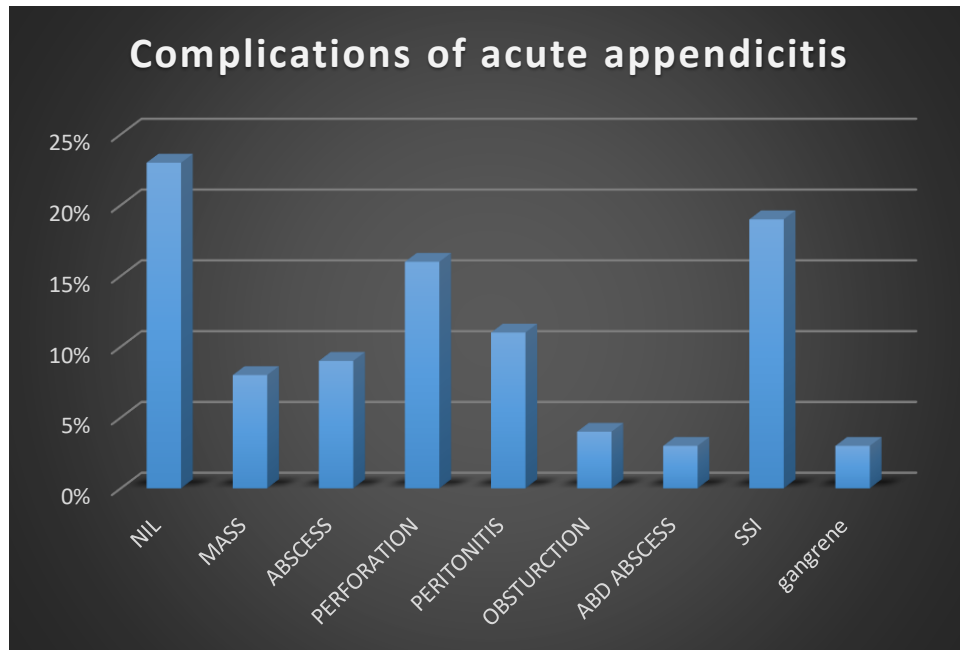


Figure 4: Incidence of complications in acute appendicitis.

This study included patients aged 5 to 45 years. Of them maximum number of patients N=59, that is, 4.29% were more than 18 years of age.

The most common complication found was appendicular perforation followed by peritonitis and small bowel obstruction in pediatric age group in this study (Figure 2). In patients aged >18 years, 24% of patients showed surgical site infection as the most common complication, followed by perforation, seen in 16% of patients (Figure 3).

DISCUSSION

Appendicitis is the most common abdominal surgical emergency, not all patients present in a typical manner.¹ This clinical entity needed surgical treatment in shortest possible time after the attack, if ignored it may get complicated and increase the morbidity and may prove fatal. Patients at the extremes of age have increased mortality.² Very young and old people were more vulnerable to complications because of their less immunity.³ Specialist investigations should not delay definitive treatment. Computed tomography scanning was more sensitive and specific than ultrasonography when

diagnosing acute appendicitis. Traditionally, the diagnosis of acute appendicitis should be made clinically and appendectomy was the preferred treatment of choice.⁴

At our hospital, open appendectomy was performed more commonly due to various reasons like expertise of the different operating surgeon, availability of assistant nurse trained in laparoscopy at emergency, patients from low income group. Clinical evidence suggested that it had some advantages over open surgery.² The mortality and morbidity are related to the stage of disease and increased in cases of perforation. The rate of postoperative wound infection was determined by the intraoperative wound contamination. Intra-abdominal or pelvic abscesses may form in the postoperative period after gross contamination of the peritoneal cavity.

In a study done by Omari et al postoperative complications were seen in 44 (21%) patients. Complications were three times more frequent in the perforated as compared to the non-perforated group of patients. In the perforated group, two patients developed multiple intraabdominal abscess collections.⁵ Their study showed that perforation rate correlated well with delayed presentation (pre-hospital delay) but did not correlate with the in-hospital delay. The incidence of appendiceal perforation in acute appendicitis was estimated to be in the range of 20-30% which increased to 32-72% in patients above 60 years of age. Their study showed that, fever (>38°C) was present in 41% of all patients and was much higher in the perforated group. WBC was found elevated in 63% of all patients with 74% shifts to left. As expected, values were higher in the perforated group as 71% of them had high WBC with 94% shift to left.⁵

Recently, these concepts were changing. Alvarado score and ultrasound examination which was operator dependent were often used in diagnosing appendicitis.⁵ In doubtful cases, utilization of CT scan abdomen and the usage of laparoscopy can reduce the morbidity associated with this disease. Increase in total leucocyte count and duration of the presentation can be a good marker of complicated appendicitis.⁶ CT scan of the abdomen can also be done to reduce the incidence of negative laparotomies.⁷

In a study done by Leite et al abdominal CT was a well-established technique in the study of acute abdominal pain and had shown high sensitivity and specificity for diagnosing and differentiating appendicitis, providing an accurate diagnosis in the early stages of disease.⁸

In a study done by Amitkumar et al total 40 patients (86.96%) required operative surgical intervention whereas 6 patients (13.04%) who had appendicular mass were managed conservatively.⁹ 35 patients (85.37%) underwent emergency surgeries whereas 5 patient had undergone elective procedure. Open appendectomy

(34.78%) was the most common surgery done followed by laparoscopic appendectomy (28.26%).⁹

CONCLUSION

Acute appendicitis is the most common cause of an acute abdomen. Open appendectomy is the most commonly done procedure in our hospital. Complications of appendicitis include perforation, gangrene, appendicular mass. In our study, postoperative wound infection was the commonest complication found in appendicular perforation patients. The use of perioperative antibiotics has been shown to decrease the rates of postoperative wound infections and abscess formation.

Funding: No funding sources

Conflict of interest: None declared

Ethical approval: The study was approved by the Institutional Ethics Committee

REFERENCES

1. Humes DJ, Simpson J. Acute appendicitis. *BMJ*. 2006;333(7567):530-4.
2. Korner H, Sondena K, Soreide JA, Andersen E, Nysted A, Lende TH, et al. Incidence of acute nonperforated and perforated appendicitis: age-specific and sex-specific analysis. *World J Surg*. 1997;21(3):313-7.
3. Pal N, Mahavir G, Kumar S, Sharma BD. Acute appendicitis: its symptoms, complications and management: a retrospective study. *Int J Enhanc Res Med Dent Care*. 2016;3(1).
4. Gomes CA, Sartelli M, Saverio SD, Ansaloni L, Catena F, Coccolini F, et al. Acute appendicitis: proposal of a new comprehensive grading system based on clinical, imaging and laparoscopic findings. *World J Emerg Surg*. 2015;10:60.
5. Omari AH, Khammash MR, Qasaimeh GR, Shammari AK, Yaseen MKB, Hammori SK. Acute appendicitis in the elderly: risk factors for perforation. *World J Emerg Surg*. 2014;9(1):6.
6. Murthy PS, Panda AP. Risk factors for complications in acute appendicitis among paediatric population. *Indian J Child Health*. 2018;5(9).
7. Bakti N, Hussain A, El-Hasani S. A rare complication of acute appendicitis: Superior mesenteric vein thrombosis. *Int J Surg Case Rep*. 2011;2(8):250-2.
8. Leite NP, Pereira JM, Cunha R, Pinto P, Sirlin C. CT evaluation of appendicitis and its complications: imaging techniques and key diagnostic findings. *AJR Am J Roentgenol*. 2005;185(2):406-17.
9. Amitkumar J, Viswanath. Surgical management of appendicitis and its complications: a retrospective study. 2013. *SEAJCRR*. 2013;2(4):212-7.
10. Gan BS, Sweeney JP. An unusual complication of appendectomy. *Case Rep*. 1994;29(12):1622.

11. Hoffmann J, Rasmussen OO. Aids in the diagnosis of acute appendicitis. *Br J Surg.* 1989;76(8):774-9.
12. Jones PF. Suspected acute appendicitis: trends in management over 30 years. *Br J Surg.* 2001;88(12):1570-7.
13. Townsend CM, Beauchamp RD, Evers BM, Mattox KL. *Sabiston textbook.* 21th ed. Philadelphia: Elsevier; 2021: 1296.

Cite this article as: Gudi N, Francis JM, Shivananda, Thinagaran K. Complications of appendicitis in a tertiary care centre. *Int Surg J* 2021;8:2612-7.