

Original Research Article

A study on the clinical and sonological correlation in the diagnosis and management of acute appendicitis in a tertiary care centre

Keerthi Mudavath, Thinagaran K.*

Department of General surgery, Pes Institute of Medical Sciences and Research, Kuppam. Karnataka, India

Received: 25 February 2019

Revised: 12 May 2019

Accepted: 13 May 2019

***Correspondence:**

Dr. Thinagaran K.,

E-mail: drdinky@gmail.com

Copyright: © the author(s), publisher and licensee Medip Academy. This is an open-access article distributed under the terms of the Creative Commons Attribution Non-Commercial License, which permits unrestricted non-commercial use, distribution, and reproduction in any medium, provided the original work is properly cited.

ABSTRACT

Background: Acute appendicitis is the most common acute surgical condition of the abdomen requiring early intervention. The diagnosis is often challenging and the decision to operate in an emergency setting is always debatable. Alvarado score for diagnosis of acute appendicitis is easy and additional tools like sonography results in accurate diagnosis. The aim was to evaluate accuracy of the clinical Alvarado scoring system, radiological findings and histopathological examination for the diagnosis of acute appendicitis.

Methods: 100 cases of acute abdomen admitted in PES institute of medical sciences and research, Kuppam from December 2016 to June 2018 were included. Clinical examination was done and all patients were subjected to ultrasound abdomen examination and other relevant blood and imaging investigations.

Results: Out of 100 patients 62 were males and 38 were Females. Most common symptom was pain in the right iliac fossa and patients with Alvarado Score 7 or > 7 subjected to USG followed by emergency appendectomy showed positive operative findings and histopathological findings. The overall specificity of abdominal USG in the diagnosis of acute appendicitis was 88.09% and sensitivity was 95.37%.

Conclusions: The Alvarado scoring system combined with ultrasound can therefore be used as a cheap and less expensive useful, reliable and non invasive way of confirming acute appendicitis thus helps in reducing negative appendectomy rate. The overall accuracy of diagnosis of acute appendicitis goes up to 90% with positive histopathological findings.

Keywords: Alvarado Score, Appendicitis, Histopathology, Ultrasonography

INTRODUCTION

Acute appendicitis is the most common cause of acute surgical abdomen with an estimated lifelong risk of 8.6% in men, 6.7% in women.¹ Appendicitis is the inflammation of appendix. It is a disease of the young, with 40% of cases occurring between the ages of 10 and 29 yrs. In 1886, Fitz reported classic symptoms and signs of the acute appendicitis the associated mortality rate of appendicitis to be atleast 67% without surgical therapy.²

The diagnosis of acute appendicitis is predominantly a clinical one many patients present with a typical history and examination findings.^{3,4}

The cause of acute appendicitis is unknown but is probably multifactorial- luminal obstruction, dietary and familial factors have all been suggested. Appendectomy is the treatment of choice.² Prompt diagnosis and surgical referral may reduce the risk of perforation and prevent complications.

The mortality rate in non perforated appendicitis is <1% but may be as high as 5% or more in young and elderly patients. A number of scoring systems for diagnosing acute appendicitis have been suggested to improve accuracy and decrease the negative appendectomy rate.⁵ Alvarado A et al (1986) described practical scoring system based on clinical signs and symptoms and laboratory investigations.⁶

Delay in diagnosis may lead to increase in morbidity and complications like perforation and peritonitis whereas overzealous diagnosis leads to increase in the negative appendectomy rate. Various diagnostic modalities are different scoring systems, ultrasonography, GIT Contrast studies, computer aided scores, computed tomography and MRI.

Among these modalities ultrasonography is simple, easily available, non-invasive, and convenient and cost effective.⁷ USG in the diagnosis of acute appendicitis was first popularized by Puylaert in 1986, one hundred years after the publication of first paper by Fitz. Pulayert reported the sensitivity of 89% and specificity of 100% of his technique in the diagnosis of acute appendicitis.⁸

METHODS

This study was carried out in the department of General Surgery, PES Institute of Medical Sciences & Research, Andhra Pradesh, India from December 2016 to June 2018.

Study Design: Hospital based prospective study. Study Period: December 2016 to June 2018. Place of Study: Department of General Surgery, PES Institute of Medical Sciences and Research, Andhra Pradesh, India. Study Population: Patients presenting with pain abdomen who required surgical intervention were included. Sample size: 100. Sampling technique: Convenient sampling technique

Inclusion criteria

- All patients presenting with right iliac fossa pain with clinical diagnosis of acute appendicitis during the study period, after informed consent, willing for surgery consecutively enrolled into the study.

Exclusion criteria

- Patients admitted for interval appendectomy following recurrent appendicitis, appendicular abscess, appendicular mass previously treated conservatively.
- Those patients who do not give consent for the study.

Investigations done

- Complete Hemogram and other necessary blood investigations.

- USG abdomen.

Analysis of data

All the data was primarily entered in Microsoft excel spread sheet and verified. The statistical analysis was done by SPSS version 17. The USG findings were compared with histology findings and sensitivity, specificity, and accuracy was calculated.

RESULTS

Of the total 100 patients involved in the study, 62 were male i.e. 62% and 38 were female i.e. 38% (Figure 1). The most common age group in the study was 21-30 years (46%) followed by 11-20 years (42%) and 31-40 years (9%) (Figure 1).

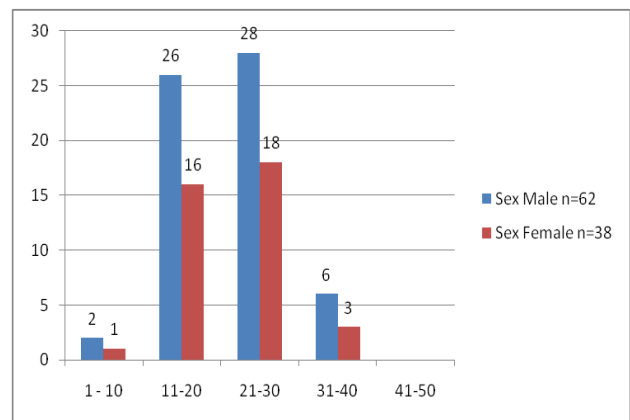


Figure 1: Age and sex distribution.

All cases are subjected to ultrasonography and high frequency probe was used out of which graded tenderness over McBurney’s point, localized adynamic ileus in 88%, visualised and inflamed appendix in 33%, diameter > 6 mm in 6 %, wall thickness > 3 mm in 22%, normal in 12%, i.e. there were no ultrasonographic finding evidence of an inflamed appendix (Figure 2).

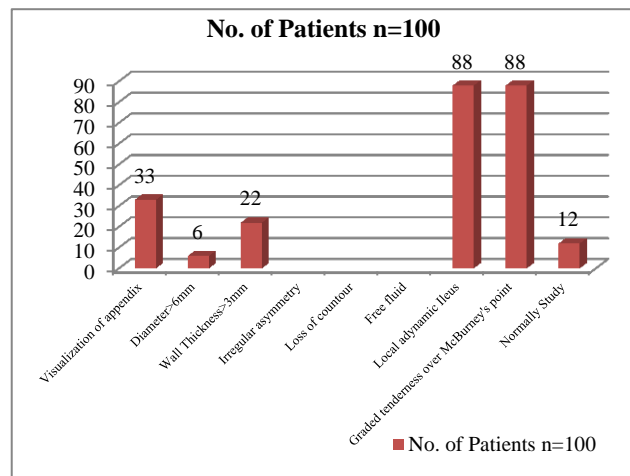


Figure 2: Ultrasonographic findings.

The sensitivity of ultrasound was 75.51% while specificity was 100% (Table 5). The ALVARADO SCORE variables were right iliac fossa tenderness (100%) (Table 3), migratory right iliac fossa pain (98%) (Table 1) and rebound tenderness (44%). Anorexia (88%), Nausea (87%), vomiting (83%) (Table 2), Increase in temperature (48%), Leucocytosis > 10,000 in (50%) >20,000 in (2%) (Table 4), Shift to the left. A score of < 7 indicated that the chances of inflamed appendix are highly unlikely, while a score of > 7 indicated that the chances of inflamed appendix are more likely. After applying the ALVARADO score, 10(10%) had a score of < 7 while male 54 (87%) and female 36 (94%) had score of >7 (Table 6) with positive histopathological findings in (88%) (Table 7) (Figure 3) with negative appendectomy rate in male (3.8%), female (16.7%). Women with normal appendix who underwent operation were having pelvic inflammatory disease in 5 patients, and ruptured follicular cyst in 1 patient. One of the males with normal appendix had Meckel's diverticulitis while the other had regional ileitis.

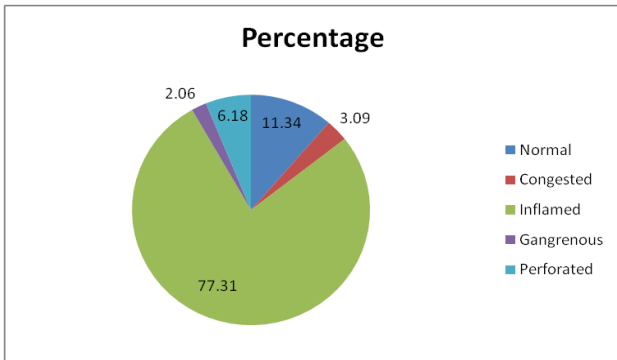


Figure 3: Pie diagram showing condition of the appendix.

Table 1: Showing pain distribution by various authors.

Authors	Pain around	Pain right lower	Pain in the Right
	Umbilicus	Quadrant	Iliac fossa
Gallindo			
Gallego et al ¹⁴	49%	32%	96.4%
Schwartz SI ¹²	50%	50%	100%
Present Study	59%	41%	98%

Table 2: Nausea or vomiting as a symptom.

Authors	Nausea (%)	Vomiting (%)
Owen et al ²²	84	78
Mathew et al ¹⁸	92	70.9
Schwartz ¹²	90	75
Present study	87	83

Table 3: Presence of right Iliac tenderness by various authors.

Authors	Percentage (%)
Bhattacharjee et al ¹⁷	92.00
Kallan, et al ²¹	95.00
Gallego et al ¹⁴	94.00
Mathews et al ¹⁸	99.1
Present study	100.00

Table 4: Leucocyte count by various authors.

Authors	Percentage >10,000	Percentage > 20,000
	Cells./ Cumm.	Cells/Cumm.
Peiper et al ¹⁹	60.00	5.00
Gallindo		
Galling et al ¹⁴	65.00	3.00
Elangovan's ²³	80.00	-
Doraiswamy ²⁰	42.00	-
Present Study	50.00	2.00

Table 5: Value of USG in the diagnosis of acute appendicitis.

Authors	Specificity (%)	Sensitivity (%)
Mathews et al ¹⁸	90.90	88.13
Puylaert et al ⁸	100	89
Gallego et al ¹⁴	82	89
Jeffrey et al ²⁴	96.2	89.9
Ziedan et al ²⁵	93.7	74.2
Fa et al ²⁶	90.6	66.7
Abu-you et al ¹³	95	85
Adams et al ²⁷	86	89
Present study	88	88

Table 6: Alvarado score 7 or > 7 by authors.

Authors	Percentage (%)	
	Male	Female
Bhattacharjee et al ¹⁷	84.5	80.00
Mohanty et al ¹⁵	75.00	88.23
Present study	87.00	94.7

Table 7: Histopathological reports by authors.

Authors	Percentage (%)
Bhattacharjee et al ¹⁷	82.7
Mohanty et al ¹⁵	94.44
George Mathews et al ¹⁸	84.28
Geryk et al ¹⁶	78.2
Present study	88.65

DISCUSSION

The discussion is based on the observations and analysis of the results in the study of 100 cases with regard to

incidence, age, sex, symptoms, signs, investigations operative findings, and histopathological examinations using Alvarado scoring system.

Acute appendicitis is one of the most common surgical emergencies encountered worldwide, The diagnosis mainly based on history and clinical findings.⁴ Also many scoring systems are in use to hasten the diagnosis of acute appendicitis. Scoring system reflects an inexpensive, non-invasive and easy to use diagnostic aid. Alvarado score is the most commonly used scoring system worldwide.⁹

A total score as per ALVARADO scoring system of (1-4) Appendicitis unlikely, (5- 6) Appendicitis possible, (7-8) Appendicitis probable, (9-10) Appendicitis definitive.

But still many radiological investigations have been used for the diagnosis of acute appendicitis like ultrasonography, computed tomography (CT), MRI. According to some studies ultrasound has a sensitivity ranging from 49 to 90%, a specificity ranging from 47 to 100%.¹⁰

As is in the study, there is a significant difference between the positive and negative predictive value for diagnosing appendicitis by ultrasonography, which strongly emphasizes the already proven fact that a positive ultrasonography for appendicitis strongly favors an inflamed appendix while a negative ultrasonography is not sufficient to rule out the diagnosis of acute appendicitis.¹¹ The present study correctly classified 88.65% of all patients with proven histological appendicitis as per ALVARADO score evaluation. This study showed a sensitivity and specificity of ALVARADO scoring system as of 93.9% and 100% respectively while ultrasonography had a sensitivity of 75.51% and specificity of 100%.

ALVARADO scoring system is a simple scoring system, based on simple, easily obtainable parameters for rapid and accurate diagnosis of acute appendicitis. Although ultrasound has a good specificity, the low sensitivity rules out its routine use in clinical cases and it can never replace a surgeon's clinical judgment.

In Levis et al series of 1000 cases, the incidence of acute appendicitis was found to occur most commonly in the age group of 20-30 years in both males and females. The male to female ratio was 3:2. In our series, the maximum incidence was found in the age group of 20 to 30 years. (Figure 1). It has been established beyond doubt by several authors, that male Sex predominated over female in the incidence of acute appendicitis.

Pain was a complaint in all the cases in this study. The initial location of pain in most cases (59%) presented with pain around umbilicus followed by (41%) in the right lower quadrant and 98% of the patients lately presented with pain in the right iliac fossa, which adds a diagnostic point of acute Appendicitis. (Table 1).

Anorexia was present in 88% of patients in present series. Anorexia nearly always accompanies appendicitis (Table 2). Nausea was present in 87% of Cases and vomiting in 83% of cases in present series (Table 3). Right iliac fossa tenderness was present in all the cases 100% at the time of presentation, a major contribution for diagnosis of Acute Appendicitis (Table 4).

Fever was present in 48 cases (48%) in present series in the major of cases fever was of low grade. W. B. C. count more than 10,000 cells/cumm was found in 50% of cases and only 2% it was raised above 20,000 Cells/ cumm (Table 5). In a study by Puylaert BCM et al 88.5% of the patients on ultrasound were reported Visualisation of the appendix in another study by Gallindo Galligo et al 82% of the patients reported with Visualisation of appendix.⁸ In the present series, graded tenderness over the McBurney's point by transducer was 88% which is the good diagnostic feature of acute appendicitis. According to Puylaert BCM et al graded tenderness over the McBurney's by transducer was 89% in the present series 88% of patients are reported as local adynamic ileus in ultrasound.³ (Figure 2).

In the present series 12% of the patients were reported as normal study of ultrasound and use has a role excluding the diagnosis of acute appendicitis. In the present study USG findings showed 88% sensitivity and 88% specificity in diagnosing acute appendicitis (Table 6). In this series 87% are Males and 94.7% were females of score 7 or >7 (Table 7). In the present series 88.65% (86) of the patients are histopathologically confirmed (Table 8). Condition of appendix is shown in (Figure 3). To prove accuracy of scoring, ultrasound sensitivity and specificity, histopathological confirmation is needed.

CONCLUSION

The Alvarado scoring system combined with ultrasound can therefore be used as a cheap and inexpensive way of confirming acute appendicitis thus reducing negative appendectomy rate. The overall specificity of abdominal USG in the diagnosis of acute appendicitis was 88.09% and sensitivity was 95.37%. History and clinical examination was more diagnostic.

Ultrasonography increases the diagnostic accuracy in patients with suspected acute appendicitis to the tune of 90-95%. Alvarado score with less than 6 leads to more than 25% negative appendectomy rate. If the scoring is above 7, the overall accuracy of diagnosis of acute appendicitis goes up to 90% with positive histopathological findings.

To prove accuracy of scoring, ultrasound sensitivity and specificity, histopathological confirmation is needed. It should be emphasized that USG does not replace clinical diagnosis; USG helps in diagnosing other causes of RIF pain which helps. In excluding appendicular pathology to avoid negative appendectomy.

Funding: No funding sources

Conflict of interest: None declared

Ethical approval: The study was approved by the Institutional Human Ethical Committee (IHEC), PESIMSR.

REFERENCES

1. Addiss DG, Shaffer N, Fowler BS, Tauxe RV. The epidemiology of appendicitis and appendectomy in United States. *Am J Epidemiol.* 1990;132(5): 910-25.
2. Fitz RH. Perforating inflammation of the vermiform appendix with special reference to its early diagnosis and treatment. *Trans. Assoc. Am. Physicians.* 1886;1(184):321.
3. Reddy GVB, Subramanyam VV, Veersalingam B, Sateesh S, Bangla G, Rao PS. Role of Alvarado score in the diagnosis of acute appendicitis. *Int J Res Med Sci.* 2013;1:404-8.
4. Singh CA, Singh AP, Sajith BSM, Gaharwar APS. Role of Alvarado score in diagnosis and management of acute appendicitis. *Int J Sci Stud.* 2016;4(6):173-7.
5. Sharma R, Kasliwal DK, Sharma RG. Evaluation of negative appendectomy rate in cases of suspected acute appendicitis and to study the usefulness of ultrasonography in improving the diagnostic accuracy. *Indian J Surg.* 2007;69:194-7.
6. Alvarado A. A Practical Score for early diagnosis of acute appendicitis, *Ann. Emerg. Med.* 1986;15(5):557-64.
7. Giljaca V, Nadarevic T, Poropat G, Nadarevic VS, Stimac D. Diagnostic Accuracy of Abdominal Ultrasound for Diagnosis of Acute Appendicitis: Systematic Review and Meta-analysis. *World J Surg.* 2017;41:3792-7.
8. Puylaert JBCM. Acute appendicitis-US evaluation using Graded compression, *Radiol.* 1986;158:355-60.
9. Nasiri S, Mohebbi F, Sodagari N, Hedayat A. Diagnostic values of ultrasound and the Modified Alvarado Scoring System in acute appendicitis. *Int J Emerg Medicine.* 2012;5:26.
10. Taj-Adean KAH. Sensitivity, Specificity and predictive values of ultrasonography in the diagnosis of acute appendicitis. *Medic J Babylon.* 2008;5(3-4):595-600.
11. Parsijani JP, Zarandi PN, Abbasi HR, Bolandparvaz S. Accuracy of Ultrasonography in Diagnosisng Acute Appendicitis. *Bull Emerg Trauma.* 2013;1(4):158-63.
12. Schwartz SI, Appendix, In: Schwartz SI, ed, *Principles of Surgery*, 10th ed. New york: Megraw Hill. 2015:1241-62.
13. Abu-Yousf MM, Phuillips ME, Franken EA, Al-Jurf AS, Smith WL; Sonography of acute appendicitis: a critical review: *Crit Rev Diagn Imaging.* 1989;29(4):381-408.
14. Gallindo G, Fadrique N, Calleja F. Evaluation of ultrasonography and clinical diagnostic scoring in suspected appendicitis. *Br J Surg.* 1998;85:3740.
15. Mohanty S, Kaushik SI, Evaluation of modified Alvarado score in decreasing negative appendectomy rate-our experience, *IJS.* 2000;62(5):342-3.
16. Geryk B, Kubikova E, Jakubovsky J; clinical histopathologic picture of acute appendicitis in children; *Rozhchir.* 2000;79(5):211-4.
17. Bhattacharjee PK, Chowdary T, Roy D. Prospective Evaluation of modified Alvarado Score for diagnosis of acute appendicitis: *J Ind Medic Association.* 2002;100(5):310-1.
18. George Mathews John, Siba Prasad Pattanayak, Charan Panda, K. Raja Ram Mohan Rao, Evaluation of Ultrasonography as a Useful Diagnostic Aid in Appendicitis. *IJS* 2002;64(5):436-9.
19. Pieper R, Kager L. The incidence of acute appendicitis and appendectomy. *Acta Chir Scand.* 1982;148:45-9.
20. Doraiswamy NV. Leucocyte counts in the diagnosis and prognosis of acute appendicitis in children. *British Journal Surg.* 1979;66(11):782-4.
21. Kallan M, Talbot D, Cunliffe WJ, Rich AJ, "Evaluation of modified alvarod Score in diagnosis of Acute Appendicitis : A prospective study ". *Ann, RCS of Engl.* 1994;76(6):418-9.
22. Owen TD, William H. Stiff G, Jenkenson LR, Rees B1: Evaluation of Alvarado Score in Acute Appendicitis: *J Social Medic.* 1992;85,87-8.
23. Elongovan S. Clinical and laboratory findings in acute appendicitis in the elderly, *J Am Board Fam Pract.* 1996;9:75-8.
24. Jeffreery RB Jr, Laing FC, Townsend RR. Acute appendicitis: sonographic criteria based on 250 cases. *Radiol.* 1988;167:327-9.
25. Zeidan BS, Wasser T, Nicholas GG. Ultrasonography in the diagnosis of acute Appendicitis. *J R Coll Surg Edinb.* 1997;42:24-6.
26. Fa EM, Cronan JJ. Compression ultrasonography as an aid in the differential diagnosis of appendicitis. *Surg Gynecol Obstet.* 1989;169:290-8.
27. Adams DH, Fine C, Brooks PC. High-resolution real-time ultrasonography: A new tool in the diagnosis of acute appendicitis. *Am J Surg.* 1988; 155(1):93-7.

Cite this article as: Mudavath K, Thinagan K. A study on the clinical and sonological correlation in the diagnosis and management of acute appendicitis in a tertiary care centre. *Int Surg J* 2019;6:2053-7.