

Original Research Article

Splenectomy in sickle cell haemoglobinopathies

Brajamohan Mishra, Malaya Krishna Nayak*, Sandeep Mishra, Itishree Das

Department of Surgery, VIMSAR, Burla, Odisha, India

Received: 05 February 2019

Accepted: 09 March 2019

***Correspondence:**

Dr. Malaya Krishna Nayak,

E-mail: drmalayanayak@gmail.com

Copyright: © the author(s), publisher and licensee Medip Academy. This is an open-access article distributed under the terms of the Creative Commons Attribution Non-Commercial License, which permits unrestricted non-commercial use, distribution, and reproduction in any medium, provided the original work is properly cited.

ABSTRACT

Background: Sickle cell disease is one of the common haemoglobinopathies in the world. Among its various clinical presentations, splenic complications are associated with high morbidity and substantial mortality, the only effective preventive strategy for which is prophylactic splenectomy. The aim of the present study was to observe the safety and effectiveness of splenectomy to prevent frequent requirement of hospitalizations, blood transfusions and splenic complications in patients of sickle cell disease.

Methods: The study was carried out in 72 patients of SCD with splenomegaly who underwent splenectomy for some indication in the surgery department of VSSIMSAR, Burla during the period from October 2016 to September 2018. Their preoperative baseline hematological parameters and frequency of transfusion requirement was compared with postoperative status.

Results: Of these 72 SCD patients, 49 (68.7%) patients had repeated requirement of blood transfusion and hypersplenism, 22 (30.5%) patients had history of one or more episodes of splenic sequestration crises, one patient had splenic abscess. After splenectomy the mean increase in haemoglobin level, TLC and TPC was respectively 2.83 ± 0.9 gm%, 1.7 ± 0.8 lac/cmm and 2726 ± 1618 /cmm. Operative mortality was 0%. None of the patients required any blood transfusion and no major postoperative complications during 6 months follow up period.

Conclusions: The morbidity of the patients of SCD in terms of repeated hospitalizations, blood transfusion, living with a huge spleen, accompanying symptoms and its complications can be effectively minimized by the elective splenectomy. With good preoperative preparation and post-operative management, splenectomy in SCD patients is a safe procedure with minimal risk of post-operative complications.

Keywords: Sickle cell disease, Hypersplenism, Splenectomy

INTRODUCTION

Sickle cell disease is one of the common haemoglobinopathies in the world.¹ It is an inherited structural abnormality of haemoglobin, a most common monogenic disorder with autosomal recessive inheritance globally.^{2,3} Based on 1981 census figures of population in India, it was estimated that there were 24,34,170 carriers and 1,31,375 sickle cell homozygotes among the tribes in India.^{1,4} The spleen plays a central role in the pathology of sickle cell disease which undergoes gradual fibrosis due to microvascular occlusion.^{3,4} During this, there may

occur episodes of acute splenic sequestration crisis, hypersplenism, massive splenic infarction and splenic abscess which are associated with an increased morbidity and substantial mortality too.⁴ The Asian haplotype of HbS mutation recognized in India is in many ways different from the African counterpart. It is associated with high level of HbF which has been suggested to be one of the causes of persistent splenic enlargement in India.^{2,4,5} This makes the patients vulnerable to suffer life threatening splenic complications, one of the effective preventive strategies of which, is elective splenectomy. This study was carried out to observe the post-operative

changes in haematological parameters and complications in 72 patients of sickle cell haemoglobinopathy who underwent splenectomy in the department of general surgery, VSSIMSAR, Burla, a tertiary health care cum research institute in the western region of state of Odisha, India.

Aim

The aim of the study was to observe the post-operative improvements in haematological parameters and the decrease in the complications in patients of sickle cell haemoglobinopathy, following elective splenectomy.

METHODS

The study was carried out in the patients of sickle cell disease who underwent splenectomy in the department of general surgery, VSSIMSAR, Burla during the period from October 2016 to September 2018. This included 72 patients whose age at presentation, sex, indication of splenectomy, preoperative haematological parameters and frequency of blood transfusion were recorded. The diagnosis of sickle cell disease was confirmed in all the patients by high performance liquid chromatography test and haemoglobin electrophoresis. Routine investigations were carried out to rule out any comorbidities. All the patients were evaluated with ultrasonography of the abdomen and pelvis to note the spleen size, presence of spleneculi and pathology of other abdominal organs if any. Preoperative vaccination against pneumococci, *Haemophilus influenzae* type B and meningococci was offered to all the patients 2 weeks prior to surgery. The haemoglobin level was brought up to ≥ 10 gm% by preoperative whole blood transfusion. Appropriate blood components or whole blood were reserved anticipating the need in the intra or post-operative period. Preoperative prophylactic antibiotics were administered in the operating room. Open splenectomy was done in all of the patients with a left subcostal incision under general anaesthesia. They were kept under close monitoring in the immediate and early post-operative period for any complications and were discharged at around 6th post-operative day with advice regarding vaccination schedule and prompt seeking of medical attention at the onset of symptoms of infection or any crisis. The patients were followed up at 1 month, 3 months, and 6 months after the surgery with observation of the haematological status and requirement of blood transfusion and hospitalization during that period and the findings were compared with preoperative levels. The pre and post-operative findings were compared by appropriate statistical analytical tests.

RESULTS

The demographic characters of these 72 patients are represented below in Table 1. The mean age of presentation was 12.9 ± 6.3 years with 50% of the patients presenting in the second decade and 16.6% in their third decade also.

Table 1: Demographic characters.

Age (years)	Number of patients	Percentage (%)
≤ 10	24	33.3
11-20	35	48.6
21-30	12	16.6
≥ 30	01	1.3

49 (68.05%) patients had repeated requirement of blood transfusion and hypersplenism as the indication for splenectomy, 22 (31.9%) patients had history of one or more episodes of splenic sequestration crises, one patient had splenic abscess.

The average preoperative haemoglobin was 6.56 ± 0.9 gm%, the total WBC count was around $7176 \pm 2245/\text{mm}^3$, total platelet count was 2.13 ± 0.57 lac/ mm^3 . Mean rate of blood transfusion preoperatively was 9.2 per year. The average spleen size of the patients was 17.5 ± 1.46 cmm as measured by ultrasonography.

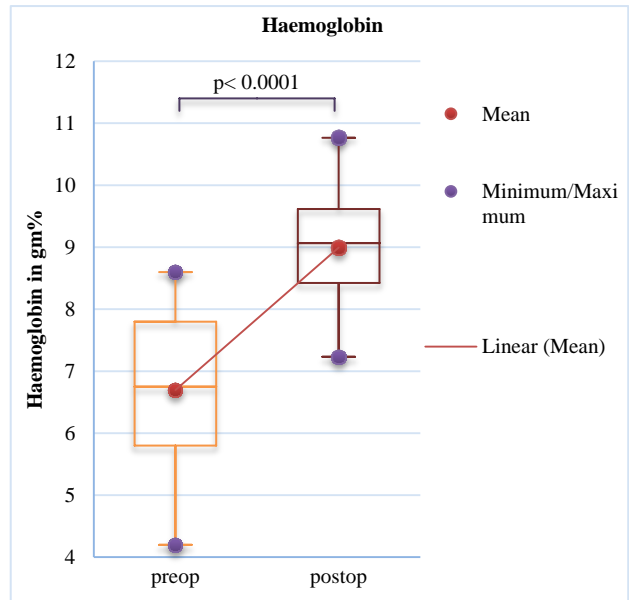


Figure 1: Pre and post-operative haemoglobin.

Table 2 Changes in post-splenectomy haematological parameters.

Parameter	Pre-splenectomy Mean \pm SD	Post-splenectomy Mean \pm SD	Mean change \pm SD	P value
Haemoglobin (gm%)	6.56 \pm 0.9	9.44 \pm 0.5	2.83 \pm 0.9	<0.0001
TLC (per cmm)	7176 \pm 2245	9293 \pm 928	2726 \pm 1618	<0.0001
TPC (per cmm)	2.13 \pm 0.57	3.6 \pm 0.5	1.7 \pm 0.8	<0.0001

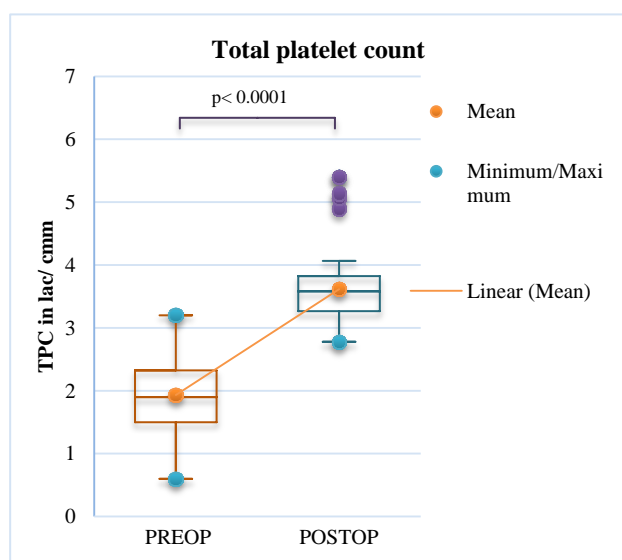


Figure 2: Pre and post-operative TPC.

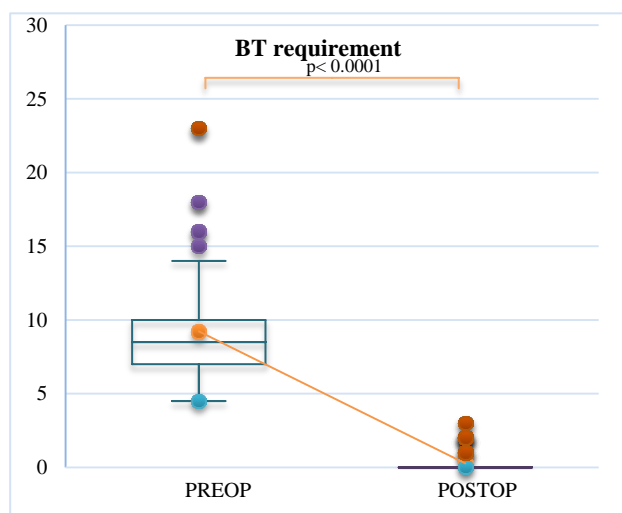


Figure 3: Pre and post-operative transfusion requirement.

All of the patients underwent complete splenectomy by open method. Operative mortality was 0%. Average duration of post-operative stay in the hospital was 7 days. 10 patients had fever and 8 patients had surgical site infections during this period and were managed conservatively. During the 6 months follow up period, average (mean of the values observed at 1 month, 3 months and 6 months post-operatively) post-operative haemoglobin was 9.44 ± 0.5 gm% (Figure 1), TLC 9293 ± 928 /cmm, TPC 3.6 ± 0.5 lac/cmm (Figure 2). The average rise in postoperative haemoglobin was 2.83 ± 0.9 gm%, TLC raised by 2726 ± 1618 /cmm, TPC raised by 1.7 ± 0.8 /cmm (Table 2). Wilcoxon signed rank test was used for comparison between pre and post-operative data ($p < 0.0001$).

Mean requirement of blood transfusion in the 6 months post-operative period was 0.264 with 25th quartile being 0

and 75th quartile 0 (Figure 3). Only three patients required hospitalization for upper respiratory tract infection in the 6 months follow up period, which were managed with standard antibiotics and discharged in stable conditions. One patient suffered two episodes of painful crisis on 20th and 45th post-operative day and was managed with analgesics and blood transfusion.

DISCUSSION

The splenic complications lie behind the major part of the pathological events in the early life of sickle cell disease patients which are acute sequestration, hypersplenism, splenic infarction leading to functional asplenia, splenic abscess. Acute splenic sequestration crisis is known to be the most common cause of early deaths in these patients³. The spleen undergoes progressive fibrosis at variable rates in different patients of African origin. But the Asian haplotype of HbS mutation is quite different from the African type. The Asian haplotype, though causes a milder illness, is associated with high level of foetal haemoglobin which has been shown to be one of the causes of persistent splenomegaly.^{4,5} The greater frequency and later peak incidence of splenomegaly in association with hypersplenism has been documented in Indian homozygous sickle cell disease patients.^{2,5} The late persistent splenomegaly adds to the morbidity of the patients by predisposing them to the complications as above. Splenic enlargement does not imply normal function, and the enlarged spleen may act only as a reservoir for blood with markedly deranged reticulo-endothelial system function.⁶

Acute splenic sequestration is characterized by a tender, rapidly enlarging spleen due to the trapping of sickled erythrocytes and other blood constituents. This may lead to shock due to loss of effective circulating volume and fall in the haemoglobin concentration at least 2 g/dl from baseline, usually with evidence of reticulocytosis and often moderate to severe thrombocytopenia.^{7,8} The condition is potentially fatal and requires prompt resuscitation and transfusions. However, recurrence carries a 20% mortality rate and can occur in 50% of those who survive.⁹ The natural history and prognosis of this fatal complication in our country is yet to be studied. As a means to prevent future acute splenic sequestration crisis, elective splenectomy has been indicated in children older than 2 or 3 years of age after the first episode of the crisis.^{10,11}

Hypersplenism is defined as a clinical syndrome characterised by splenic enlargement, any combination of anaemia, leukopenia or thrombocytopenia, compensatory bone marrow hyperplasia and improvement after splenectomy. The patients become transfusion dependent to maintain haemoglobin level. Chronic hypersplenism may occur as early as 1 year but is most common between 5 and 10 years and is unusual after 15 years.¹² But in our study hypersplenism was found to persist

beyond 15 years in 8 out of 72 (11%) patients of which one patient presented at 30 years of age.

Though chronic transfusion remains another option in dealing with these complications, the post transfusion reduction of the load of sickled cells lessens the possibility of splenic atrophy and retains the risk of subsequent sequestration attacks. Chronic repeated transfusion of blood or blood products carries its own risks of alloimmunisation, blood borne infections, transfusion reactions, iron overload etc. The requirement of frequent admissions for transfusion is an added stress on the part of the patient and their parents and also a burden on the healthcare system in view of the low availability of matched blood. In view of this, elective splenectomy appears a more rational treatment option. But this is often avoided in the hope that the spleen will face the natural fate of autoinfarction in sickle cell disease patients and the patients need not be offered a major surgical intervention and be deprived of the immunological role of spleen in combating different infections. As stated above the spontaneous splenic atrophy has been less frequent in Indian variety of the disease. The study of splenic function by colloid scan by Pearson and colleagues demonstrated that in children with SS disease, after each episode of sickle cell crisis, pitted red cell count increases indicating the gradual loss of splenic function with every attack. So the return of normal immunological function of the spleen after episodes of crisis is unlikely.¹³⁻¹⁵ With good pre and post-operative care splenectomy appears to be a safe, effective and better option in the management of patients of sickle cell haemoglobinopathies with splenic complications in this region. The risk of post-splenectomy sepsis found out in past studies is approximately 2% but increases substantially if splenectomy is performed before 4 years of age¹⁶⁻¹⁸. None of the patients included in our study developed overwhelming post-splenectomy sepsis in the six months post-operative follow up period. However, long term follow up studies are needed to know the late complications and the post-splenectomy quality of life of the patients.

Splenic abscess is rare owing to the early autosplenectomy in sickle cell disease but the persistent enlarged spleen is prone to develop this complication. The single patient of splenic abscess in our study, a 5 years girl, had multiple hypodense lesions in the splenic parenchyma of largest size 3.8 cm×2.8 cm with contrast enhancement, pancytopenia and high reticulocyte count in association. She was managed by open splenectomy. Unilocular abscesses <3 cm in size with thin liquid content can be safely drained under radiological guidance.¹⁹ When abscess size is >10 cm or non-surgical treatment has failed, splenectomy has been shown to be a safe alternative to treat the condition.²⁰ As opposed to other causes of splenic abscess, those developing in patients of sickle cell disease should be managed by splenectomy because it is unnecessary to preserve a complication prone nonfunctional spleen in these

patients. Those patients who are unfit for laparotomy can be taken up for drainage of abscess under radiological guidance as a temporary measure.

In our study the improvement in the haematological parameters i.e. the haemoglobin level, total leukocyte count and total platelet count after splenectomy was significant (Table 2) and the incidence of post-operative transfusion requirement was nil (Figure 3) and post-operative hospitalization for infectious complications or other crises was also negligible. The perioperative mortality was nil. Only 8 out of 72 (11%) cases had surgical site infection. Though no quantitative data has been collected to support, the parents of 24 patients reported that the growth and general wellbeing of their children improved after surgery. This may be explained by the fact that the t½ of red cells increases in splenectomised individuals which reduces the haematopoietic load on the bone marrow competing with growth.²¹ The patients get relief from pain and the weight of a heavy spleen, they would no more be frequent transfusion dependent, and the stomach would be relieved of the compression by the huge spleen which caused early satiety before surgery. This goes parallel with the observation by Serjeant et al of the acceleration in linear growth after splenectomy in patients of hypersplenism.²²

Keeping in view the complications associated with repeated hospital admissions and chronic blood transfusion and the advantages of splenectomy in reducing transfusion requirement (Figure 3), relieving pain and discomfort from mechanical pressure, improved growth in addition to the significant changes in haematological parameters (Figure 1, 2), the later mode of treatment appears more favorable for these patients.

The safety of splenectomy has also been shown by previous studies that with modern anaesthetic and surgical techniques, elective splenectomy appears to be a safe and fairly minor procedure and the arguments against splenectomy in the patients of SCD with splenic complications like acute splenic sequestration crisis and hypersplenism are less convincing.²³

CONCLUSION

Although splenectomy has not been proven to increase survival, it significantly reduces the morbidity of the patients of SCD by reducing frequency of hospitalization for transfusion, giving relief from a huge spleen and its accompanying symptoms and preventing the dreaded complications of future acute splenic sequestration crisis. With good preoperative preparation and post-operative management, splenectomy in SCD patients is quite a safe procedure with minimal risk of post-operative major complications.

Funding: No funding sources

Conflict of interest: None declared

Ethical approval: The study was approved by the Institutional Ethics Committee

REFERENCES

1. Rao VR. Genetics and epidemiology of sickle cell anemia in India. *ICMR Bull*. 1988;18:87-90.
2. Parmar D, Likhar KS. Prevalence of Splenomegaly in Sickle cell Anemia patients in relation to Haemoglobin F. *IJRRMS*. 2014;4(1):12-5.
3. Serjeant GR, Chin N, Asnani MR, Serjeant BE, Mason KP, Hambleton IR, et al. Causes of death and early life determinants of survival in homozygous sickle cell disease: The Jamaican cohort study from birth. *PLoS ONE*. 2018;13(3):e0192710.
4. Serjeant GR. Evolving locally appropriate models of care for Indian sickle cell disease. *Indian J Med Res*. 2016;143(4):405–13.
5. Kar BC, Satapathy RK, Kulozik AE, Kulozik M, Sirm S, Serjeant BE, et al. Sickle cell disease in Orissa State, India. *Lancet*. 1986;2:1198-201.
6. Powars DR, Pagelow CH. The spleen in sickle cell disease and thalassemia. *Am J Pediatr Hematol Oncol*. 1979;1(4):343–51.
7. Ballas SK, Lieff S, Benjamin LJ, Dampier CD, Heeney MM, et al. Definitions of the phenotypic manifestations of sickle cell disease. *Am J Hematol*. 2010;85:6-13.
8. Rezende PV, Viana MB, Murao M, Chaves AC, Ribeiro AC. Acute splenic sequestration in a cohort of children with sickle cell anemia. *J Pediatr (Rio J)*. 2009;85:163-9.
9. Stuart MJ, Nagel RL. Sickle-cell disease. *Lancet*. 2004;364:1343.
10. al-Salem AH, Qaisaruddin S, Nasserallah Z, al Dabbous I, al Jam'a A. Splenectomy in patients with sickle-cell disease. *Am J Surg*. 1996;172:254-8.
11. Sorrells DL, Morrissey TB, Brown MF: Septic complications after splenectomy for sickle cell sequestration crisis. *Pediatr Surg Int*. 1998;13:100.
12. Serjeant GR. Sickle-cell disease. *Lancet*. 1997;350:725–30.
13. Pearson HA, Spencer RP, Cornelius EA. Functional asplenia in sickle cell anemia. *N Engl J Med*. 1969;281:923-6.
14. Pearson HA, McIntosh S, Ritchey AK, Lobel JS, Rooks Y, Johnston D. Developmental aspects of splenic function in sickle cell diseases. *Blood*. 1979;53:358-65.
15. Casper JT, Koethe S, Rodney GE, Thatcher LG. A new method for studying splenic reticuloendothelial dysfunction in sickle cell disease patients and its clinical application: a brief report. *Blood*. 1976;47:183-8.
16. Wright JG, Hambleton IR, Thomas PW, Duncan ND, Venugopal S, Serjeant GR. Postsplenectomy course in homozygous sickle cell disease. *J Pediatr*. 1999;134:304.
17. Emond AM, Morais P, Venugopal S, Carpenter RG, Serjeant GR. Role of splenectomy in homozygous sickle cell disease in childhood. *Lancet*. 1984;1:88.
18. Leshner AP, Kalpatthi R, Glenn JB. Outcome of splenectomy in children younger than 4 years with sickle cell disease. *J Pediatr Surg*. 2009;44:1134.
19. Maliyil J, Caire W, Nair R, Bridges D. Splenic abscess and multiple brain abscesses caused by *Streptococcus intermedius* in a young healthy man. *Proc (Bayl Univ Med Cent)*. 2011;24:195-9.
20. Alvi AR, Kulsoom S, Shamsi G. Splenic abscess: outcome and prognostic factors. *J Coll Physicians Surg Pak*. 2008;18:740-3.
21. Sprague CC, Paterson JCS. Role of the Spleen and Effect of Splenectomy in Sickle Cell Disease. *Blood*. 1958;13:569-81.
22. Singhal A, Thomas PW, Keatney T, Venugopal S, Serjeant GR. Acceleration in linear growth after splenectomy for hypersplenism in homozygous sickle cell disease. *Arch Dis Child*. 1995;72:227–9.
23. Topley JM, Rogers DW, Stevens MCG, Serjeant GR. Acute splenic sequestration and hypersplenism in the first five years in homozygous sickle cell disease. *Arch Dis Childhood*. 1981;56:765-9.

Cite this article as: Mishra B, Nayak MK, Mishra S, Das I. Splenectomy in sickle cell haemoglobinopathies. *Int Surg J* 2019;6:1371-5.