

Case Report

Inguinal hernia with ovary as content- laparoscopic repair in a Mayer–Rokitansky–Küster–Hauser syndrome patient: case report

Washim F. Khan, Yashwant S. Rathore*, Manjunath M. Pol, Gurpremjit Singh

Department of Surgical Disciplines, All India Institute of Medical Sciences, New Delhi, India

Received: 04 February 2019

Accepted: 09 March 2019

*Correspondence:

Dr. Yashwant S. Rathore,

E-mail: dryashvant.r@gmail.com

Copyright: © the author(s), publisher and licensee Medip Academy. This is an open-access article distributed under the terms of the Creative Commons Attribution Non-Commercial License, which permits unrestricted non-commercial use, distribution, and reproduction in any medium, provided the original work is properly cited.

ABSTRACT

Inguinal hernia is a common surgical disease. Ovary and fallopian tube are not frequently found as content of the hernia. A 18 year old female, diagnosed case of Mayer–Rokitansky–Küster–Hauser (MRKH) syndrome, presented with left sided reducible inguinal hernia for six months. Ultrasonography revealed absence of intra-abdominal left ovary and presence of ovary in the sac. She was planned for laparoscopic repair and total extra-peritoneal repair (TEP) was done. Ovary and adnexa may be content in groin hernia in females. Association of syndromes especially MRKH syndrome should be kept in mind in this group of patients. Laparoscopic total extra-peritoneal repair may be successfully attempted in this group of patients.

Keywords: Inguinal hernia, Content ovary, TEP, MRKH syndrome, Ovarian inguinal hernia

INTRODUCTION

Inguinal hernia is one of the most commonly seen surgical diseases worldwide. In comparison to male population, it is relatively uncommon in females. The incidence of female inguinal hernia is < 5% of total female population and indirect hernia is more common variety found in them.¹ Ideally any abdominal organ can herniate through the defect but most commonly intestine or omentum stay as content of hernia sac.² Urinary bladder, appendix, ovary, fallopian tube are seen as content rarely. Though rare, instances of ovary as content of groin hernia have been reported in literature and its incidence is very low in adult female population (<3%).² Most of the cases has been reported in newborn, infant and pediatric population and has been often found to be associated with congenital genitourinary tract anomalies.³⁻⁵

Mayer–Rokitansky–Küster–Hauser (MRKH) syndrome is a rare congenital anomaly and has been documented in 1

out of 5000 females.⁶ Very few cases of ovarian hernia with MRKH syndrome have been documented in literature till date.⁷ We report one such case of inguinal hernia with ovary and fallopian tube as content of the hernia sac in a diagnosed case of MRKH syndrome.

CASE REPORT

An 18 year old female presented with swelling in left groin for six months. The swelling was gradually progressive, increasing with coughing and straining, and used to get reduced on lying down. On examination, a diagnosis of left sided reducible, indirect, incomplete inguinal hernia was made. Ultrasonography revealed non-visualization of left ovary in abdomen and presence reducible inguinal hernia with a well-defined hypo-echoic ovary like structure with few tiny small cystic areas (possibly follicles), as a content of the sac. She was a known case of MRKH syndrome with left kidney agenesis which was diagnosed during evaluation for primary amenorrhoea 3 years ago. MRI done during that time revealed absent uterus and cervix with thin vagina

along with presence of bilateral normal intra-abdominal ovaries. She is hypertensive and controlled on amlodipine 5mg OD for the same duration of 3 years.

Routine blood investigations were within normal limits. Ultrasonography revealed non-visualization of left ovary in abdomen and presence of a reducible inguinal hernia with a well-defined hypo-echoic ovary-like structure with few tiny small cystic areas (possibly follicles), as a content of the sac.

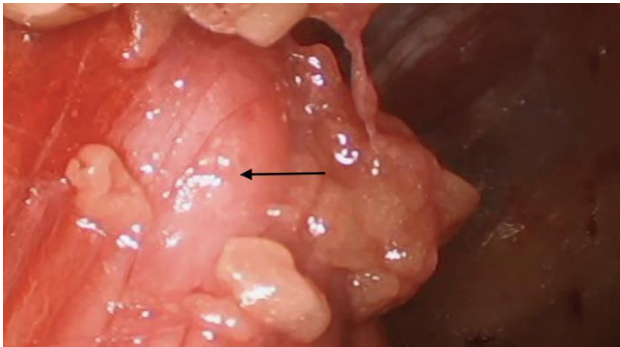


Figure 1: Intraoperative photograph showing ovary as the content of sac (arrow marking the ovary).

She was taken for surgery with a plan for total extra-peritoneal repair of hernia. Pre-peritoneal space was created with telescopic dissection after placement of Hasson's cannula. Contents of the sac were palpated with laparoscopic grasper and were found to be ovary with part of fallopian tube (Figure 1). Sac was reduced completely. After adequate dissection, a prolene mesh of 10×15 cms was placed in pre-peritoneal space and fixed with tacker at both medial and lateral side.

Postoperative recovery was uneventful. Patient was discharged on post-operative day one. A follow-up USG was done at two weeks and it showed normal ovaries bilaterally.

DISCUSSION

The incidence of groin hernia containing genital organs (e.g., the fallopian tube, ovary or uterus) is not a commonly seen phenomenon. Till date one of the largest retrospective series on content of inguinal hernias is by Gurer et al.² They reported that among 1,950 cases, ovaries and fallopian tubes accounted for 2.9% of the unusual contents of hernia sacs. 0.41% of patients showed a hernia sac containing only the fallopian tube. Though most of the patients in this series are adult, majority of articles in literature have reported this in pediatric population only.⁸

The mechanism of herniation of genital organs in groin hernia is not clear. Ozkan et al have suggested that weakness of the broad ligament and ovarian suspensory ligament may be a cause of herniation, which may be aggravated when abdominal pressure is increased.⁹ Ozbey

et al on the other hand has said that due to modified presentation of round ligament in a processus vaginalis, ovary in a hernia sac may be a descended gonad.¹⁰

Genetic or developmental abnormality has been found to be frequently associated with ovarian inguinal hernia.¹¹ Our patient was a young teenager with MRKH syndrome with left renal agenesis. Mohanty et al have previously documented a patient of MRKH syndrome presenting as ovarian inguinal hernia in a case report.¹¹

Ovary or tube as content of hernia is frequently associated with torsion, irreducibility, strangulation, gangrene etc.^{12,13} Pediatric patients being a majority in overall incidence of ovarian inguinal hernia, incidence of complication is also high. However, Gurer et al in their series have said that though most of the patients in their series were adults, oophorectomy/salpingo-oophorectomy could be avoided in only 3 out of 7 patients in their series.²

Most of the case reports and series in literature have described open surgical approach for inguinal hernia with ovary and or tube as content.^{2,9} Our patient being young and unmarried, we decided to perform laparoscopic repair (TEP) for her. Laparoscopic approach to such surgery has also been documented in literature before (both TAPP and TEP).^{14,15}

In conclusion, we reported a case of inguinal hernia of left ovary and fallopian tube in a teenage girl with MRKH syndrome. A laparoscopic approach with using TEP mesh repair was successful, with good cosmetic outcomes and less pain after surgery. Both ovary and the fallopian tube were preserved. Therefore, we suggest considering a laparoscopic approach to reduce herniated adnexae in groin hernia patients.

Funding: No funding sources

Conflict of interest: None declared

Ethical approval: Not required

REFERENCES

1. Kark AE, Kurzer M. Groin hernias in women. *Hernia*. 2008;12(3):267–70.
2. Gurer A, Ozdogan M, Ozlem N, Yildirim A, Kulacoglu H, Aydin R. Uncommon content in groin hernia sac. *Hernia*. 2006;10(2):152–5.
3. Karadeniz Cerit K, Ergelen R, Colak E, Dagli TE. Inguinal Hernia Containing Uterus, Fallopian Tube, and Ovary in a Premature Newborn. *Case Rep Pediatr*. 2015;2015:807309.
4. Wiley J, Chavez HA. Uterine adnexa in inguinal hernia in infant females: report of a case involving uterus; both uterine tubes and ovaries. *West J Surg Obstet Gynecol*. 1957;65(5):283–5.
5. Huang CS, Luo CC, Chao HC, Chu SM, Yu YJ, Yen JB. The presentation of asymptomatic palpable

- movable mass in female inguinal hernia. *Eur J Pediatr.* 2003;162(7-8):493-5.
6. Herlin M, Bjørn A-MB, Rasmussen M, Trolle B, Petersen MB. Prevalence and patient characteristics of Mayer-Rokitansky-Küster-Hauser syndrome: a nationwide registry-based study. *Hum Reprod.* 2016;31(10):2384-90.
7. Mohanty HS, Shiroadkar K, Patil AR, Rojed N, Mallarajapatna G, Nandikoor S. A rare case of adult ovarian hernia in MRKH syndrome. *BJR Case Rep.* 2017;3(3):20160080.
8. Okada T, Sasaki S, Honda S, Miyagi H, Minato M, Todo S. Irreducible indirect inguinal hernia containing uterus, ovaries, and Fallopian tubes. *Hernia.* 2012;16(4):471-3.
9. Ozkan OV, Semerci E, Aslan E, Ozkan S, Dolapcioglu K, Besirov E. A right sliding indirect inguinal hernia containing paraovarian cyst, fallopian tube, and ovary: a case report. *Arch Gynecol Obstet.* 2009;279(6):897-9.
10. Ozbey H, Ratschek M, Schimpl G, Höllwarth ME. Ovary in hernia sac: prolapsed or a descended gonad? *J Pediatr Surg.* 1999;34(6):977-80.
11. Manjunath BG, Shenoy VG, Raj P. Persistent müllerian duct syndrome: How to deal with the müllerian duct remnants - a review. *Indian J Surg.* 2010;72(1):16-9.
12. Ballas K, Kontoulis T, Skouras C, Triantafyllou A, Symeonidis N, Pavlidis T, et al. Unusual findings in inguinal hernia surgery: Report of 6 rare cases. *Hippokratia.* 2009;13(3):169-71.
13. Merriman TE, Auldish AW. Ovarian torsion in inguinal hernias. *Pediatr Surg Int.* 2000;16(5-6):383-5.
14. Kim JH, Chong GO, Lee JY, Lee YH, Hong DG, Park SY, et al. Laparoscopic repair of indirect inguinal hernia containing endometriosis, ovary, and fallopian tube in adult woman without genital anomalies. *Obstet Gynecol Sci.* 2014;57(6):557-9.
15. Park YH, Jung EJ, Byun JM, An MS, Kim YN, Lee KB, et al. Laparoscopic total extraperitoneal hernia repair of fallopian tube indirect inguinal hernia in reproductive aged woman: a case report. *Obstet Gynecol Sci.* 2017;60(6):608-11.

Cite this article as: Khan WF, Rathore YS, Pol MM, Singh G. Inguinal hernia with ovary as content-laparoscopic repair in a Mayer-Rokitansky-Küster-Hauser syndrome patient: case report. *Int Surg J* 2019;6:1421-3.