

Research Article

Evaluation of large duodenal ulcer perforation with special reference to omentopexy and omental plugging

Suman Parihar*, P.N. Mathur, C.P. Joshi

¹Department of General Surgery, Geetanjali Medical College & Hospital, Udaipur, Rajasthan

Received: 29 April 2016

Accepted: 06 May 2016

*Correspondence:

Dr. Suman Parihar,

E-mail: pariharsuman209@gmail.com

Copyright: © the author(s), publisher and licensee Medip Academy. This is an open-access article distributed under the terms of the Creative Commons Attribution Non-Commercial License, which permits unrestricted non-commercial use, distribution, and reproduction in any medium, provided the original work is properly cited.

ABSTRACT

Background: Duodenal perforation is complication of peptic ulcer disease and is common surgical emergency. The giant perforation (more than 2 cm) with long duration is having high mortality. This study in medical college setup where surgical emergencies are catered all the time is carried out to compare the success between omental plugging and omentopexy in emergency setup. The peptic ulcer disease in southern region of state of Rajasthan is very prevalent, may be because of food habits, smoking, and alcohol consumption.

Methods: The present study is a prospective, non-randomized case series study. The study was under taken in the Department of Surgery; Geetanjali Medical College & Hospital between years 2011 to 2013. Thirty cases who were found to have giant peptic perforation during laparotomy were selected for the study. Perforations repaired by omental plugging were taken as cases and those repaired by omentopexy were taken as control.

Results: In our study perforation was common in middle aged patients ranging from 30 to 50 years (56%). Personal habits like smoking and alcohol consumption contribute significantly in causing peptic perforation. In our series two female patients were non-smokers but had history of acid peptic disease. Duration and size of perforation is indicative of peritoneal contamination.

Conclusions: In large duodenal ulcer perforation, the technique of omental plugging for repair is effective and safe. This is a simple technique and can be performed rapidly even in high risk patients in emergency. This effectively closes the perforation and chances immediate re-leak are minimal.

Keywords: Giant peptic perforation, Omental plugging, Omentopexy

INTRODUCTION

Perforation is the most catastrophic complication of peptic ulcer.¹ It is the common surgical emergency. Most perforations occur a few hours after meal. The incidence of perforated peptic ulcer is approximately 7 to 10 cases per 100,000 populations per year. Perforation is present in about 7% of patients hospitalized for peptic ulcer disease and it is the first manifestation of disease in about 2% of patients with duodenal ulcer. In the duodenum, the ulcer that perforates are located anteriorly.²

Giant peptic perforations are defined as perforation of size equal to or greater than 2cm in diameter.¹ These perforations are considered hazardous because of the extensive duodenal tissue loss, friability of ulcer margins, surrounding tissue inflammation poor general condition of the patient and over -whelming sepsis due to bacterial peritonitis. These factors are said to preclude simple closure using omental patch, often resulting in postoperative leak or gastric outlet obstruction.³⁻⁵

Various methods apart from omentopexy have been described for management of giant perforations and they include partial gastrectomy, jejunal serosal patch,

jejunal pedical graft, omental plugging and proximal gastrojejunostomy.² Apart from omental plugging all other methods are more elaborate, time consuming and technically difficult to perform in emergency and serious patients.⁶

The present study was done to compare the success rate between omental plugging and simple repair with omentopexy in the emergency management of giant peptic perforations.

Risk factors

A strong association has been observed between the use of nonsteroidal anti-inflammatory drugs and perforated peptic ulcer. A second risk factor for perforation is immuno suppression.⁷ Other risk factors include smoking, alcohol consumption, advancing age chronic obstructive lung disease, major burns and multiple organ system failure.⁸

Diagnosis

Perforated peptic ulcer is suspected following sudden abdominal pain, abdominal rigidity with obliteration of hepatic dullness. Definitive diagnosis is made by pneumoperitoneum in Roentgenograms taken in erect position. Exploratory laparotomy and closure of perforation is rational mainstay of treatment.⁹

There are several conventional options for dealing with a perforated peptic ulcer at laparotomy. The first option is simple closure, a method that can be used for a small perforation. The mortality rate ranges from 2.9-10 percent.³

The second option of closure with an omental patch, devised by Callen Jones in 1929 is the most widely used technique. In this a strand of omentum is drawn under an arch of full thickness sutures placed on either side of perforation.¹⁰

The real concern exists as to the safety of omental patch repair for closure of large perforations greater than 2 cm in diameter. In our setting of omental plugging, we commonly encounter cases of large duodenal perforation. Most of the patients present late usually 3-4 days after the onset of symptoms. Patient's condition is usually poor to withstand major surgical procedure. There is too much edema and induration around the perforation. The suture get cut through the inflamed duodenal wall and the omental patch does not seal the perforation or is rendered ischemic by tight sutures applied over it. This ultimately results in re leakage from the ulcer site causing high incidence of morbidity and mortality.

All these factors prompted us to adopt an alternative technique for the repair of large duodenal perforation of omental plugging. In this technique intraluminal invagination of omentum is done through the perforation

and this omental plug is secured by taking internal mattress sutures around the perforation. (Internal Trans fixation technique).

METHODS

The present study is a prospective, non-randomised case series study comparing the efficacy of omental plugging (described by Karanjia et al in 1993) and omentopexy (first described by Callen Jones in 1929 and later modified by Graham in 1937) in repair of giant peptic perforations (>2 cm in diameter).

The study was undertaken in department of surgery Geetanjali medical college Udaipur between year 2011 to 2013. Thirty cases who were found to have giant Peptic perforations during laparotomy were selected for the study. Patients repaired by omental plugging were taken as cases and patients repaired by omentopexy were taken as control.

All the patients were investigated for routine CBC, BT, CT, Biological investigations including Blood sugar, serum urea and creatinine, serum electrolytes, HbsAg, HIV and urine analysis was performed. Pre- operative Flat-plate X-ray of abdomen in erect position and X-ray chest P.A. were done.

Adequate preoperative treatment by giving I.V. fluids and broad spectrum antibiotics imidazole and proton pump inhibitor were given.

The abdomen was opened under general anaesthesia, through the upper midline incision. Operative findings regarding size and exact location of perforation, amount of peritoneal fluid, peritoneal soiling were noted .The cases were divided into study and control group. In the study group omental plugging and in control group omentopexy was done.

Omental plugging

A pedicle of omentum based on one of the omental vessels is prepared by separating it from rest of omental apron .The internal mattress sutures with silk are taken , First bite is taken from outside near the duodenal perforation away from indurate area and passed through the lumen. Then a bite of omentum is taken and needle is again passed through the perforation inside the lumen and taken out near the perforation, these sutures are kept loose, 3 to 4 such sutures are taken. These sutures when tied pull the omental pedicle into the lumen through the perforation forming an effective plug. (Figure 1, 2). Reinforcing seromuscular sutures are placed externally between the edge of perforation and the omentum, in between the already placed internal mattress sutures

Omentopexy

The perforation was sutured by applying three sutures of 2/0 silk and omental patch was reinforced over the suture line (GRAHAM'S PATCH). The Peritoneal cavity was drained by two tube drains –a right sub hepatic and a pelvic drain after thorough peritoneal toilet. Post operatively patients were kept on I.V. fluids, continuous nasogastric decompression, broad spectrum antibiotics, Imidazole and PPI. In most cases sub hepatic drain was removed on third day, Pelvic drain on 5th day. Ryle's tube was removed around 5th day and patient was allowed oral liquids by 6th postoperative day.

Patients were discharged on H.P. KIT for 2 weeks followed by PPI for 3 weeks. Patients were followed over a period of 3 and 6 months.

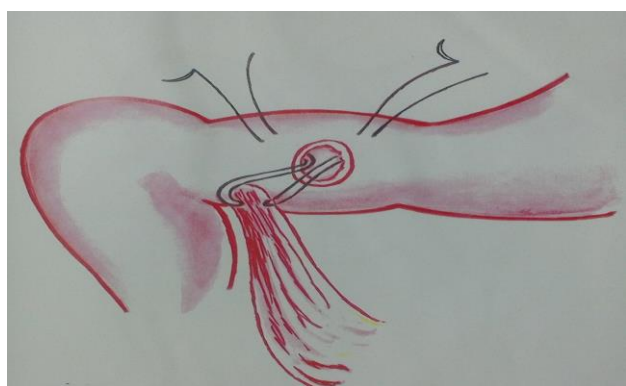


Figure 1: Suture passed into the lumen through perforation and taken out near first bite after taking omentum.

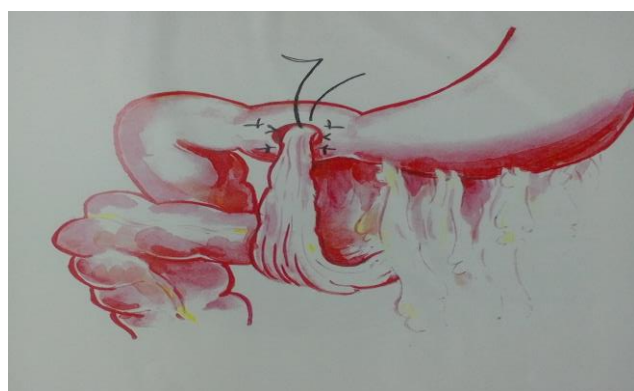

Figure 2: Completion of internal mattress suture and suture tied thus plugging the omental pedicle inside the perforation. Reinforce sutures taken between the perforation margin and omentum.

RESULTS

In our study perforation was common in middle aged patients ranging from 30 to 50 years (56%). Personal habits like smoking and alcohol consumption contribute significantly in causing peptic perforation. In our series

two female patients were non-smokers but had history of acid peptic disease. Duration and size of perforation is indicative of peritoneal contamination.

Table 1: Age group incidence.

Age in years	Number of patients	Percentage
20—30	4	13.33%
31 –40	8	26.65%
41 -50	9	29.03%
51-60	6	20 %
61 -80	3	10%

Table 2: Male female ratio.

Sex	Number of patient	Percentage
MALE	28	93.33%
Female	2	6.66%

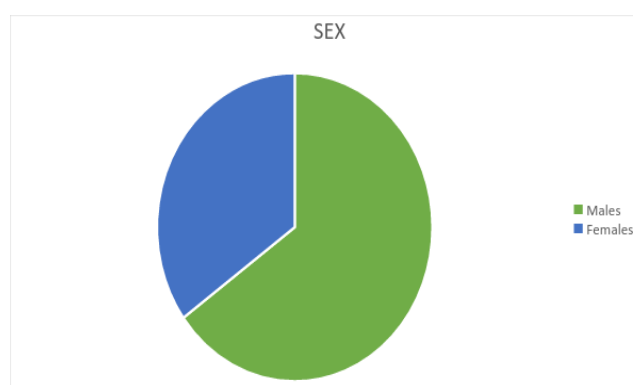


Figure 1: Showing male: female ratio.

Table 3: Urban/rural distribution.

Area	Number of Patient	Percentage
Urban	6	20%
Rural	24	80 %

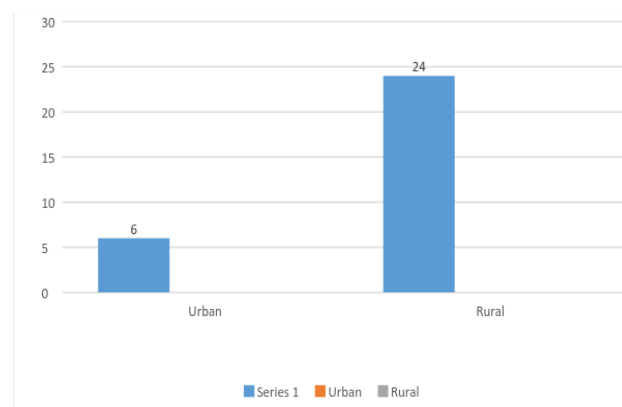
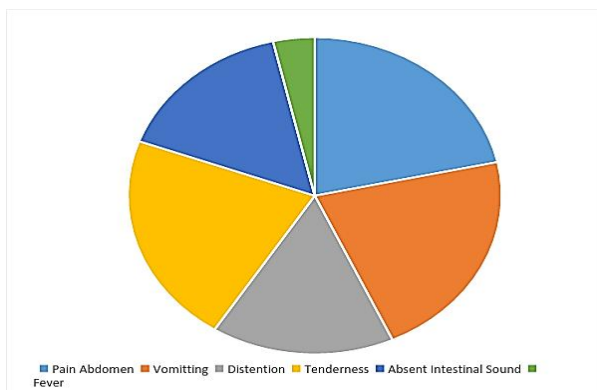


Figure 2: Urban/rural distribution.

Table 4: Showing sign and symptoms.

Sign and symptom	Number of patients	Percentage %
Pain abdomen	30	100
Vomiting	30	100
Distension	22	73.3
Tenderness guarding and rigidity	30	100
Absent intestinal sound	22	73.3
Fever	5	16.6

**Figure 3: Various signs and symptoms of perforation.****Table 5: Morbidity.**

Parameter	Omental plugging	Omentopexy	Significance
Wound Infection	2	3	Not significant
Intra-abdominal abscess	1	1	Not significant
Lung complication	2	3	Not significant

Table 6: Mortality.

Type of repair	Total no. of cases	Death within 24 hrs of surgery	Death >24 hrs	Total
Omental plugging	15	1	-	1
Omentopexy	15	1	2	3

DISCUSSION

Peptic perforation is a common emergency especially in this southern region of Rajasthan state. There is sharp decrease in elective surgery for peptic ulcer disease, but

the complication and emergency of disease such as perforation is commonly encountered and its treatment is surgical.⁵

In our study the perforation was common in middle aged patients ranging from 30-50 years of age (56 %), similar to other studies.^{1,6,9} Personal habits like smoking and alcohol contribute significantly in causing peptic perforation. In our series two female patients were non-smokers but had a history of acid peptic disease.

Duration and size of perforation is indicative of peritoneal contamination. Mortality in two patients in our study was mainly because of age, duration of perforation, amount of contamination and comorbidity. Both patients had omentopexy.

In our series three patients with omentopexy had re-leak of which one died within twenty four hours of surgery and other two patients died after twenty four hours in post-operative period. In omental plugging, one patient expired with in twenty four hours, because of severe septicemia and MODS .The common complications like wound infection, fever and chest complication were almost same in both groups as found in other study also.¹¹

Larger perforation were difficult to repair due to complex anatomy of duodenum and its proximity to pancreas, hence liable to break down of suture line.¹²

Omental plugging is a simple procedure based on principle that healthy vascularized tissue should be incorporated in the repair of any defect with tissue loss and with friable margins.¹² The procedure is simple can be performed in short time in seriously ill patients in an emergency situation.¹³

Omental plugging works on basic principle of physics, as the part of the omentum is taken inside the stomach, even with rise of intragastric pressure, the omentum is always remains in contact with gastric mucosa in contrast in omentopexy the repair is done from outside and so with rising intra gastric pressure the omental patch can be easily disturbed and the suture line can be disrupted causing a chance to re-leak.

CONCLUSION

To conclude for large duodenal ulcer perforation in patients the technique of omental plugging for repair is effective and safe. This technique is simple and can be performed rapidly even in high risk patients in emergency. This technique effectively closes the perforation and chances of immediate re-leak are minimal. The mortality rate excluding preexisting septicemia is lower in omental plugging making it a better choice.

Postoperative recovery of the patient is good and follow up of patients shows that there is little scarring or

cicatrizization of duodenal wall as proved by postoperative endoscopic study done after 3 and 6 months.

Funding: No funding sources

Conflict of interest: None declared

Ethical approval: The study was approved by the institutional ethics committee

REFERENCES

1. Jani K, Saxena AK, Vaghasia R. Omental plugging for large sized duodenal peptic perforation: a prospective randomized study of 100 patients. Southern Med J. 2006;99(5):467-71.
2. Stabile BE, Hardy HJ, Passaro E Jr. Kissing duodenal ulcer. Arch Surg. 1979;114(10):1153-6.
3. Gupta S, Kaushik R, Sharma R, Attri A. The management of large perforations of duodenal ulcers. BMC Surg. 2005;5:15.
4. Chaudhary A, Bose SM, Gupta NM, Wig JD, Khanna SK. Giant perforation of duodenal ulcer. Indian J gastroenterol. 1991;10:14-5.
5. Karanjia ND, Shanahan DJ, Knight MJ. Omental patching of a large perforated peptic ulcer: a new method. Br J Surg. 1993;80:65.
6. Khalil AR, Yunas M, Jan QA, Nisar W, Imran M. Graham's omentopexy in closure of perforated duodenal ulcer. J Med Sci. 2010;18(2):87-90.
7. Spons RK, Simmons RL, Rattazzile. Peptic ulcer disease in transparent recipients. Arch. 1974;109(2):193-7.
8. Debas HT, Sean J, Mulvihill. Complications of peptic ulcer. Maingot's Abdominal Operation Vol. 1. 10th edition. McGraw Hill Education; 1996:981.
9. Gupta BS, Talukdar RN, Neptune HC. Cases of perforated duodenal ulcer treated in college of medical sciences, Bharatpur over a period of 1 year. Kathmandu Univ Med J. 2003;1:166-9.
10. Rajes V, Chandra SS, Smile SR. Risk factors predicting operative mortality in perforated peptic ulcer disease. Trop Gastroenterol. 2003;24:148-50.
11. Hastings N, Machida R. Perforated peptic ulcer: results after simple surgical closure. Am J Surg. 1961;102:136-42.
12. Agarwal P, Sharma D. Repair of duodenal fistula with rectus abdominis musculo-peritoneal (RAMP) flap. Indian J Gastroenterol. 2004;23:143-4.
13. Sharma D, Saxena A, Rahman H, Raina VK, Kapoor JP. 'Free Omental Plug': a nostalgic look at an old and dependable technique for giant peptic perforations. Dig Surg. 2000;17(3):216-8.

Cite this article as: Parihar S, Mathur PN, Joshi CP. Evaluation of large duodenal ulcer perforation with special reference to omentopexy and omental plugging. Int Surg J 2016;3:1229-33.