

## Research Article

# Evaluation of management of lymphangiomas in a tertiary care hospital: a prospective, open label, clinical study

Manjeet Singh Chahal, Rohit Tiwari\*

Department of General Surgery, Rohilkhand Medical College, Bareilly, UP, India

**Received:** 15 June 2016

**Accepted:** 01 July 2016

**\*Correspondence:**

Dr. Rohit Tiwari,

E-mail: [dr.rohitrmch@gmail.com](mailto:dr.rohitrmch@gmail.com)

**Copyright:** © the author(s), publisher and licensee Medip Academy. This is an open-access article distributed under the terms of the Creative Commons Attribution Non-Commercial License, which permits unrestricted non-commercial use, distribution, and reproduction in any medium, provided the original work is properly cited.

## ABSTRACT

**Background:** Lymphangiomas are rare benign congenital tumours, involving both the head and the neck and causing obstructing symptoms in the upper airways as well as aesthetic anomalies. They consist in localized centers of abnormal development of the lymphatic system. Present in 2 forms- infiltrative form (firm in consistency) and cystic form (soft and compressible) in neck, known as cystic hygroma. Surgical resection still remains the best treatment for lymphangiomas; other treatment options, such as sclerotherapy have been proposed as an alternative to reduce the impact and complications of surgery.

**Methods:** A prospective, open label clinical study of 36 months duration was conducted on 44 consecutively admitted cases of lymphangioma in age group of 0-21 years of both genders. A thorough detailed history and clinical examination was undertaken. Local Symptoms, skin changes and vascular affect if any was recorded. Unresected lymphangiomas can be treated by radiation, sclerotherapy and steroids.

**Results:** Maximum cases were in the age group of 0-14 years, M: F ratio 1.9:1. Majority of patients were drawn from lower class of the society (56%). Majority of patients (84%) were non-smokers, non-tobacco chewers and non-alcoholics. Site of lymphangioma was head and neck 72% followed by shoulder 18%. 86% of lymphangiomas were non-infected and maximum number of cases 88% stayed in hospital for about 1 week. In 87% cases healing was complete in about 2 weeks. Total surgical excision is the most successful treatment modality of all other options available for its treatment.

**Conclusions:** A correct diagnosis, multidisciplinary approach, optimal treatment and assessment can provide optimal treatment of lymphangiomas.

**Keywords:** Lymph angiogenesis, Lymphangioma, Cystic hygroma, Benign lymphatic tumour

## INTRODUCTION

Lymphangiomas can be microcystic, macrocystic and cystic hygromas. There are three theories proposed for its pathogenesis - firstly blockage or arrest of normal growth of primitive lymph channels, secondly primitive lymph sac fails to reach the venous system and thirdly lymphatic tissue lies in wrong place. Cystic hygromas, account for more than 90% of the lymphangiomas in the head and neck region. The other common areas are axilla, shoulder, chest wall, mediastinum, abdominal wall and thigh.

Surgical excision is the best treatment. Sclerotherapy can be an alternative treatment.<sup>1</sup> Bleomycin, tetracycline, doxycycline, dextrose, OK-432 have been used for the sclerotherapy. Most of these agents, except OK-432, cause extensive peri-lesional fibrosis which may complicate the salvage later.<sup>2</sup>

The aim and objectives of the study was to discuss the clinical presentation, diagnosis and pathologic findings, and management of this malformation and to study the incidence and morbidity and mortality data for cases of lymphangiomas.

## METHODS

This prospective, open label clinical study was conducted in Department of Surgery, Paediatrics and Obstetrics of Rohilkhand Medical College and Hospital, Bareilly, UP, a tertiary care centre in India. In the study period of 36 month duration, from Jan 2013 to Dec 2015, a total of 44 patients were included in this study.

Each patient participating in the clinical trial signed an informed consent form though one could withdraw without any prejudice at any time. The approval of study protocol was obtained from institutional ethical committee.

Study was done for number of deliveries in Obstetrics Department, cases treated or managed in Paediatrics and Surgery department. Morbidity and mortality data for the studied group was accounted.

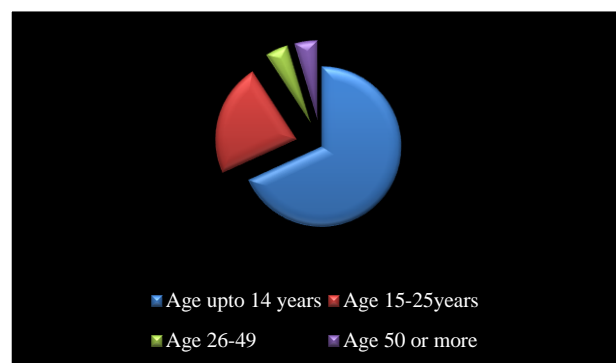
A detailed history and through clinical examination was done in all the patients. Socio-demographic data such as name, age, sex, date of admission and discharge were noted down.

Patients with extensive disease were also subjected to MRI for better delineation of the disease. All enrolled patients were thoroughly clinically examined for any chronic systemic ailment.

In all patients Hb%, Total leucocyte count (TLC), Differential leucocyte count (DLC), fasting or random blood sugar, blood urea and serum creatinine was routinely done. Urine was also examined routinely for both macroscopic and microscopic examination.

Follow up of patients was done. In first 6 months, 30 patients turned up for follow up, in next 6 months, 15

patients came in and only 4 patients came for follow up at the end point (total 24 months).



**Figure 1: Age distribution.**

## RESULTS

44 patients with lymphangioma, exclusive of those who had intra-abdominal lesions, were seen between 2013 and 2015. The results of treatment by surgical excision, aspiration, incision and drainage, and radiation are reported. Two of the four who were left with lymphangioma tissue at operation never had significant recurrences. Therefore, this clinical study does not clarify the possible role of spontaneous regression in lymphangioma. Extensive surgery is the treatment of choice whenever feasible, but in unilocular or bilocular cystic lymphangioma subsequent regression can be expected after palliative treatment (aspiration, or incision and drainage). Clinical and pathological criteria should be established for differentiation between lymphangioma and primary lymphedema. Lesions involving subepithelial, subdermal, and subcutaneous or internodal networks of lymphatics will produce lymphangioma; lesions of the collecting lymphatic trunks will result in lymphedema.

**Table 1: Treatment modality and outcome.**

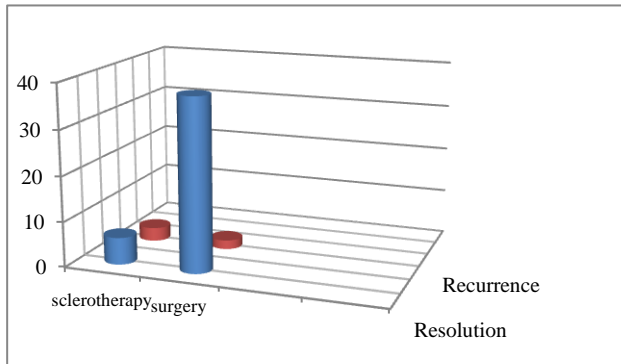
No. of Patients	Modality	Recurrence	Follow up	Final outcome
38	Surgery	2	Revised and then no recurrence	Recovery
6	Sclerotherapy	3	Repeated intra lesional sclerosing agent (max. 3 sittings)	Recovery

In below depicted case of cystic variant of lymphangioma in the region of neck and axilla, which was unique in the virtue of its nature, being a large, macrocystic, single sac located in posterior triangle of neck well as extending well below infra axillary and posterior subscapular area and with sudden rapid painful growth of 15 days duration and the fact that it was successfully treated with complete surgical excision, with no evidence of recurrence in 2 years follow up study.

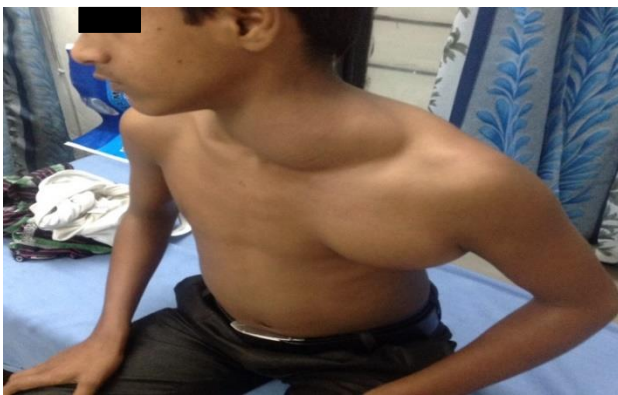Surgical excision resulted in complete resolution in a case of lymphangioma of left thigh in a 3 year old girl.

Other available treatment modality adapted by us at this center for small sized lymphangiomias (up to 1 cm) was intra-lesional injection of sclerosing agent (sodium tetradecyl sulphate) followed by compression bandage for 2 weeks. It resulted in good recovery with few recurrences, which got resolved in due course spontaneously. However some of them required repeat

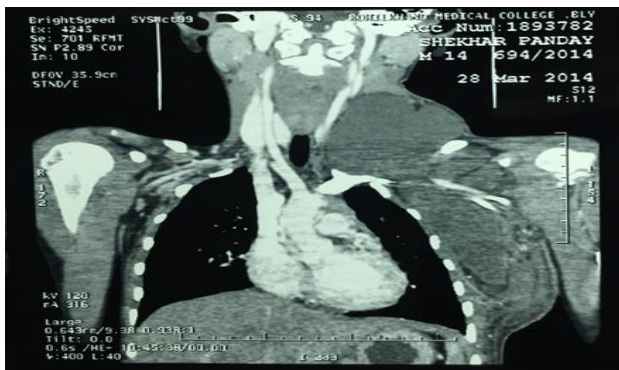intra lesional injections of sclerosing agent for up to 3-4 additional sittings.



**Figure 2: Treatment modality and outcome.**



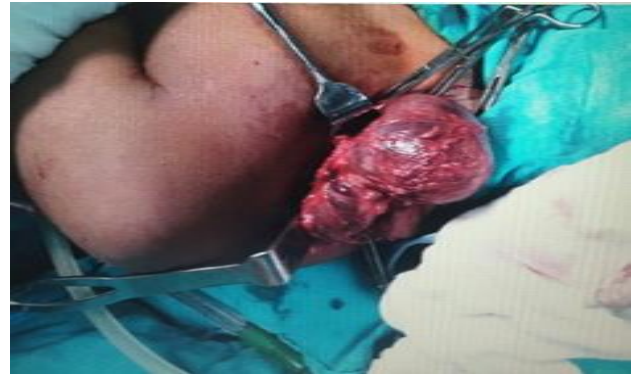**Figure 3: Pre-operative showing intercommunicating cervical and axillary components.**



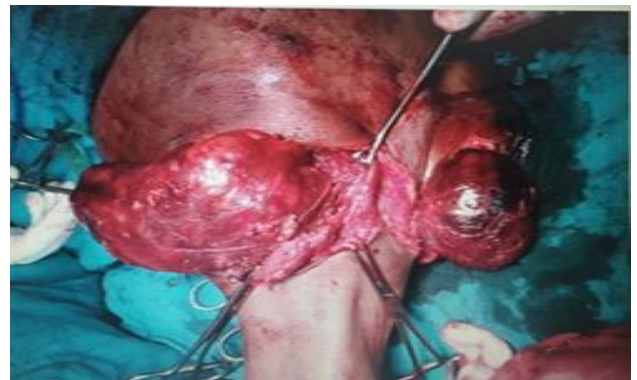**Figure 3: MRI scan revealing large, macrocystic, single sac located in posterior triangle of neck as well as extending well below infra axillary and posterior subscapular area.**

## DISCUSSION

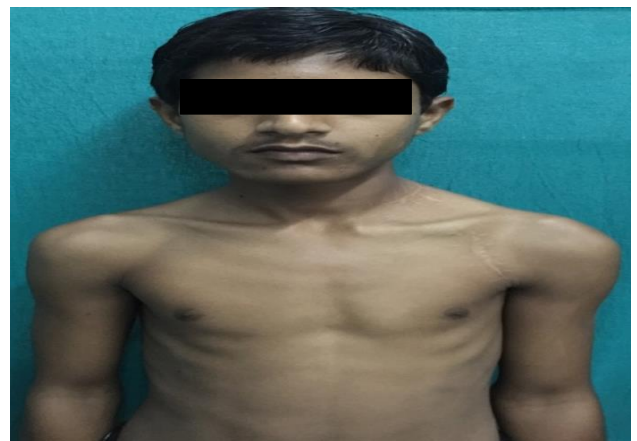Lymphangiomas are rare congenital malformations of the lymphatic system that may occur anywhere in the body. They can be classified as microcystic (i.e. capillary haemangioma), macrocystic (i.e. cavernous haemangioma) and cystic hygroma.<sup>3</sup>



**Figure 4: Intra operative revealing cervical sac originating from posterior triangle of neck.**



**Figure 5: Intra operative-revealing intercommunicating cervical and axillary sacs travelling behind clavicle to reach axilla.**

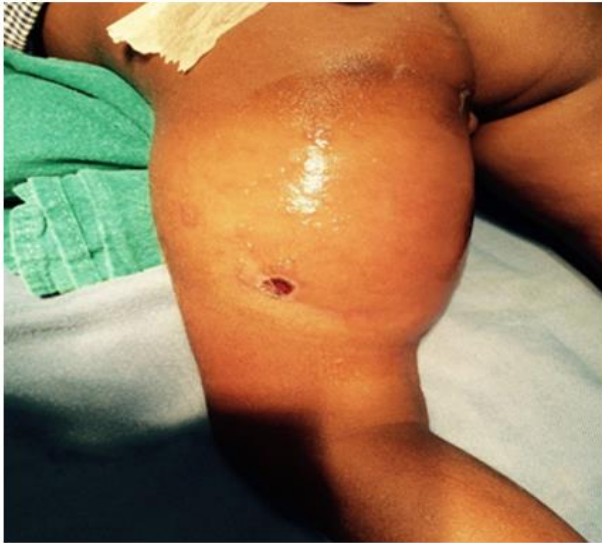

**Figure 6: Post-operatively 2 years showing excellent recovery without recurrence.**

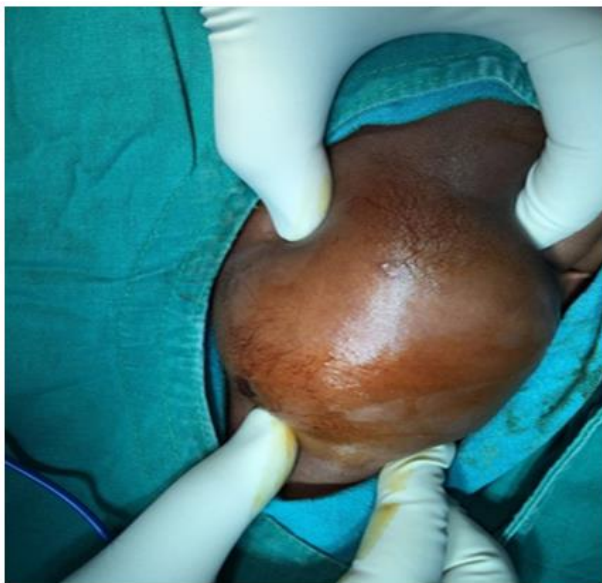The incidence of cystic hygroma is 1.2-2.8 per 1000 birth.<sup>3</sup> In about 80 % of instances, the location of cystic hygromas is cervico-facial region.<sup>4</sup> Capillary haemangioma are mostly found in suprahoid areas like tongue and oral cavity whereas cystic hygromas are most common in the neck. In the neck, anterior triangle of the neck is frequently involved. Cystic hygroma may be localised in the parotid area and is the most common



congenital lesion of the parotid.<sup>4</sup> Therefore, cystic hygroma should always be considered first in the preliminary differential diagnosis of cystic lesion with onset at birth in above mentioned locations.

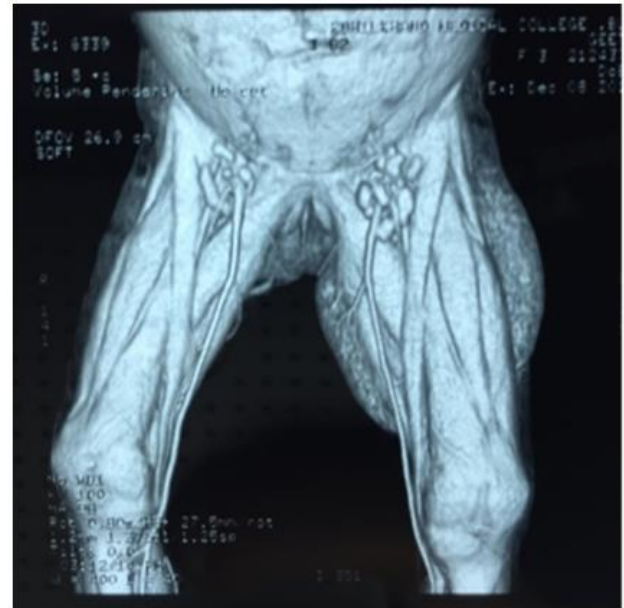

**Figure 7: Lymphangioma (microcystic variant) with skin lesion on thigh.**

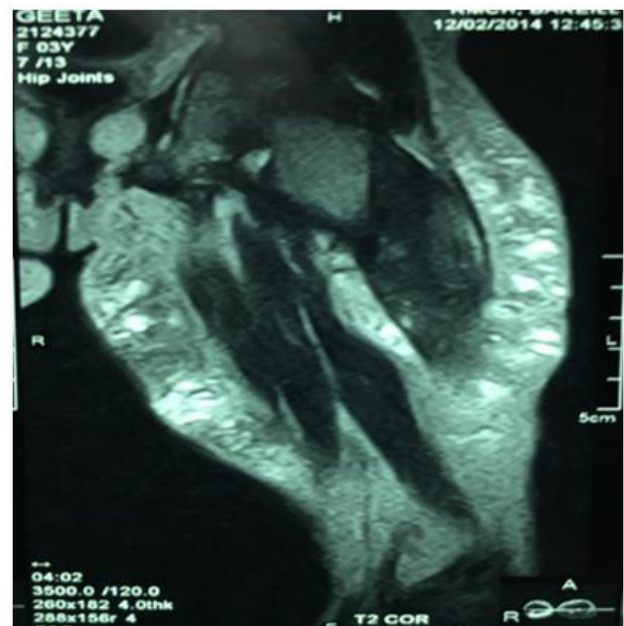


**Figure 8: Clinical examination revealing - confinement of lesion to subcutaneous tissue plane.**

More than 60% have onset at birth and up to 90% becomes overt by age of two years. The nascent appearances of cystic hygroma in adults are scarcely reported in literature. Some case reports depict posttraumatic appearance of cystic hygroma in previously normal adults. These might represent the dormant variety of cystic hygroma that can appear at any age and trauma might be a coincidental event in those cases. The commonest presenting symptom is swelling in the neck which may be very small at birth and may go unnoticed.<sup>5</sup>

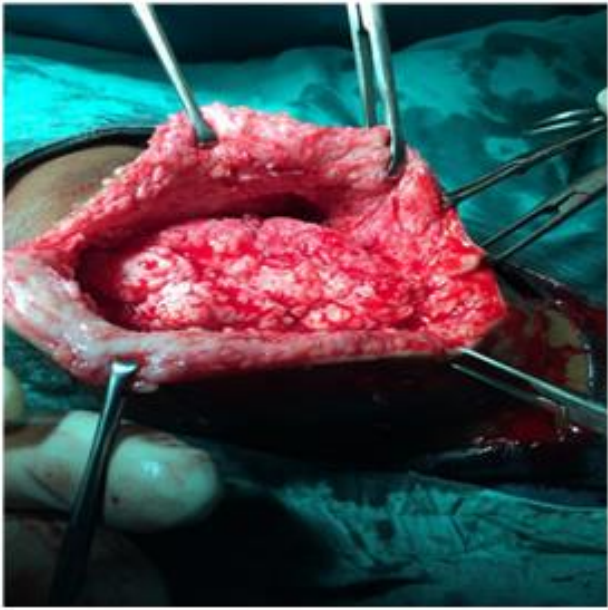


**Figure 9: CT angiogram showing no vascular component of lymphangioma.**

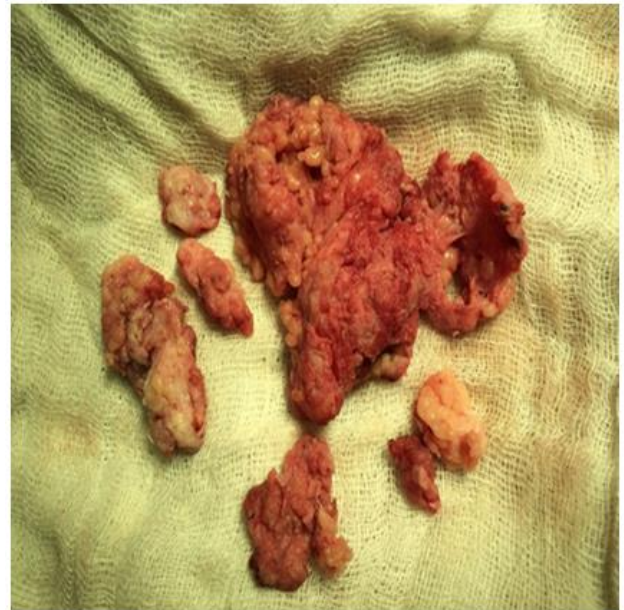


**Figure 10: CECT revealing circumferential extent and extension in intermuscular planes (hamstring muscles).**

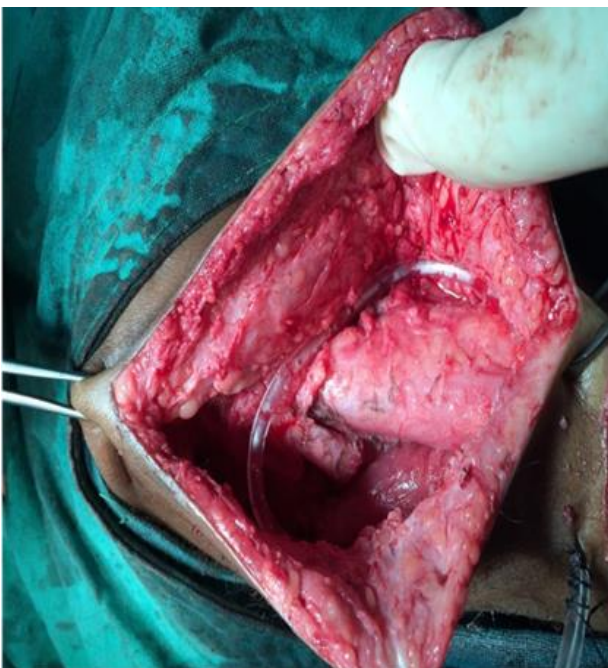
Aspiration of cystic hygroma can be performed as a temporary measure to reduce the size of it and thereby reducing its pressure effects on respiratory and feeding passages. These cysts may produce milky, serous, sero-sanguinous or straw-coloured fluid, when aspirated with a wide-bore needle. The respiratory distress may be of severe nature necessitating a tracheostomy due to significant laryngeal or tracheal compressions by external and rarely laryngeal lymphangiomas.<sup>5</sup>



**Figure 11: Lymphangiomatous microcystic mass dissected all around subdermal plane.**

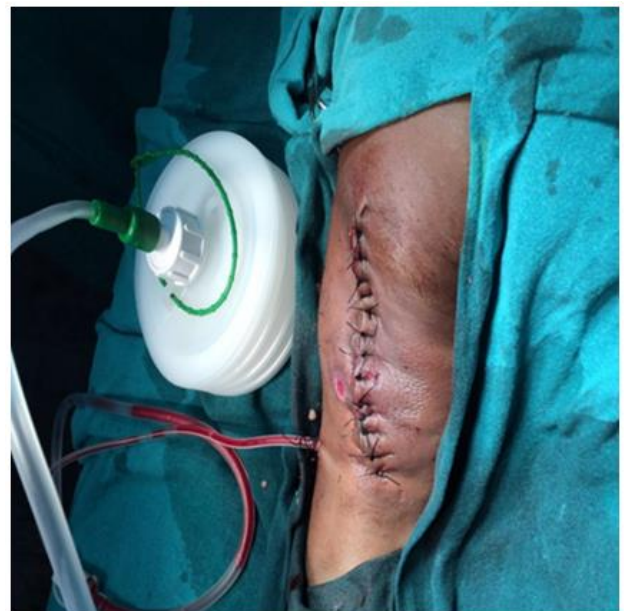

**Figure 13: Resected Specimen of microcystic variant.**



**Figure 12: Dissected till hamstring muscles and drain in situ.**

The prenatal diagnosis of cystic hygroma using ultrasound is well documented in literature. These malformations are commonly localised in the nuchal region. An additional 20% are localised in axilla and rest 5% are found in mediastinum, retroperitoneum, abdominal viscera, groin and scrotum. Fetus with cystic hygroma can be associated with other anomalies in about 62% of cases.<sup>5</sup> When diagnosed prenatally, it may be associated with turners' syndrome, various cardiac anomalies and trisomy syndromes and foetal hydrops.<sup>5-7</sup>



**Figure 14: Post-operative wound closure with closed suction drain.**

Success of the surgery correlates with histopathology, encapsulation, complete excision, anatomical location and stage of the lesion.<sup>8</sup> However, rapid enlargement over a short period of time has frequently been reported and major structures such as the larynx, trachea, oesophagus, brachial plexus and great vessels have known to be compressed or incorporated within the lesion.<sup>9</sup>

In this case the lesion had doubled in size over a period of 4 months and had caused a restriction of neck movement; others have reported presentation with pain, hoarseness, dysphagia and breathlessness.<sup>10,11</sup>



Complete surgical excision has traditionally been considered the treatment of choice for cystic hygroma.<sup>12-</sup>

<sup>15</sup> However, several authors have suggested that sclerotherapy may be a more appropriate first-line therapy.<sup>16,17</sup> Although sclerotherapy is now well established in the treatment of neonatal and paediatric cystic hygromas, there have been relatively few cases reported of its use in adult patients. Some success has been reported in small numbers of adults with sclerotherapy agents such as OK-432.<sup>18</sup> Caution has been urged with the use of agents such as OK-432 which induce a local immune response that often results in a rapid temporary increase in the size of the cystic hygroma.<sup>17,18</sup>

Smith et al compared results from their large-scale trial of OK-432 with pooled results from large surgical case series reported in the literature and reported greater success rates and lower occurrence of major complications with OK-432 sclerotherapy compared with surgical excision.<sup>17</sup>

In addition, clinical success of OK-432 treatment was defined as a greater than 60% reduction in size.<sup>17</sup> This may leave a substantial proportion of the lesion in situ and the acceptability of this may depend on the exact location and relations of the tumour. It is therefore difficult to apply these results to our case of an adult patient with a lesion in close relation to several important structures in the neck.

## CONCLUSION

Lymphangiomas are benign lymphatic tumours, found in nearly all regions of body. They arise due to failure of lymphatics to drain into venous system. Cystic hygromas are rare benign neoplasm. Though easy to diagnose clinically, it needs good radiological evaluation. Complete surgical excision is possible even in very extensive lesions. Treatment of choice is excision where possible. Unresected lymphangiomas can be treated by radiation, sclerotherapy, steroids and intralesional injection of OK-432.

## ACKNOWLEDGEMENTS

We would like to thank our patients who participated in this study. Also we are thankful to our colleagues and paramedical staff who helped and supported us throughout the study.

*Funding: No funding sources*

*Conflict of interest: None declared*

*Ethical approval: The study was approved by the institutional ethics committee*

## REFERENCES

1. Ward FE, Hendrick JW, Chambers RG. Cystic Hygroma of the Neck. West J Surg Obstet Gynaecol. 1950;58:41-7.
2. Ogita S, Tsuto T, Nakamura K, Deguchi E, Tokiwa K, Iwai N. OK-432 Therapies For Lymphangioma In Children: Why and How Does It Work? J Paediatr Surg. 1996;31:477-80.
3. Filston HC. Haemangioma, Cystic Hygromas and Teratomas in of the Head and Neck. Semin Pediatr Surg. 1994;3:147-59.
4. Galofre M, Judd ES, Perez PE, Harrison EJ Jr. Results of Surgical Treatment of Cystic Hygroma. Surg Gynecol Obstet. 1962;115:19-26.
5. Mirza B, Ijaz L, Sheikh A. Cystic Hygroma: An Overview. J Cutan Aesthet Surg. 2010;3(3):139-44.
6. Chappius IIP - Current Aspect of Cystic Lymphangioma in Neck. Arch. Paediatric. 1994;1(2):186-92.
7. Morley SE, Ramesar KC, Mcleod DA. Cystic Hygroma in an Adult: A Case Report. J R Coll Surg. 1999;44(1):57-8.
8. de Serres L, Sie K, Richardson M. Lymphatic malformations of the head and neck. A proposal for staging. Arch Otolaryngol Head Neck Surg. 1995;121:577-82.
9. de Casso Moxo C, Lewis NJ, Rapado F. Lymphangioma presenting as a neck mass in the adult. Int J Clin Pract. 2001;55:337-8.
10. Cheng LHH, Wells FC. A multidisciplinary approach to recurrent cervicothoracic cystic hygroma in an adult. Br J Oral Maxillofacial Surg. 2004;42:66-8.
11. Vaid L, Gupta M, Gupta N, Singh P. Bleomycin sclerotherapy in a rare case of adult-onset cervical lymphangioma. Ear Nose Throat J. 2010;89:E23-6.
12. Riechelmann H, Muehlflay G, Keck T, Mattfeldt T, Rettinger G. Total, subtotal, and partial surgical removal of cervicofacial lymphangiomas. Arch Otolaryngol Head Neck Surg. 1999;125:643-8.
13. Mandel L. Parotid area lymphangioma in an adult: case report. J Oral Maxillofacial Surg. 2004;62:1320-3.
14. Morley S, Ramesar K, Macleod D. Cystic hygroma in an adult: a case report. J R Coll Surg Edinb. 1999;44:57-8.
15. Oakes M, Sherman B. Cystic hygroma in a tactical aviator: a case report. Mil Med. 2004;169:985-7.
16. Sichel JY, Udassin R, Gozal D, Koplewitz BZ, Dano I, Eliashar R. OK-432 therapy for cervical lymphangioma. Laryngoscope. 2004;114:1805-9.
17. Smith MC, Zimmerman MB, Burke DK, et al. Efficacy and safety of OK-432 immunotherapy of lymphatic malformations. Laryngoscope. 2009;119:107-15.

**Cite this article as:** Chahal MS, Tiwari R.

Evaluation of management of lymphangiomas in a tertiary care hospital: a prospective, open label, clinical study. Int Surg J 2016;3:1101-6.