

Original Research Article

One-stage lapro-endoscopic procedure in the management of concomitant gallbladder and common bile duct stones: institutional experience

Ahmed M. Abdelaziz Hassan^{1*}, Ayman M. Abdelaziz², Mohamed Emad Esmat¹,
Hussam Hamdy¹, Magdy M. Elsebae¹

¹Department of General Surgery, ²Department of Gastroenterology, Theodor Bilharz Research Institute, Cairo, Egypt

Received: 01 December 2018

Revised: 12 March 2019

Accepted: 14 March 2019

***Correspondence:**

Dr. Ahmed M. Abdelaziz Hassan,

E-mail: ahmedelmaghney@yahoo.com

Copyright: © the author(s), publisher and licensee Medip Academy. This is an open-access article distributed under the terms of the Creative Commons Attribution Non-Commercial License, which permits unrestricted non-commercial use, distribution, and reproduction in any medium, provided the original work is properly cited.

ABSTRACT

Background: Still there is no standard technique for managing patients with concomitant gallbladder (GB) and common bile duct stones (CBDS). In this work, we report our experience of the management for gallstone disease and biliary duct calculi as a single stage treatment.

Methods: Forty Patients with symptomatic gall bladder calculi disease and suspected CBDS were enrolled in the study. The outcome measures were operating time, CBD stone clearance, postoperative morbidity and mortality, the need to conversion to other techniques and hospital stay.

Results: They were 13 males and 27 females of median age 43 years old. Intra operative cholangiography (IOC) revealed single CBD stone in twenty-eight, two stones in eleven and three stones in only one of the patients. The mean operating time had been 175 min. There were no intraoperative complications with a mean hospital stay was 1.8 days (range, 1-4 days).

Conclusions: One-stage lapro-endoscopic procedure in the management for gallstone disease and biliary duct calculi is safe and efficient in CBD stone clearance. It is preferred when facilities and experience in endoscopic therapy exist.

Keywords: Common bile duct stones, Gall bladder, Rendezvous technique

INTRODUCTION

Still there is no standard technique for managing patients with concomitant gallbladder (GB) and common bile duct stones (CBDS). The most commonly applied options now involve either a single stage laparoscopic cholecystectomy (LC) with transcystic stone extraction (LTSE) or two-stage LC with pre- or post-operative endoscopic retrograde cholangiography (ERCP) with stone extraction.¹⁻³ Although preoperative ERCP and endoscopic sphincterotomy (ES) with stone removal is successful in approximately 85% of cases with CBDS, only 20-50% of those patients suspected by clinical,

biochemical, and radiological criteria show CBDS on preoperative ERCP.⁴⁻¹⁰ Therefore, a high number of patients would undergo unnecessary ERCP with its considerable risk rate of complications (5-20%) and a substantial cost. On the other hand, postoperative ERCP and ES, with stone removal has the clear advantage, of limiting ERCP to documented cases of CBDS but with a failure rate of 7-14%, in which case a further procedure with its associated morbidity, mortality and cost is necessary.¹¹⁻¹³ Moreover, in some cases the insertion of the cannula into the CBD during ERCP may be technically difficult due to anatomical abnormalities such as, the Vater papilla opening in the third portion of the

duodenum, a peripapillary duodenal diverticulum or other reasons.¹⁴ Furthermore, LTSE by Dormia basket and/or Fogarty angioplasty catheter is technically demanding and time-consuming with contradictory affectivity in 50-97% of cases.¹⁵⁻²⁰

A combined procedure in which the GB to be removed laparoscopically while a CBD stone is simultaneously cleared endoscopically by a selective CBD cannulation, facilitated by the laparoscopic placement of a guide wire through the cystic duct into the duodenum, (rendezvous technique) was originally adopted to overcome technical difficulties during ERCP. In this work, we report our experience of a modified rendezvous technique as a single stage treatment for management for gallstone disease and biliary duct calculi when LTSE treatment is not possible. The outcome measures were operating time, CBD stone clearance, postoperative morbidity and mortality, the need to conversion to other techniques and hospital stay.

METHODS

During the period from March 2017 to October 2018, 40 Patients with symptomatic gall bladder calcular disease and suspected CBDS because of manifest or clinical history of jaundice, elevation of serum bilirubin and alkaline phosphatase and CBDS on abdominal ultrasonography and/or magnetic resonance cholangiopancreatography (MRCP), were recruited for this study. All patients had been consented to a laparoscopic cholecystectomy with possible need for intra-operative ERCP, in addition to thorough explanation of the operative procedure and possible complications and the possibility of conversion to conventional laparoscopic cholecystectomy or open technique. The Ethics Committee of Theodore Bilharz Research Institute (TBRI) approved this study. For all patients, the main author was part of the surgical crew and the surgical technique to be standardized.

Surgical technique

With slight anti-Trendelenburg and left tilting supine position, four trocars for LC were used. The cystic artery first dissected and divided after clipping. The gallbladder partially dissected off the liver leaving a rim of connection at the fundus of gall bladder with cystic duct kept intact. Routine intraoperative cholangiography (IOC) via the cystic duct performed. When IOC demonstrated or confirmed the presence of CBDS, LTSE attempted through the cholangiography catheter with a Dormia basket after it was flushed with saline. If this was not successful, an intra-operative ERCP and ES performed. The ERCP equipment was set up at the head of the patient on to the left side. The Dormia basket catheter (4 Fr.) passed into CBD through the opening on cystic duct (Figure 1) and then pushed through the papilla into the duodenum (Figure 2).

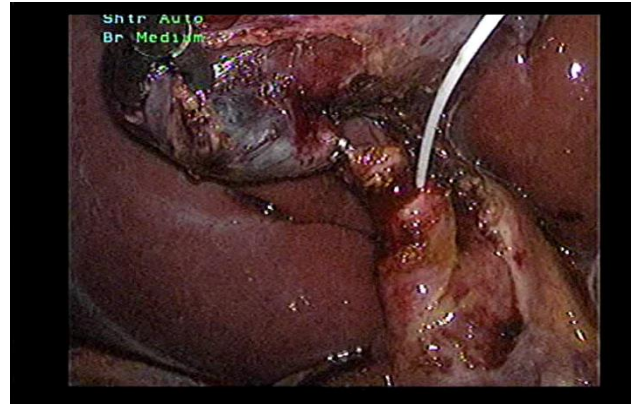


Figure 1: The dormia basket catheter (4 fr.) passed into cbd through the opening on cystic duct.

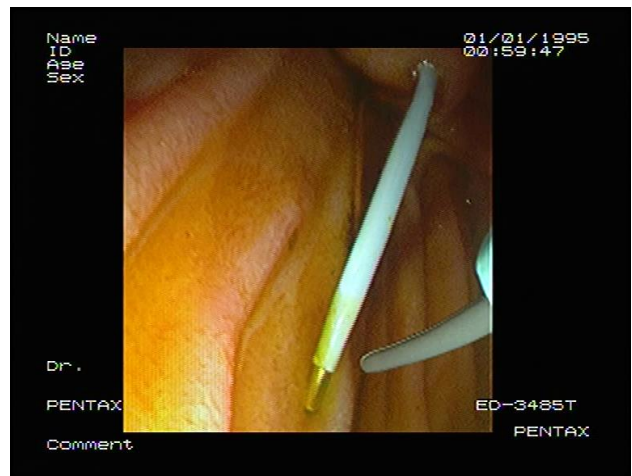


Figure 2: The Dormia basket catheter pushed through the papilla into the duodenum.

Simultaneously, the endoscopist passed the endoscope to duodenum as in conventional ERCP until the papilla is visualized, overseeing the Dormia basket catheter passing through the papilla (Figure 3).

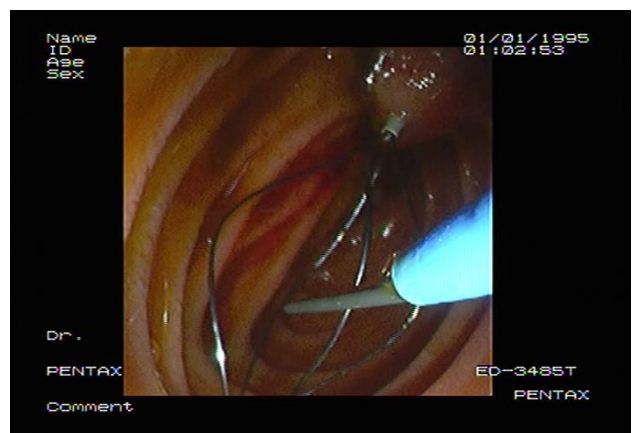


Figure 3: the endoscopist passed the endoscope to duodenum until the papilla is visualized, overseeing the Dormia basket catheter passing through the papilla.

Under the endoscopic monitoring, a sphincterotome loaded with guide wire introduced through endoscope to approach the opened Dormia basket; the guide wire advanced until its hydrophilic tip trapped into basket (Figure 4).

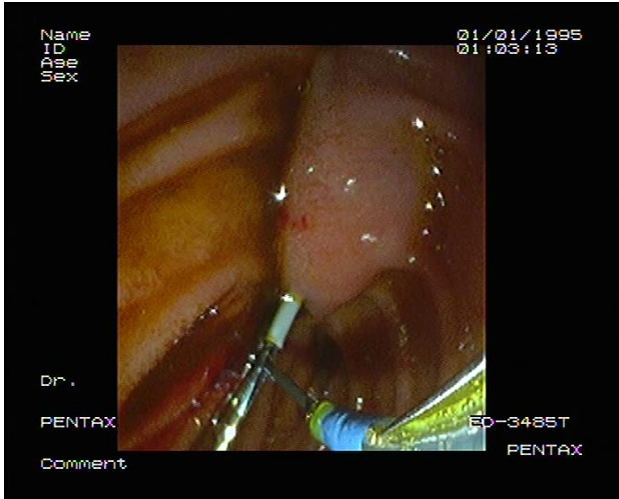


Figure 4: The guide wire advanced by the endoscope until its hydrophilic tip trapped into basket.

The laparoscopic surgeon then close the basket to grasp the guide wire and pull back the basket catheter so that the guide wire followed the catheter and entered CBD; the sphincterotome is then advanced over the guide wire by the endoscopist to achieve elective CBD cannulation (Figure 5).

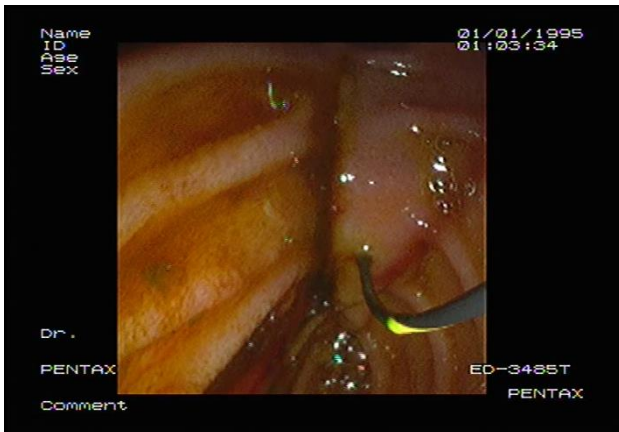


Figure 5: The sphincterotome advanced over the guide wire by the endoscopist to achieve elective CBD cannulation.

At this point of time, the surgeon open the basket and let the endoscopist retreating guide wire; then the surgeon remove the basket catheter and double clip the cyst duct distal to the opening to avoid bile leakage during the subsequent process. The sphincterotomy and balloon dilatation was then be performed accordingly, followed by the CBD stone clearance using basket or balloon catheter under fluoroscopic guidance as in routine ERCP

(Figure 6). Another cholangiography via ERCP performed to ensure clearance of the CBD. The endoscopist withdraws the duodenoscope after aspirating the air and fluid in duodenum and stomach. The surgeon then divided the cystic duct between clips to complete cholecystectomy.

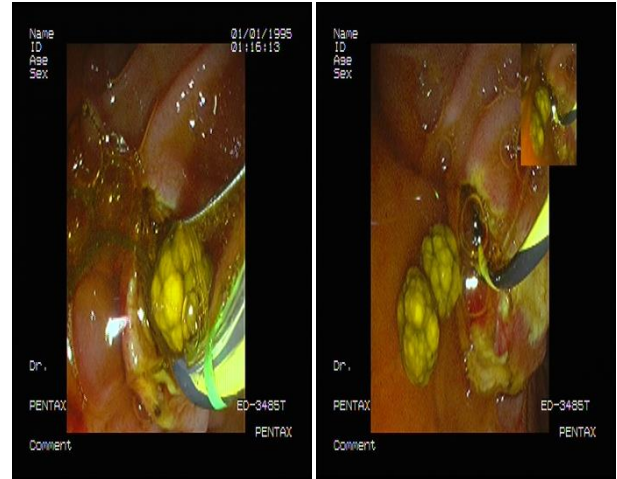


Figure 6: CBD stone clearance using basket or balloon catheter under fluoroscopic guidance.

Postoperatively, all patients fasted overnight. Normal oral intake has resumed once the patients demonstrated normal serum amylase and lipase titers. All patients have reviewed within 4 weeks from discharge.

RESULTS

They were 13 males and 27 females of median age 43 years old (range, 25-68 years old) included in this study. Abdominal ultrasound and/or MRCP revealed dilated CBD and intrahepatic biliary radicals in all of the patients. Preoperatively Confirmed CBD stones revealed in 37 (92.5%) of patients. IOC revealed calcular obstructive jaundice in all patients (100 %); single CBD stone in twenty-eight, two stones in eleven and multiple (\geq three stones) in only one of the patients. Successful LTSE performed in thirteen patients (32.5%). All of them had single CBD stone.

Rendezvous technique needed in twenty-seven (67.5%) of patients because LTSE was not successful. Passage of the Dormia basket and successful ERCP stone extraction performed for a single CBD stone in thirteen patients, two stones in eleven patients and multiple stones in one of the patients. Failed ERCP to extract CBD stone due its huge size ($>$ 1.5 cm) occurred in two patients (5%) and they needed laparoscopic choledochotomy to extract it. The CBD stones clearance was 100%.

Regarding CBD drainage, in LTSE treated patients; no drain needed and direct closure of the cystic duct was done in all 13 patients. A T-tube drain inserted in the two patients with the choledochotomy and one patient of the

Rendezvous technique because of suspected infected bile. None of the patients converted to open CBD exploration.

There were no intraoperative complications. The mean operating time had been 175 min (range, 90-210). Table (1) shows the mean operative time in details.

Table 1: Operative time details.

	Mean (min)	Range (min)
Stage 1	13.4	8 – 22
Stage 2	34.2	20 – 57
Stage 3	49	37-62
Stage 4	14	9 -22
Stage 5	4	3-7

Stage 1: Standard positioning, insufflation, dissection of Calot's triangle and IOC, Stage 2: Successful LTSE, Stage 3: Failed LTSE, Stage 4: Lapro-endoscopic 'rendezvous' technique, Stage 5: Completion of laparoscopic cholecystectomy.

Regarding Postoperative complications; none of patients developed postoperative pancreatitis. Two patients with the T-tube developed bile leakage after removal of it. They were managed conservatively until it stopped and there was no need for another intervention for that complication. LTSE and Rendezvous technique treated patients were comparable in length of hospital stay (Table 2).

Table 2: Postoperative data.

	LBDSE* (n=15)	Rendezvous technique (n=25)
Common bile duct clearance rate	15 (100%)	25 (100%)
Conversion to open surgery	None	None
Complication		
Cholangitis	0 (100%)	0 (0%)
Bile leak	1 (6.66%)	1 (4%)
Acute pancreatitis	0 (0%)	0 (0%)
Hospital stay (Mean & range, days)	2.6(2-11)	2.8 (1-14)

*LBDSE: Laparoscopic bile duct stone extraction

DISCUSSION

Peroperative lapro-endoscopic 'rendezvous' technique has reported for the first time in 1998, as an efficacious method to treat CBD stones with no difference, even lower than in the two-step approach (ERCP followed by LC) in the incidence of complications mainly postoperative pancreatitis. It is significantly useful in shortening hospital stay and in reducing medical costs compared to a two-stage treatment. However, it has disadvantages of prolongation of the operation time and the logistic problems of organizing the procedure.²¹ However, we believe peroperative lapro-endoscopic

'rendezvous' technique should be the first choice single-stage treatment for concomitant GB and CBD stones as it allowed successful CBD cannulation and clearance of the CBDS in our cases compared to a high rate of cannulation failure (14% to 23%) by the conventional ERCP technique.^{22,23} It is easy to implement the already familiar technique of ERCP in the operating theater, with additional advantage of that its application irrespective of the diameter of the bile duct stone; when the transcystic laparoscopic approach cannot remove large stones.

In most of the reports of the 'rendezvous' technique, they insert a flexible guide wire through the cholangiogram catheter into the CBD according to the Hunter technique.^{11,15} However, Passage of the guide-wire through the papilla might fail.²⁴⁻²⁶ In the technique adopted in this study, to facilitate Vater papilla cannulation we inserted a Dormia basket catheter (4 Fr.) passed into CBD through the opening on cystic duct and then pushed through the papilla into the duodenum. Simultaneously, the endoscopist passed the endoscope to duodenum as in conventional ERCP until the papilla is visualized, overseeing the Dormia basket catheter passing through the papilla then caught by a duodenoscope. Sphincterotome from the duodenoscope then guided it into the bile duct to ensure its easy cannulation. Moreover, an antegrade easy cannulation of the papilla, avoids the risk of inadvertent cannulation of the pancreatic duct, with possible related major complication of acute pancreatitis. The use of Dormia basket catheter in our technique was better than the flexible guidewire that might fail due to the possibility of its obstruction by CBDS, as well as, the general surgeon is more familiar with its application.

Laparoscopic CBD exploration (LCBDE) to extract CBD stones was Successful in only fifteen (37.5%) by LTSE performed in thirteen of patients, while Two patients needed laparoscopic choledochotomy due its huge size > 1.5 cm. when comparing LCBDE versus lapro-endoscopic 'rendezvous' technique for CBDS, the success rate of CBD clearance, surgical time and postoperative length of stay between the two interventions was not different. Our study and others suggests that lapro-endoscopic 'rendezvous' technique by the use of Dormia basket catheter in our technique rather than the flexible guidewire in Vater papilla cannulation for the management of CBDS is a safe and effective without post-ERCP pancreatitis.

It offers another alternative for surgeons especially those who do not practice LCBDE to treat patients in a single setting.

CONCLUSION

One-stage lapro-endoscopic procedure in the management for gallstone disease and biliary duct calculi is safe and efficient in CBD stone clearance. It is

preferred when facilities and experience in endoscopic therapy exist.

Funding: No funding sources

Conflict of interest: None declared

Ethical approval: The study was approved by the Institutional Ethics Committee

REFERENCES

1. Fitzgibbons RJ, Gardner GC. Laparoscopic surgery and the common bile duct. *World J Surg.* 2001;25:1317-24.
2. Almadi MA, Barkun JS, Barkun AN. Management of suspected stones in the common bile duct. *CMAJ.* 2012;184(8):884-92.
3. Takada T, Strasberg SM, Solomkin JS. Tokyo Guidelines Revision Committee. TG13: Updated Tokyo Guidelines for the management of acute cholangitis and cholecystitis. *J Hepatobiliary Pancreat Sci.* 2013;20:1-7.
4. Lenriot JP, Le Neel JC, Hay JM, Jaeck D, Millat B, Fagniez PL. Retrograde cholangiopancreatography and endoscopic sphincterotomy for biliary lithiasis. Prospective evaluation in surgical circle. *Gastroenterol Clin Biol.* 1993;17(4):244-50.
5. Huynh CH, Van de Stadt J, Devière J, Mehdi A, Nakadi I, Cremer M, et al. Preoperative endoscopic retrograde cholangiopancreatography: therapeutic impact in a general population of patients needing a cholecystectomy. *Hepatogastroenterol.* 1996;43(12):1484-91.
6. Franciosi C, Caprotti R, De Fina S, Romano F, Colombo G, Uggeri F, et al. Sequential endo-laparoscopic treatment in patients with common bile calculi. *Minerva Chir.* 2000;55(10):665-71.
7. Ramírez-Luna MA, Elizondo-Rivera J, Herrera MF, Pedroza-Granados J, Valdovinos-Andraca F. Usefulness of endoscopic cholangiography and sphincterotomy in patients with biliary lithiasis. *Rev Gastroenterol Mex.* 2004;69(4):217-25.
8. Costi R, Gnocchi A, Di Mario F, Sarli L. Diagnosis and management of choledocholithiasis in the golden age of imaging, endoscopy and laparoscopy. *World J Gastroenterol.* 2014;20(37):13382-401.
9. Tronsen E, Edwin B, Reiertsen O, Faerden AE, Fagertun H, Rosseland AR. Prediction of common bile duct stones prior to cholecystectomy: a prospective validation of a discriminant analysis function. *Arch Surg.* 1998;133(2):162-6.
10. Coppola R, Riccioni ME, Ciletti S, Cosentino L, Ripetti V, Magistrelli P, et al. Selective use of endoscopic retrograde cholangiopancreatography to facilitate laparoscopic cholecystectomy without cholangiography. A review of 1139 consecutive cases. *Surg Endosc.* 2001;15(10):1213-6.
11. Cavina E, Franceschi M, Sidoti F. Laparo-endoscopic 'rendezvous': a new technique in the choledocholithiasis treatment. *Hepatogastroenterol.* 1998;45:1430-5.
12. La Greca G, Barbagallo F, Di Blasi M. Rendezvous technique versus endoscopic retrograde cholangiopancreatography to treat bile duct stones reduces endoscopic time and pancreatic damage. *J Laparoendosc Adv Surg Tech A.* 2007;17:167-71.
13. Morino M, Baracchi F, Miglietta C. Preoperative endoscopic sphincterotomy versus laparoendoscopic rendezvous in patients with gallbladder and bile duct stones. *Ann Surg.* 2006;244:889-93.
14. Enochsson L, Lindberg B, Swahn F. Intraoperative endoscopic retrograde cholangiopancreatography (ERCP) to remove common bile duct stones during routine laparoscopic cholecystectomy does not prolong hospitalization: a 2-year experience. *Surg Endosc.* 2004;18:367-71.
15. Hunter JG. Laparoscopic transcystic common bile duct exploration. *Am J Surg.* 1992;163(1):53-6.
16. Scientific Committee of the European Association for Endoscopic Surgery (E.A.E.S.). Diagnosis and treatment of common bile duct stones (CBDS). Results of a consensus development conference. *Surg Endosc.* 1998;12(6):856-64.
17. Kent AL, Cox MR, Wilson TG, Padbury RT, Toouli J. Endoscopic retrograde cholangiopancreatography following laparoscopic cholecystectomy. *Aust N Z J Surg.* 1994;64(6):407-12.
18. Kim BS, Joo SH, Cho S, Han MS. Who experiences endoscopic retrograde cholangiopancreatography after laparoscopic cholecystectomy for symptomatic gallstone disease? *Ann Surg Treat Res.* 2016;90(6):309-14.
19. Zhu JG, Han W, Guo W, Su W, Bai ZG, Zhang ZT. Learning curve and outcome of laparoscopic transcystic common bile duct exploration for choledocholithiasis. *Br J Surg.* 2015;102(13):1691-7.
20. Aawsaj Y, Light D, Horgan L. Laparoscopic common bile duct exploration: 15-year experience in a district general hospital. *Surg Endosc.* 2016;30(6):2563-6.
21. Cemachovic I, Letard JC, Begin GF, Rousseau D, Nivet JM. Intraoperative endoscopic sphincterotomy is a reasonable option for complete single-stage minimally invasive biliary stones treatment: short-term experience with 57 patients. *Endoscopy.* 2000;32(12):956-62.
22. Tricarico A, Cione G, Sozio M, Di Palo P, Bottino V, Tricarico T, et al. Falco Endolaparoscopic rendezvous treatment: a satisfying therapeutic choice for cholecysto-choledocholithiasis. *Surg Endosc.* 2002;16(4):585-8.
23. Williams GL, Vellacott KD. Selective operative cholangiography and Perioperative endoscopic retrograde cholangiopancreatography (ERCP) during laparoscopic cholecystectomy: a viable option for choledocholithiasis. *Surg Endosc.* 2002;16(3):465-7.
24. Odabasi M, Yildiz MK, Abuoglu HH, Eris C, Ozkan E, Gunay E, et al. A modified Rendezvous ERCP

- technique in duodenal diverticulum. *World J Gastrointest Endosc.* 2013;5(11):568-73.
25. Saccomani G, Durante V, Magnolia MR, Ghezzi L, Lombezzi R, Esercizio L, et al. Combined endoscopic treatment for cholelithiasis associated with choledocholithiasis. *Surg Endosc.* 2005;19(7):910-4.
26. ElGeidie AA, ElShobary MM, Naeem YM. Laparoscopic exploration versus intraoperative

endoscopic sphincterotomy for common bile duct stones: a prospective randomized trial. *Dig Surg.* 2011;28(5-6):424-31.

Cite this article as: Hassan AMA, Abdelaziz AM, Esmat ME, Hamdy H, Elsebae MM. One-stage lapro-endoscopic procedure in the management of concomitant gallbladder and common bile duct stones: institutional experience. *Int Surg J* 2019;6:1447-52.