

Case Report

Large primary scrotal lipoma with particular presentation

Nicolae-Iustin Berevoescu^{1,2*}, Sorin Stanilescu¹, George Halcu³,
Mihaela Berevoescu⁴, Daniel Cristian^{1,2}

¹Department of General Surgery, Colțea Clinical Hospital, Bucharest, Romania

²Department of Surgery, Carol Davila University of Medicine and Pharmacy, Bucharest, Romania

³Department of Pathology, Colțea Clinical Hospital, Bucharest, Romania

⁴Department of Pathology, Craiova University of Medicine and Pharmacy, Dolj, Romania

Received: 30 November 2018

Accepted: 02 January 2019

*Correspondence:

Dr. Nicolae-Iustin Berevoescu,
E-mail: niberev@yahoo.com

Copyright: © the author(s), publisher and licensee Medip Academy. This is an open-access article distributed under the terms of the Creative Commons Attribution Non-Commercial License, which permits unrestricted non-commercial use, distribution, and reproduction in any medium, provided the original work is properly cited.

ABSTRACT

Scrotal lipomas are benign tumours rarely seen in clinical practice. They can mimic common affections such as an inguinoscrotal hernia, varicocele, hydrocele or a testicular tumour. Thus, in many cases, physical examination leads to a correct diagnosis, there are situations that require comprehensive imagistic examinations, to establish the preoperative nature of the scrotal tumour. A case of 64-year-old male, known with arterial hypertension and gonarthrosis, came to the hospital for a painless scrotal tumour with a fast growth rate in dimensions over the last year. Physical examination detected an elastic, painless, irreducible, irregularly shaped mass of a right scrotal region. The scrotal ultrasound revealed a heterogeneous hyperechoic solid mass with 10x8.1x8cm in dimensions, localized in the right scrotal region. The magnetic resonance imaging (MRI) showed a globular shaped right scrotal tumour mass with well-defined margins, poorly vascularized at the lower pole. Surgery was performed, with excision of a mass about 10cm in major diameter from the right scrotal wall. Postoperative evolution was good, and the histological diagnosis of primary scrotal lipoma was made. One-year follow-up revealed no local relapse.

Keywords: Inguinoscrotal hernia, Scrotal lipoma, Scrotal liposarcoma, Scrotal magnetic resonance imaging

INTRODUCTION

The scrotum is a cutaneous fibromuscular compartment which comprises the testicles and extra testicular anatomical structures like epididymis and spermatic cord.¹ In this anatomical compartment can arise some tumour formations, typically considered as intratesticular or extra testicular, cystic or solid types. While solid intratesticular masses, as germ cell and non-germ cell tumours, metastatic lesions, lymphomas or leiomyosarcomas are malignant in about 95% of cases, extra testicular ones are common benign and include lipoma, leiomyoma, fibrous pseudotumour, neurofibroma, granular cell tumour, angio-myo-fibro-blastoma-like

tumour and fibrous hamartoma of infancy.² Solid extra testicular tumours are malignant in only 3% of cases, including liposarcoma, leiomyosarcoma, rhabdomyosarcoma, lymphoma and metastasis.³ In a such of tumoral pleomorphism, the scrotal lipoma is not always an easy diagnosis to establish. They are rarely seen in clinical practice and the origin regions of these tumours are not always detectable.⁴ They can arise from adipose tissue of spermatic cord, extended into the scrotum and are named scrotal lipomas, from spermatic cord structures develop in the spermatic cord and are named spermatic cord and tunica vaginalis tumours and from the adipose cells of the scrotal wall, which are named primary scrotal lipoma.⁵⁻⁷ Author highlighted a primary scrotal lipoma having a

particular clinical and imagistic presentation that sustains rather a preoperative diagnosis of well-differentiated liposarcoma than a lipoma.

CASE REPORT

A 64-year-old male, known with arterial hypertension and gonarthrosis, presented to the Surgery Clinic for a painless scrotal tumour with a fast growth rate in dimensions over the last year. Physical examination detected an elastic, painless, irreducible, irregular shaped mass of a right scrotal region (Figure 1).

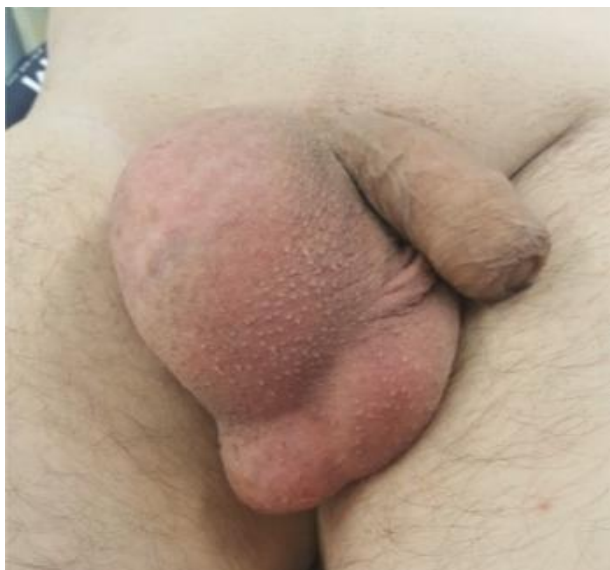

Figure 1: Clinical aspect of the scrotal tumour.

It was easily distinguishable from the testicle. Both testicles and spermatic cords were normal and the tumour was without transillumination. Laboratory values were in normal ranges, including β -human chorionic gonadotropin and α -fetoprotein. The scrotal ultrasound revealed a heterogeneous hyperechoic solid mass with 10x8.1x8cm in dimensions, localized in the right scrotal region.

The clinical and ultrasonographic features determined us to request a scrotal magnetic resonance imaging. Images showed a globular shaped right scrotal tumour mass, with well-defined margins, poorly vascularized at the lower pole (Figure 2).

Surgery was performed, with excision of a mass about 10cm in major diameter from the right scrotal wall (Figure 3). Postoperative evolution was good. Microscopic cross-section report stated incapsulated primary scrotal lipoma consisting of mature adipose cells, blood vessels with a slightly dilated lumen, minimally inflamed chronic interstitial lymphocytic infiltration with no sarcomatous structures (Figure 4). One-year follow-up revealed no local relapse.

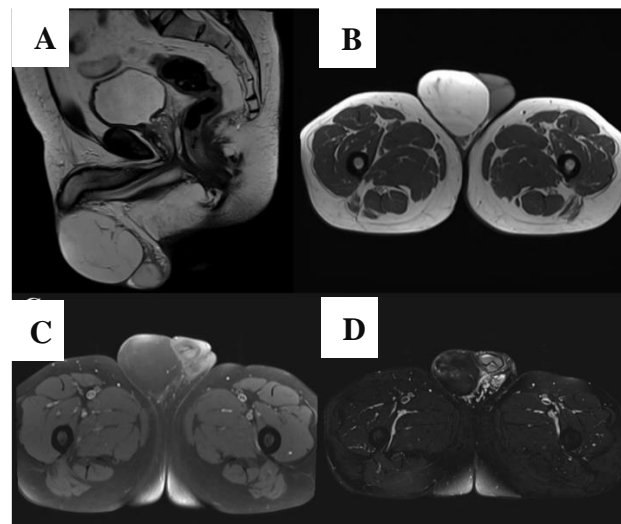


Figure 2: Scrotal MRI. A): Globular shaped right scrotal tumour mass with well-defined margins, poorly vascularized peripherally, B): Scrotal lesion with mostly homogeneous high signal intensity, C) and D): loss of signal intensity on frequency-selective fat-saturated images.

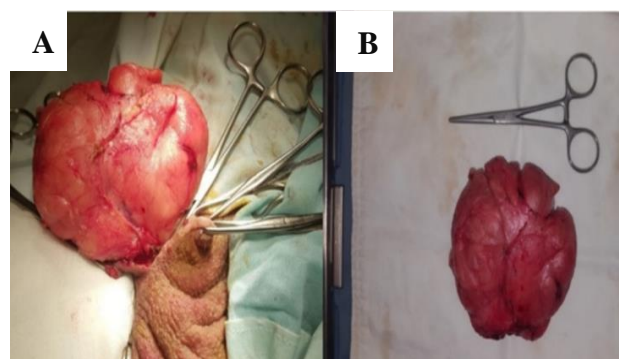


Figure 3: Intra-operator images. A): lipoma excision from the right scrotal wall, B): macroscopic aspect of the scrotal lipoma.

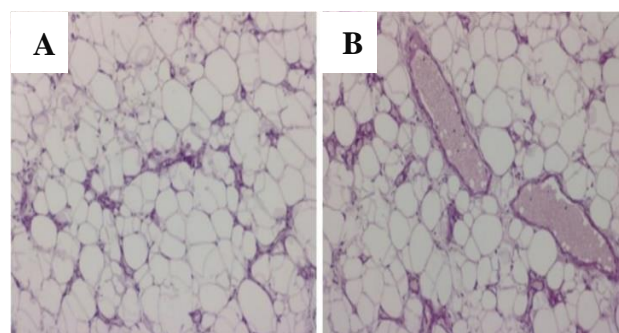


Figure 4: Histological features of the scrotal tumour. A): mature adipose cells, minimally inflamed chronic interstitial lymphocytic infiltration, B): mature adipose cells, blood vessels with slightly dilated lumen, without sarcomatous structures.

DISCUSSION

Scrotal lipomas are benign tumours rarely seen in clinical practice. They can mimic common affections such as an inguinoscrotal hernia, varicocele, hydrocele or a testicular tumour. In almost all scrotal tumour masses, clinical examination is able to differentiate between them.

Usually, an intact external inguinal ring without an exacerbated tumour on exertion, excludes an inguinoscrotal hernia, a palpable painless scrotal swelling associated with vasodilation, complaints or infertility, suggests varicocele, the presence of transillumination differentiates a hydrocele, and a palpable testicle with distinguishable demarcation from the scrotal mass, rather sustains a para testicular or extra testicular tumour than a testicle one.⁸

Furthermore, the correlation between the patient age and the subtype of scrotal lipomas is also mentioned. The primary scrotal lipomas seem to occur predominantly in boys and young men, while other types are commonly found in men over 40 years of age.^{7,9} Also, clinically signs and symptoms are caused by growth.⁷

Thus, in many cases, physical examination leads to a correct diagnosis, there are situations, like in this case, that require comprehensive imagistic examinations, in order to establish the preoperative nature of the scrotal tumour. Ultrasonography is the first choice in the evaluation of a scrotal tumour. It is a non-invasive and accurate route to estimate the size, echotexture and the borders of the mass.³ This exploration can provide information of tumour topography in the scrotum, cystic or solid scrotal masses but it is difficult to distinguish malignancy.¹⁰

On sonography, lipomas present as well-defined, homogeneous hyperechoic lesions, while, the heterogeneous hypoechoic architectures, often containing areas of calcification are suggestive for myxoid, fibrous or vascular tissues.¹¹

In addition, although extra-testicular tumours are usually benign, any painless echogenic mass with heterogeneous architecture on ultrasound and relatively low vascularity should indicate a liposarcoma.¹² In present case, of an elderly man, the clinical aspects, like a painless tumour with a fast growth rate in dimensions, and presence of the heterogeneity on ultrasonographic images, made us to request supplementary imagistic exploration, such as magnetic resonance imaging of the scrotum, which gave us the diagnosis of lipoma.

Magnetic resonance imaging is useful to establish the diagnosis of a lipoma. Most often, lipomas have high signal intensity on T1- and T2-weighted images and also present loss of signal intensity on frequency-selective fat-saturated images.¹³ If the MRI-findings are not conclusive, surgery is recommended, with intraoperative

extemporaneous histological examination of the tumour mass.¹⁴

Surgical excision was the treatment of choice for lipomas, whereas, hemi-scrotectomy with wide excision of the inguinal lymph nodes was recommended in cases of malignancies.¹² No malignancy was observed in the case presented and one-year follow-up revealed no local relapse.

CONCLUSION

Scrotal lipomas can raise different diagnosis issues. Ultrasonography and magnetic resonance imaging can complete the diagnosis in the case of a scrotal tumour with uncertain nature of the lesion. When preoperative diagnosis may not be established, surgical intervention with intraoperative extemporaneous histological examination of the scrotal tumour mass is the procedure of choice.

Funding: No funding sources

Conflict of interest: None declared

Ethical approval: Not required

REFERENCES

1. Federle MP. Diagnostic and surgical imaging anatomy: chest, abdomen, pelvis. Amirsys: 2006; 3: 130-135.
2. Eble JN, Sauter G, Epstein JI, Sesterhenn IA, eds. Pathology and Genetics of Tumours of the Urinary System and Male Genital Organs. France: IARC: 2004; 273-276.
3. Aluko T, Masi Z, Tomaszewski J, Germaine P. Scrotal sac leiomyoma: Case report of a rare benign scrotal mass. Radiology Case Reports. 2018;13(2):411-414.
4. Fabiani A, Principi E, Filosa A, Pieramici T, Fioretti F, Maurelli V, et al. An unusual case of primary intrascrotal lipoma. Arch Ital Urol Androl. 2016;88(4):345-6.
5. Galosi AB, Scarpelli M, Mazzucchelli R, Lopez-Beltran A, Giustini L, Cheng L, et al. Adult primary para testicular mesenchymal tumors with emphasis on a case presentation and discussion of spermatic cord leiomyosarcoma. Diagnostic Pathol. 2014;9(1):90.
6. Fujimura N, Kurokawa K. Primary lipoma of the scrotum. Euro Urol. 1979;5:182-3.
7. Srivastava KN, Agarwal A, Vikram SS, Gupta M. Huge scrotal lipoma posing a diagnostic dilemma: a case report and review of literature. Urol Case Rep. 2017;15:39.
8. Siegel D. Imaging and interventional therapy for varicoceles. Current Urol Rep. 2014;15(4):399.
9. Leyson JF, Doroshov LW, Robbins MA. Extra testicular lipoma: report of 2 cases and a new classification. J Urol. 1976;116(3):324-6.

10. Kaplanoglu V, Kaplanoglu H, Parlak IS, Tatar IG. Giant intrascrotal lipoma. *BMJ Case Rep.* 2013;bcr2013200500.
11. Woodward PJ, Schwab CM, Sesterhenn IA. From the archives of the AFIP: extra testicular scrotal masses: radiologic-pathologic correlation. *Radiographics.* 2003 Jan;23(1):215-40.
12. Cardenosa G, Papanicolaou N, Fung CY, Tung GA, Yoder IC, Althausen AF, et al. Spermatic cord sarcomas: sonographic and CT features. *Urol Radiol.* 1990;12(1):163.
13. Wolfman DJ, Marko J, Gould CF, Sesterhenn IA, Lattin Jr GE. Mesenchymal extra testicular tumors and tumorlike conditions from the radiologic pathology archives. *Radiograph.* 2015;35(7):1943-54.
14. Patel NG, Rajagopalan A, Shrotri NS. Scrotal liposarcoma-a rare extra testicular tumour. *JRSM Short Rep.* 2011;2(12):1-3.

Cite this article as: Berevoescu NI, Stanilescu S, Halcu G, Berevoescu M, Cristian D. Large primary scrotal lipoma with particular presentation. *Int Surg J* 2019;6:597-600.