

Original Research Article

Comparative analysis of clinical, radiological and operative findings in acute abdomen

Mir Zeeshan Ali, Vamsee Krishna Maddu*

Department of General Surgery, JSS Medical College and Hospital, Mysore, Karnataka, India

Received: 18 November 2018

Revised: 22 January 2019

Accepted: 29 January 2019

*Correspondence:

Dr. Vamsee Krishna Maddu,
E-mail: vamseekrishna.m08@gmail.com

Copyright: © the author(s), publisher and licensee Medip Academy. This is an open-access article distributed under the terms of the Creative Commons Attribution Non-Commercial License, which permits unrestricted non-commercial use, distribution, and reproduction in any medium, provided the original work is properly cited.

ABSTRACT

Background: The term acute abdomen refers to signs and symptoms of abdominal pain and tenderness that often requires emergency surgical therapy. The objective of the present study is to compare pre-operative diagnosis based on clinical examination with the operative diagnosis in acute abdomen.

Methods: Total 60 cases of acute abdomen who underwent laparotomy in a tertiary care hospital were analysed prospectively regarding clinical features and also assessed the diagnostic utility of radiological investigations like plain abdominal radiographs, ultrasonography and computed tomography.

Results: Acute abdomen was most common in males and 2nd to 5th decade of life. Appendicitis was most common cause of acute abdomen followed by hollow viscus perforation and intestinal obstruction. Abdominal pain was the most common symptom. Tenderness was the most common sign. Diagnostic utility of x-ray is more in hollow viscus perforation and intestinal obstruction, whereas ultrasonography is diagnostic in 64.3%. Ultrasonography accurately diagnosed acute appendicitis in 74.2%, hollow viscus perforation in 50%, and intestinal obstruction in 60% of patients. 95% clinical accuracy was found when compared to intra operative diagnosis. Kappa is 0.912 ($p < 0.0001$).

Conclusions: Clinical judgement is key to diagnosis of acute abdomen and investigations are only supplementary and cannot replace the clinical decision.

Keywords: Acute abdomen, Acute appendicitis, Hollow viscus perforation, Intestinal obstruction, Laparotomy

INTRODUCTION

Acute abdomen is a condition that demands urgent attention and treatment. The acute abdomen may be caused by an infection, inflammation, vascular occlusion, or obstruction. The patient will usually present with sudden onset of abdominal pain with associated nausea or vomiting. Most patients with an acute abdomen appear ill.

The approach to a patient with an acute abdomen should include a thorough history and physical examination. The location of pain is critical as it may signal a localized

process. However, in patients with free air, it may present with diffuse abdominal pain. Auscultation may reveal absent bowel sounds and palpation may reveal rebound tenderness and guarding, suggestive of peritonitis. The causes of an acute abdomen include appendicitis, perforated peptic ulcer, acute pancreatitis, ruptured sigmoid diverticulum, ovarian torsion, volvulus, ruptured aortic aneurysm, lacerated spleen or liver, and ischemic bowel.¹⁻³

History taking and physical examination form the corner stone of diagnosis.⁴ Equally important is the investigational confirmation of the suspected diagnosis

by laboratory tests and radiologic investigations. In the past 10 years, the ability to accurately determine intra-abdominal pathology by radiologic imaging has allowed earlier and more accurate diagnosis.⁵ And in no other specialty has such dramatic transformation taken place.⁴ Ultrasound is a well-established imaging modality for evaluating the abdomen, as it is non-invasive, portable, readily obtainable, relatively inexpensive, and without the risks of ionizing radiation or iodinated intravenous contrast. In addition, ultrasound has extremely high diagnostic accuracy in many clinical scenarios equivalent or even superior to CT.⁶ Multislice, helical CT is increasingly replacing Ultrasonography (USG) for the evaluation of patients with acute abdominal pain. CT has major advantages over USG: it is extremely fast, and the time burden is often less than that of a USG examination.⁷ The present study aimed at to assess acute abdomen, the effectiveness of radiological investigations in diagnosing acute abdomen and its influence on clinical decision making.

METHODS

The prospective observational study was performed in department of general surgery, JSS hospital, Mysuru, India from November 2016 to May 2018 to compare the pre-operative diagnosis based on clinical examination and investigation with the operative diagnosis in acute abdomen.

Inclusion criteria

All patients who presented to emergency department with clinical diagnosis of acute abdomen were included in the study.

Exclusion criteria

- Pediatric age group (14 years and below)
- Acute abdomen in pregnancy
- Gynecological causes of acute abdomen
- Patients managed conservatively.

Total 60 patients who underwent laparotomy were evaluated. imaging studies were selected based on clinical diagnosis.

Statistical analysis

Descriptive statistics (mean, standard deviation, frequency, percentage), Chi-square test, crammers v test, student t test was applied wherever applicable to find out the level of significance. P value <0.05 will be considered as the level of significance.

RESULTS

Total 60 patients of acute abdomen who underwent laparotomy were analysed. Over all acute abdomen was most common in male gender and appendicitis was more

common in 36.1±13.6 years age group; hollow viscus perforation was most common in 51.1±18.0 years age group and intestinal obstruction was most common in 33.8±12.2 years age group.

Out of 33 patients diagnosed clinically as acute appendicitis, intra operatively appendicitis was found in 30 patients and 3 patients found to have appendicular perforation. Duodenal perforation is the most common among hollow viscus perforation followed by gastric and ileal perforation. In one patient ileal perforation was associated with caecal growth which postoperatively was found to be adenocarcinoma of caecum. Among the causes of intestinal obstruction adhesions were most common and the other causes were meckels diverticulum and the cause couldn't be found in one case.

Table 1: Intra operative diagnosis of acute abdomen.

Intra operative diagnosis	Count	Column N %
Acute appendicitis	30	50.0%
Intestinal obstruction	5	8.3%
Perforations	25	41.7%

Table 2: Clinical diagnosis of acute abdomen.

Clinical diagnosis	Count	Column N %
Acute appendicitis	33	55.0%
Hollow viscus perforation	22	36.7%
Intestinal obstruction	5	8.3%

As shown in Table 1, out of 60 patients intraoperatively 30 patients had acute appendicitis, 25 patients had hollow viscus perforation, 5 patients had intestinal obstruction.

As shown in Table 2 out of 60 total patients clinically 33 patients were diagnosed as acute appendicitis, 22 patients were diagnosed as hollow viscus perforation, 5 patients were diagnosed as intestinal obstruction.

Table 2: Age wise distribution.

Clinical diagnosis	Age in years	
	Mean	SD
Acute appendicitis	36.1	13.6
Hollow viscus perforation	51.1	18.0
Intestinal obstruction	33.8	12.2

As shown in Table 3, Acute appendicitis is more common in age group i.e. 36.1±13.6 yrs, Hollow viscus perforation is more common in age group i.e.51.1±18 yrs, Intestinal obstruction is more common in 33±12.2 yrs.

As shown in Figure 1, out of total 60 patients pain abdomen was the leading symptom present in 60 patients, followed by vomiting in 43 patients and fever in 17

patients, abdominal distension in 9, constipation in 2 patients and diarrhoea in 5 patients.

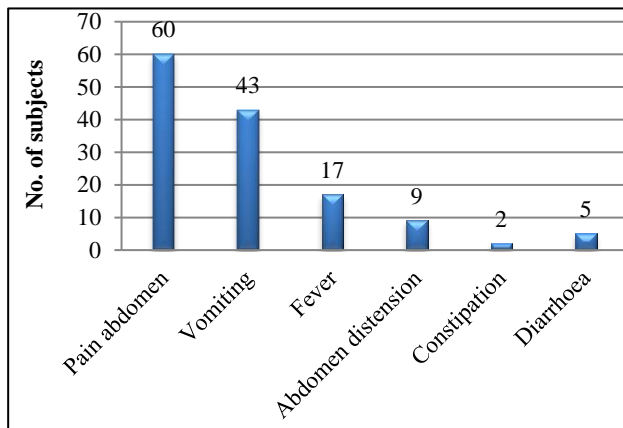


Figure 1: Symptoms of acute abdomen.

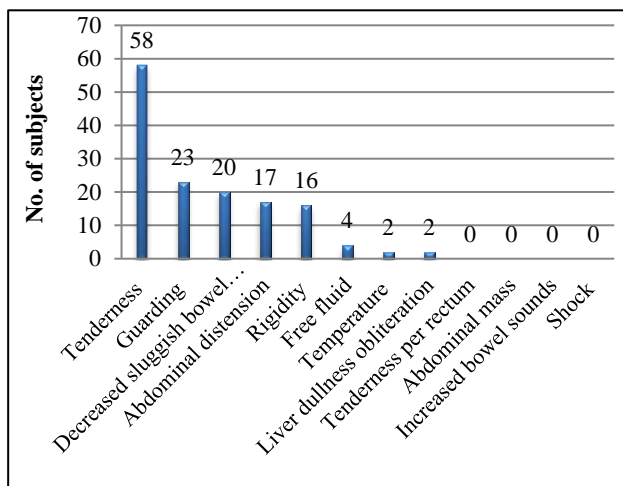


Figure 2: Signs of acute abdomen.

As shown in Figure 2, out of total 60 patients' tenderness was the leading sign present in 58 patients, followed by

guarding in 23 patients and decreased/sluggish bowel sounds in 20 patients, abdominal distension in 17 patients, rigidity in 16 patients, free fluid in the abdomen in 4 patients, rise in temperature in 2 patients and liver dullness obliteration in 2 patients.

As shown in Table 4 out of 33 patients clinically diagnosed as acute appendicitis, pain abdomen was present in 33 patients, vomiting is present in 21 patients, fever is present in 12 patients, diarrhea in 3 patients.

As shown in Table 5 out of 22 patients clinically diagnosed as hollow viscus perforation, pain abdomen was the leading symptom present in 22 patients, followed by vomiting in 17 patients, abdominal distension in 7 patients, fever in 5 patients, diarrhea in 2 patients, constipation in 2 patients.

As shown in Table 6 out of 5 patients clinically diagnosed as intestinal obstruction, pain abdomen and vomiting were the leading symptoms present in 5 patients each, followed by abdominal distension in 2 patients.

As shown in Table 7 out of 33 patients diagnosed clinically as acute appendicitis, leading sign was tenderness present in 31 patients, followed by rise in body temperature and guarding in 2 patients each, abdominal distension in 1 patient.

Out of 22 patients diagnosed clinically as hollow viscus perforation, leading sign was tenderness present in 22 patients, followed by guarding in 20 patients and decreased/sluggish bowel sounds in 18 patients, rigidity in 13 patients, abdominal distension in 11 patients, free fluid in abdomen in 4 patients, liver dullness in 2 patients

Out of 5 patients diagnosed clinically as intestinal obstruction, leading signs were tenderness and abdominal distension present in 5 patients each, followed by rigidity in 3 patients, guarding in 2 patients, decreased /sluggish bowel sounds in 2 patients.

Table 4: Symptoms of acute appendicitis.

Clinical diagnosis	Symptoms					
	Pain abdomen	Vomiting	Fever	Diarrhoea	Constipation	Abdomen distension
Acute appendicitis (33)	Count	Count	Count	Count	Count	Count
	33	21	12	3	0	0

Table 5: Symptoms of hollow viscus perforation.

Clinical diagnosis	Symptoms					
	Pain abdomen	Vomiting	Abdomen distension	Fever	Diarrhoea	Constipation
Hollow viscus perforation (22)	Count	Count	Count	Count	Count	Count
	22	17	7	5	2	2

Table 6: Symptoms of intestinal obstruction.

Clinical diagnosis	Symptoms					
	Pain abdomen	Vomiting	Abdomen distension	Constipation	Fever	Diarrhoea
	Count	Count	Count	Count	Count	Count
Intestinal obstruction (5)	5	5	2	0	0	0

Table 7: Signs of acute appendicitis and hollow viscus perforation and intestinal obstruction.

Clinical diagnosis	Signs											
	Temperature	Tenderness	Guarding	Rigidity	Abdominal distention	Liver dullness obliteration	Free fluid	Tenderness per rectum	Abdominal mass	Increased bowel sounds	Decreased sluggish bowel sounds	Shock
Acute appendicitis	2	31	2	0	1	0	0	0	0	0	0	0
Hollow viscus perforation	0	22	20	13	11	2	4	0	0	0	18	0
Intestinal obstruction	0	5	2	3	5	0	0	0	0	0	2	0

Table 8: Signs of acute appendicitis and hollow viscus perforation and intestinal obstruction.

Clinical diagnosis		Acute appendicitis		Hollow viscus perforation		Intestinal obstruction	
		Count	Column N %	Count	Column N %	Count	Column N %
X-ray done	Not done	33	100.0%	1	4.5%	0	0%
	Done	0	0%	21	95.5%	5	100.0%
USG done	Not done	2	6.1%	2	9.1%	0	.0%
	Done	31	93.9%	20	90.9%	5	100.0%
CT done	Not done	31	93.9%	20	90.9%	4	80.0%
	Done	2	6.1%	2	9.1%	1	20.0%

Table 9: Overall diagnostic accuracy of radiological investigations.

Radiological investigation		Count	Column N %
X ray	Diagnostic	26	100
	Non-diagnostic	0	0
USG abdomen pelvis	Diagnostic	36	64.3
	Non-diagnostic	20	35.7
CT abdomen pelvis	Diagnostic	5	100
	Non-diagnostic	0	0

As shown in Table 8, out of 60 patients x-ray was done in 26 patients, USG was done in 56 patients, CT abdomen and pelvis was done in 5 patients; these radiological investigations were done on basis of clinical scenario.

As shown in Table 9, out of 60 patients of acute abdomen, X ray was diagnostic in 100%, USG abdomen was diagnostic in 64.35%; CT abdomen and pelvis was diagnostic in 100%.

As shown in Table 10, a sum of 9.1% patients diagnosed clinically as acute appendicitis were found to have hollow viscus perforation intraoperatively. This difference is statistically significant (p=0.082) and there was 95% Accuracy of clinical diagnosis compared to intra op diagnosis. Kappa is 0.912 (p<0.0001).

DISCUSSION

Our study was conducted over a period of 18 months from November 2016 -May 2018 at JSS Hospital, Mysuru, Karnaka state, India. According to our results in 60 patients, the age group most commonly affected was 21-40 years overall which is in accordance with various other studies.⁸⁻¹¹

Acute appendicitis is the most common cause of acute abdomen followed by hollow viscus perforation and intestinal obstruction which is in accordance with results shown by Katarzyna et al.¹² In appendicitis it was 21-40 years and in peptic ulcer perforations >61 years of age group showed predominance.

There is a sex predilection with males having predominance in in all forms of acute abdomen presentation.

Pain abdomen was significantly the most common cause of presentation to the hospital; seen in 60 patients i.e.

100% followed by vomiting seen in 43 patients (71.7%). These symptoms were commonly seen irrespective of the final diagnosis of acute abdomen. The leading signs observed were that of tenderness (98.3%) followed by guarding (39%) and decreased bowel sounds (33.9%).

Table 10: Comparison of clinical and intra-operative diagnosis.

Intra operative diagnosis		Clinical diagnosis					
		Acute appendicitis		Hollow viscous		Intestinal obstruction	
		perforation		perforation			
		Count	%	Count	%	Count	%
Intra op merged	Acute Appendicitis	30	90.9%	0	0%	0	0%
	Perforations	3	9.1%	22	100.0%	0	0%
	Intestinal obstruction	0	0%	0	0%	5	100.0%

P=0.082 (McNemar Test)

The most common cause of presentation to our hospital with acute abdomen was acute appendicitis seen in 30 patients (50%). The second most common cause was perforation peritonitis; seen in 25 patients (41.7%) of which most common was duodenal perforations seen in 8 patients (13.3%) followed by Intestinal obstruction in 5 patients (8.3%).

Thorough clinical examination with a detailed history was found to be diagnostic in correlation with the surgical findings. Radiological tests such as X-ray was found to be accurate especially in the diagnosis of perforation and intestinal obstruction with diagnostic accuracy of 100%.

The diagnostic utility of USG abdomen and pelvis was not statistically significant between these three clinical variables i.e. acute appendicitis, hollow viscous perforation and intestinal obstruction (p=0.2) but showed 74.2% accuracy for acute appendicitis only. Highest accuracy of ultrasound was found in acute appendicitis which is in accordance with other studies.^{13,14}

Routine blood investigations such as total leukocyte count was elevated in 19 patients of acute appendicitis (57.6 %) and 12 patients of hollow viscous perforations (54.5%) and 5 patients of intestinal obstruction (100%) and this was found to be statistically significant with p=0.001. Neutrophil count was raised in 21 out of 30 patients of acute appendicitis (63.6%), 15 patients of hollow viscous perforation (68.2%) and 4 patients of intestinal obstruction (80%) and this was not found to be statistically significant (p=0.4).

Out of 33 patients diagnosed clinically with acute appendicitis 30 patients were found to have appendicitis intra-operatively (90.9%) and 3 patients were diagnosed to have appendicular perforation. Surgical findings in

hollow viscous perforation and intestinal obstruction had 100% correlation with clinical diagnosis. Present study showed 95% accuracy of clinical diagnosis compared to the intra-operative diagnosis. Kappa is 0.912 (p<0.001).

The differences in these three variables of clinical examination, radiological and intra-operative findings were not found to be statistically significant. (p=0.082, Mc Nemar test).

A prospective observational study conducted on 125 patients in Rohtak University of Health Sciences, also showed similar results with USG being specific for appendicitis and erect X-ray abdomen showing highest sensitivity in obstruction.¹⁵ This study also had a similar outcome of concluding that clinical judgement is accurate for the diagnosis of acute abdomen which cannot be replaced by investigations.

CONCLUSION

Acute appendicitis was the most common presentation of acute abdomen in our study. Pain abdomen and vomiting were the leading symptoms, while tenderness and guarding were the leading signs. Clinical examination was the found to be statistically correlating with the intra-operative findings. Radiological investigations like USG had high sensitivity for appendicitis but overall low specificity, while Erect x- ray was diagnostic of perforation and Intestinal obstruction. Thus, clinical judgement is key to the diagnosis of acute abdomen with radiological and blood investigations only aiding in its management and cannot replace the clinical decision.

Funding: No funding sources

Conflict of interest: None declared

Ethical approval: The study was approved by the Institutional Ethics Committee

REFERENCES

1. Elhardello OA, MacFie J. Digital rectal examination in patients with acute abdominal pain. *Emerg Med J.* 2018 Sep;35(9):579-80.
2. Verki MM, Motamed H. Rectus muscle hematoma as a rare differential diagnosis of acute abdomen; a case report. *Emergency.* 2018;6(1):e28.
3. Kaushal-Deep SM, Anees A, Khan S, Khan MA, Lodhi M. Primary cecal pathologies presenting as acute abdomen and critical appraisal of their current management strategies in emergency settings with review of literature. *Int J Crit Illness Injury Sci.* 2018 Apr 1;8(2):90.
4. Baker SR. The abdominal plain film. What will be its role in the future?. *Radiologic Clin North Am.* 1993 Nov;31(6):1335-44.
5. Sabiston DC Jr. and Lysterly KM. *Text book of Surgery. The biologic basis of modern surgical practice.* 15th ed. Harcourt Asia PTE Ltd: Saunders; 1997.
6. Scoutt LM, Sawyers SR, Bokhari J, Hamper UM. Ultrasound evaluation of the acute abdomen. *Ultrasound Clin.* 2007 Jul 1;2(3):493-523.
7. Puylaert JB. Ultrasonography of the acute abdomen: gastrointestinal conditions. *Radiol Clin.* 2003 Nov 1;41(6):1227-42.
8. Memon AA, Bhutto AA, Shaikh GS, Jokhio A, Soomro QA. Spectrum of diseases in patients with non-traumatic acute abdomen. *J Liaquat Uni Med Health Sci.* 2008 Sep;7(3):180-3.
9. Laal M, Mardanloo A. Acute Abdomen; Pre and Post-Laparotomy Diagnosis. *Int J Collaborative Res Internal Med Public Health.* 2009 Jan 1;1(5):157-65.
10. Matin MA, Siddiq AK, Hasan MM. Acute abdomen in a peripheral military hospital. *J Armed Forces Med College Bangladesh.* 2009 Dec;5(2):36-9.
11. Chhetri RK, Shrestha ML. A comparative study of pre-operative with operative diagnosis in acute abdomen. *Kathmanolu university Med J* 2005 Jun;3(2):107-10.
12. Padaszyńska K, Celnik A, Pomorski L. Patients subject to surgery due to acute abdominal disorders during the period between 2001-2004. *Polish J Surg.* 2012 Dec 1;84(10):488-94.
13. Squires R, Postier RG; *Acute Abdomen.* In: Townsend C, Beauchamp R D, Evers BM, Mattox K, editors. *Sabiston Textbook of Surgery.* 19th ed. Saunders Elsevier; 2012.
14. Danse EM, Kartheuser A, Paterson HM, Laterre PF. Color Doppler sonography of small bowel wall changes in 21 consecutive cases of acute mesenteric ischemia. *JBR-BTR.* 2009;92(4):202-6.
15. Arora B, Gupta A, Nandi S, Sarwal A, Goyal P, Gogna S, et al. Comparative analysis of clinical, radiological and operative findings in acute abdomen. *Int J Enhanced Res Med Dental Care.* 2015;2(1):1590-2349.

Cite this article as: Ali MZ, Maddu VK. Comparative analysis of clinical, radiological and operative findings in acute abdomen. *Int Surg J* 2019;6:806-11.