

## Original Research Article

# Incidence and implications of spleniculi: a five-year experience

Sridar Govindaraj<sup>1\*</sup>, A. P. Roshini<sup>2</sup>

<sup>1</sup>Department of General Surgery, St. John's Medical College and Hospital, Bengaluru, Karnataka, India

<sup>2</sup>Intern, St. John's Medical College and Hospital, Bengaluru, Karnataka, India

**Received:** 15 November 2018

**Accepted:** 08 December 2018

### \*Correspondence:

Dr. Sridar Govindaraj,

E-mail: [sridar\\_sasi@yahoo.com](mailto:sridar_sasi@yahoo.com)

**Copyright:** © the author(s), publisher and licensee Medip Academy. This is an open-access article distributed under the terms of the Creative Commons Attribution Non-Commercial License, which permits unrestricted non-commercial use, distribution, and reproduction in any medium, provided the original work is properly cited.

## ABSTRACT

**Background:** Spleniculi or accessory spleen, is a congenital anomaly occurring in 10% of individuals. Spleniculi resembles normal spleen in structure and in immunological function. Certain hematological and radiological investigations can indicate residual splenic function. They can enlarge following splenectomy and be the source of recurrent symptoms in those operated on for hematological disorders.

**Methods:** Authors did a retrospective study in a tertiary care hospital to estimate the incidence and to describe the location and number of spleniculi in patients undergoing splenectomy, both elective and emergency, over a 5-year period - October 2013 to October 2018. Total patients included was 186.

**Results:** Majority of the patients were in the age group of 18-45 years. 16 (8.6%) had spleniculi, found incidentally and confirmed histopathologically. Hematological disorders, out of which idiopathic thrombocytopenic purpura 70 (49.6%) was the most common indication. Commonest location was in the hilum, 12 (75%), second being, near the tail of pancreas. 1 patient presented with a left hypochondriac mass, which was confirmed as enlarged spleniculi on histopathology, post - relook surgery.

**Conclusions:** Accessory spleens are asymptomatic and have a high chance of being overlooked during splenectomy, which could be one of the causes of relapse in hematological disorders.

**Keywords:** Accessory spleen, Hematological disorders, Splenectomy, Spleniculi, Technetium 99m

## INTRODUCTION

Ectopic splenic tissue can be either congenital or acquired. Spleniculi or accessory spleen, is a congenital anomaly occurring in 10% of individuals.<sup>1</sup> On the other hand, splenosis or auto-transplantation of splenic tissue, incidence of 67%, occurs when cells from a damaged spleen seed elsewhere on the peritoneal surface or omentum, during splenectomy or trauma, and grow into nodules of differentiated splenic tissue with varying size.

Accessory spleen derives their blood supply from branches of the splenic artery. This is in contrast to splenosis nodules, which receive their blood supply from

newly formed arteries penetrating the capsule. The splenosis nodules are usually numerous (>400) and can be intra- or extra-peritoneal. Spleniculi may be solitary or multiple, seldom >6 and are more commonly involved in hematological disorders of the spleen. Embryologically, during the 5<sup>th</sup> week, spleen arises in the dorsal mesogastrium as the mesenchymal tissue. Incomplete fusion of splenic buds causes accessory spleens to develop.<sup>2</sup> Common sites of occurrence include the splenic hilum (75%) and the 2<sup>nd</sup> most common being near pancreatic tail (20%).<sup>3</sup>

Haematological tests that indicate hyposplenism post-splenectomy include: increased pitted red cell count (red blood cells with membrane abnormalities), presence of

Howell Jolly body (persistent nuclear fragments in red blood cells), monocytosis, lymphocytosis and thrombocytosis. Others are a reduced IgM, properdin, tuftsin and opsonin.<sup>4,5</sup> Increase in tuftsin activity after splenectomy has been found to correlate with residual splenic function.<sup>6</sup> Abdominal USG and CT are readily available diagnostic tests. Drawbacks are that the nature of accessory spleens resembles tumours of adjacent organs or metastasis.<sup>7</sup> Technetium (Tc 99m) labelled radionuclide scan, is a highly specific investigation, with the disadvantage of not being readily available and cost. Another limitation is that hepatic uptake of technetium obscures the presence of splenic foci in the upper abdomen.<sup>8</sup> Splenic artery doppler sonography, is based on the principle of measurement of vascular resistance (RI) of the splenic artery as described by Herneth et al, Complete clearance of splenic tissue caused the RI value to increase.<sup>9</sup> The RI values in splenosis, is similar to non-splenectomized patients and is reduced.

Accessory spleens can enlarge following splenectomy and be the source of recurrent symptoms in those operated on for haematological disorders. Accessory spleens may be overlooked during splenectomy. Consequently, a second splenectomy may be necessary. Most patients are asymptomatic, therefore, it becomes important to establish a proper and a meticulous search for spleniculi at the time of initial surgery, to prevent relapses.

The objectives of the present study were to estimate the incidence spleniculi in patients undergoing splenectomy over a 5-year period in a tertiary care centre. And to describe the location and number of spleniculi in patient undergoing splenectomy

## METHODS

A retrospective cohort study, through chart review, was conducted in authors' hospital. The study included all patients who underwent splenectomy in the past 5 years, from October 2013 to October 2018. Inclusion criteria was all patients aged more than 18 years, both males and females, who underwent splenectomy, both emergency and elective. They should have undergone splenectomy in authors' hospital, either open or laparoscopic. Exclusion criteria were those patients with incomplete data. The data collected included age, gender, underlying comorbidities, indication for splenectomy, duration of underlying condition, emergency or elective surgery, number, size and location of spleniculi, number of patients with relapse secondary to accessory spleen. Details of a total of 186 patients was collected.

All statistical analyses were performed using SPSS V 16. Incidence of spleniculi was represented as the number of patients with spleniculi by the total number of patients recruited for the study over the 5years period. Descriptive statistics, for age, gender distribution, number and location of spleniculi, sizes of spleniculi was done using

frequencies, percentages, median and standard deviation. Institutional Ethical Clearance (Ref. No-220/2018) was obtained prior to starting the study.

## RESULTS

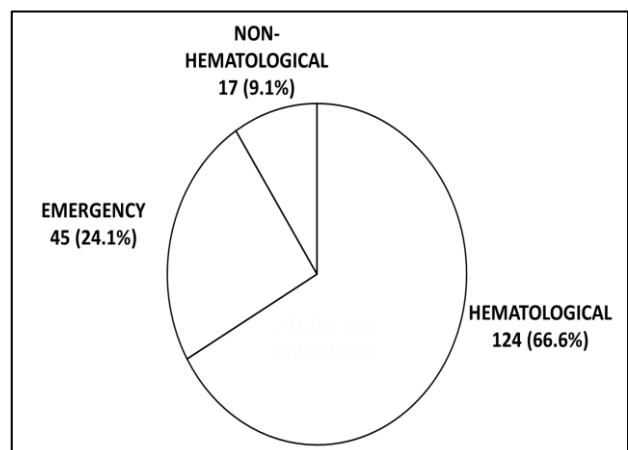
A total of 186 patients underwent splenectomy in the 5-year period analyzed. Patients age ranged from 18 to 78years, with the mean age being  $36.6 \pm 14.48$  years (Table 1). 86 (46.2%) were women. 141 (75.8%) had an elective splenectomy, conventional laparoscopic splenectomy or hand-assisted splenectomy.

**Table 1: Age distribution of 186 patients, in years.**

Age group (years)	No. (%)
18-45	102 (72.3%)
40-60	26 (18.4%)
>60	13 (9.2%)

Indication was hematological in 124 (66.6%) patients, most common being Idiopathic thrombocytopenic purpura, 70 (49.6%). Other non-hematological indications were chronic pancreatitis, pancreatic neuroendocrine tumour in the tail of pancreas, hydatid cyst and splenic abscess. Emergency splenectomy was done secondary to blunt trauma to the abdomen or spontaneous rupture of the spleen (Figure 1) Of all the patients, 16 (8.6%) had spleniculi, detected incidentally. Previous radiological investigations did not reveal the presence of accessory spleen.

Most common location was in the splenic hilum -12 (75%), second being, near the tail of pancreas. All were sessile spleniculi, with an intact capsule. Three patients had 2 spleniculi, with sizes ranging from 2 x 0.5 x 0.4cm and 1 x 0.2 x 0.3cm. Histopathology showed an intact capsule with red and white pulp, which confirmed a spleniculi. 1 patient had a re-look surgery, a year post-splenectomy, wherein she presented with a left hypochondriac mass and CECT was suggestive of an enlarged spleniculi and was confirmed on histopathology.



**Figure 1: Indications of splenectomy.**

## DISCUSSION

Incidence of spleniculi in present study was 8.6%, which is less compared to the others. All patients had the spleniculi detected and removed, incidentally on laparotomy or Laparoscopic Splenectomy (LS) or Hand-Assisted Splenectomy (HALS), as per the norm.<sup>1</sup> USG and CT scans done previously did not detect them, probably due to the small size.

Most common location is the splenic hilum, which was also the same in present case. Other locations are, in order of decreasing incidence, 5% along the splenic artery, and remaining in the gastrosplenic, splenocolic, or gastrocolic ligament.<sup>3</sup> Differentiation between spleniculi and splenosis nodule can be done histologically. Accessory spleens have well defined capsule, hilum, trabeculae, white pulp with malpighian follicles having central arteriole and red pulp. Splenosis nodules are also surrounded by capsule but malpighian follicles and central arteriole are not formed. In studied patients, their splenic structure was confirmed histologically.

Spleniculi is approximately 1cm in diameter, but can also vary from microscopic deposits, not visible on CT to 2-3cm in diameter.<sup>10</sup> All studied patients have had spleniculi sizes ranging from 0.5 x 0.2 x 0.1cm to 2 x 0.8 x 0.5cm. Most patients are asymptomatic, with rare complications being rupture, torsion and strangulation, bowel obstruction and produce defects on upper gastrointestinal radiographs suggestive of gastric neoplasms.<sup>11</sup> Spleniculi resembles normal spleen in structure and in immunological function. Many previous researchers have shown concern about accessory spleens in patients with ITP since evidence emerged that sustained remission was obtained after accessory splenectomy in patients with recurrent ITP.<sup>12</sup> Only 1 patient in current study had a relapse secondary to a massively enlarged accessory spleen.

## CONCLUSION

Accessory spleens may be overlooked during splenectomy, and consequently, a second surgery may be necessary in cases of patients with hematological disorders with relapse. Therefore, it becomes imperative to establish a meticulous search for spleniculi at the time of first surgery, to prevent relapses.

*Funding: No funding sources*

*Conflict of interest: None declared*

*Ethical approval: The study was approved by the Institutional Ethics Committee*

## REFERENCES

1. Spencer GR, Bird C, Prothero DL, Brown TR, Mackenzie FA, Phillips MJ. Spleen scanning with <sup>99</sup>Tc-labelled red blood cells after splenectomy. *Br J Surg.* 1981 Jun;68(6):412-4.
2. Impellizzeri P, Montalto AS, Borruto FA, Antonuccio P, Scalfari G, Arena F, et al. Accessory spleen torsion: rare cause of acute abdomen in children and review of literature. *J Pediatr Surg.* 2009 Sep 1;44(9):e15-8.
3. Babcock TL, Coker DD, Haynes JL, Conklin HB. Infarction of an accessory spleen causing an acute abdomen. *Am J Surg.* 1974 Mar 1;127(3):336-7.
4. Horton J, Ogden ME, Williams S, Coln D. The importance of splenic blood flow in clearing pneumococcal organisms. *Ann Surg.* 1982 Feb;195(2):172-6.
5. William BM, Corazza GR. Hyposplenism: a comprehensive review. Part I: basic concepts and causes. *Hematol.* 2007 Feb 1;12(1):1-3.
6. Zoli G, Corazza GR, D'amato G, Bartoli R, Baldoni F, Gasbarrini G. Splenic autotransplantation after splenectomy: tuftsin activity correlates with residual splenic function. *Br J Surg.* 1994 May;81(5):716-8.
7. Petroianu A, Resende V, Da Silva RG. Late follow-up of patients submitted to subtotal splenectomy. *Int J Surg.* 2006;4(3):172-8.
8. Resende V, Petroianu A. Functions of the splenic remnant after subtotal splenectomy for treatment of severe splenic injuries. *Am J Surg.* 2003 Apr 1; 185(4): 311-5.
9. Herneth AM, Pokieser P, Philipp MO, Bader TR, Helbich TH, Mallek R, et al. Role of Doppler sonography in the evaluation of accessory spleens after splenectomy. *J Ultrasound Med.* 2001 Dec;20(12):1347-51.
10. Mohan H, Amanjit B, Bhardwaj S, Handa U. Splenunculi-Report of three cases. *J Anat Soc India.* 2002;51:70-1.
11. Olsen WR, Beaudoin DE. Increased incidence of accessory spleens in hematologic disease. *Arch Surg.* 1969 Jun 1;98(6):762-3.
12. Verheyden C, Beart JR, Clifton MD, Phyllyk RL. Accessory splenectomy in management of recurrent idiopathic thrombocytopenic purpura. *In Mayo Clinic Proceedings.* 1978;53(7):442-6.

**Cite this article as:** Govindaraj S, Roshini AP. Incidence and implications of spleniculi: a five-year experience. *Int Surg J* 2019;6:98-100.