

## Case Report

# Massive left lobe liver cyst: a rare case report and review of literature

**Ramula Muthammal\*, Arivazagan Natarajan, Mohan Raj, Ramprasath Radhakrishnan**

Department of Surgery, Karpaga Vinayaga Institute of Medical Sciences, Kancheepuram District, Tamil Nadu, India

**Received:** 13 November 2018

**Accepted:** 11 December 2018

**\*Correspondence:**

Dr. Ramula Muthammal,

E-mail: [ramuladurai@gmail.com](mailto:ramuladurai@gmail.com)

**Copyright:** © the author(s), publisher and licensee Medip Academy. This is an open-access article distributed under the terms of the Creative Commons Attribution Non-Commercial License, which permits unrestricted non-commercial use, distribution, and reproduction in any medium, provided the original work is properly cited.

### ABSTRACT

Huge Cyst of the liver not frequently found. This case of massive liver cyst (left lobe) in a female patient is reported for its rarity. In this case, the patient presented with no other complaints except distention of abdomen and vague pain abdomen. To highlight diagnostic challenges and treatment options available to rural population, that is affordable and accessible. A 57 years old female patient from nearby village, presented with distention of abdomen for 5years, which was small to start with and gradually increasing in size to attain the present size. Preoperatively, it was a huge tensely cystic swelling arising from left lobe of liver occupying whole upper abdomen. Swelling appeared to be arising from segment II and III (Couinaud system), right lobe compressed to a rim. The cyst was opened anteriorly and drained 4.8l of clear fluid. Marsupialization of the cyst was done. Though huge cystic swellings are comparatively rare, they should be considered in the pre-operative differential diagnosis of abdominal masses. They can be easily diagnosed and managed in hospitals with limited resources and are affordable to the patients also.

**Keywords:** Laparotomy, Massive liver cyst, Marsupialization

## INTRODUCTION

Non-parasitic, solitary cysts are referred as simple liver cyst.<sup>1</sup> Etiology of liver cyst not known but many studies recorded it is congenital.<sup>2</sup> Though they attain mammoth size, initially they are asymptomatic and no systemic side effects.

So, the patients come to hospital only when they develop complications such as huge distention of abdomen, rupture, haemorrhage or infection.<sup>3</sup> Management of huge liver cysts has many options such as aspiration, drainage, sclerosants, and fenestration. Fenestration, excision and marsupialization of the cyst can be done either by laparoscopy and laparotomy.<sup>4</sup>

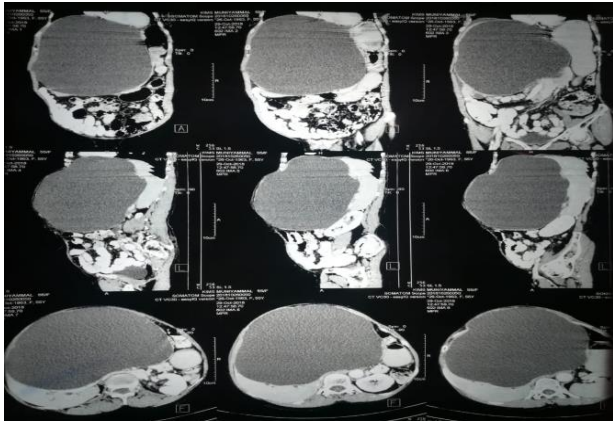
This case was presented for its rarity, limited investigations options, diagnostic dilemma and to stress that these cases can be managed successfully with available limited resources in rural set up.

## CASE REPORT

Fifty-seven-year-old female, farmer's wife, initially admitted in Gynae ward as a case of ovarian cyst referred to general surgery department with ultrasound report of cystic lesion arising from liver. Patient had only complaint of distension abdomen one-year duration, pain and dyspepsia for one month. She reported to the hospital since her abdomen distention limited her daily chorus. Patient was moderately built dyspepsia with normal bowel and bladder habits. No history of fever, vomiting, injury, or hospitalization.

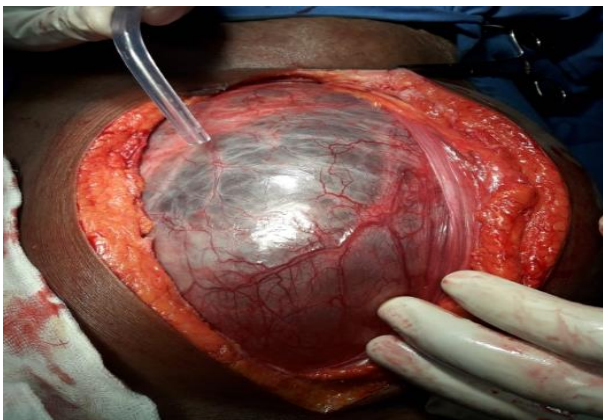
On examination moderately nourished, not anemic, abdomen distended, groins free, liver spleen not palpable because of the mass. Mass was 25x20cm in sizing occupying all quadrants of abdomen except pelvis. Mass plane found to be intra-abdominal with restricted mobility. Dull on percussion, bowel sounds heard normally. Per vaginal examination atrophy uterus and per

rectal examination nothing found significant. Routine investigations like complete blood count, random blood sugar, renal function tests, liver function tests and coagulation profile all found within normal limits. Plain X-ray abdomen erect view was normal except for mild elevation of right diaphragm. Ultra-sonogram showed a cystic hypo dense mass occupying all quadrants except pelvis and impression was probably cystic swelling of hepatic origin or mesenteric cyst. CT scan was done preoperatively for more clarity and it confirmed low attenuated space occupying lesion arising from Liver (Figure 1).



**Figure 1: Hypo dense cystic lesion 19.6x23.0cm, possibility of large cystic liver lesion.**

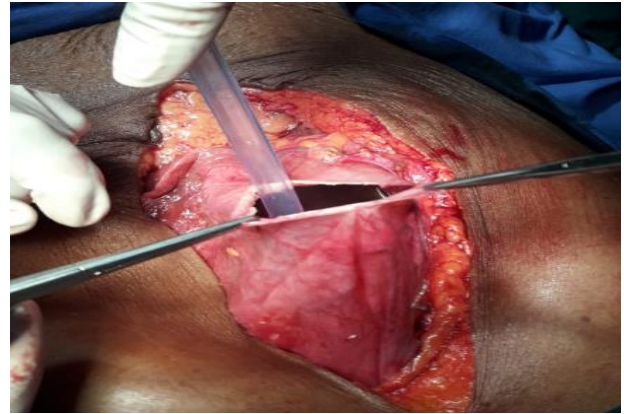A preoperative diagnosis of cystic swelling probably hepatic cyst was made and patient was taken up explorative laparotomy. Abdomen opened by midline incision on opening the peritoneum author found a cystic swelling of 25x20cm cystic swelling occupying entire peritoneal cavity (Figure 2).



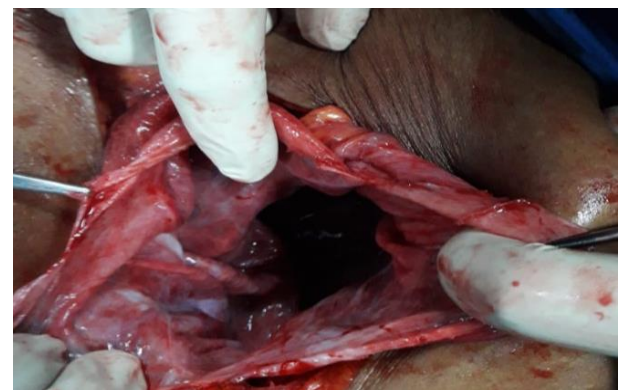**Figure 2: Intra operative picture of left hepatic cyst.**

Because of the mammoth size, cyst was opened and clear fluid of 4.8lts serous fluid was drained (Figure 3). Stomach, lesser sac, and small bowels found normal. Cyst was found to arise from left lobe of liver (Figure 4) and right lobe of liver compressed to thin rim of tissue in the periphery (Figure 5). Hemostasis was obtained.

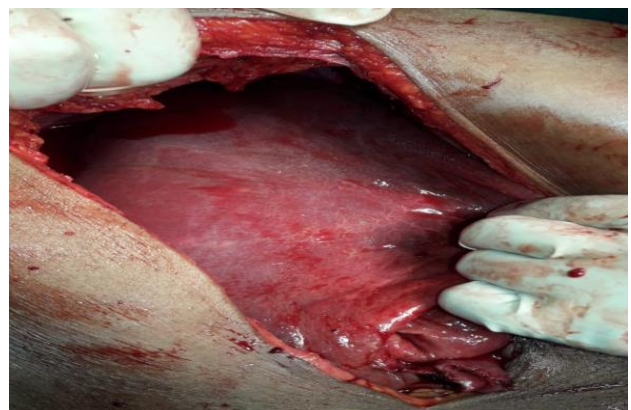
Wound closed with a drain. Patient recovered well without any complications. Post-operative ultrasound revealed no collection, hence patient discharged on the tenth post-operative day. Patient was being regularly followed up in surgical outpatient department.



**Figure 3: Cyst wall opened and drainage of fluid was done.**



**Figure 4: Fenestration of cyst showing cavity of liver post drainage.**



**Figure 5: Right lobe of the liver.**

## DISCUSSION

Hepatic cysts are more common in women than men with predilection for right lobe (83%) though cysts remain

dormant for many years they become symptomatic only in 6<sup>th</sup> decade in most of the cases.<sup>5</sup> Only 5% of the patients present with symptoms usually abdominal distention.<sup>6</sup> Literatures have reported that Right lobe was involved in 83% of cases but in this case author found in the left lobe of liver. Stănescu CA et al, in his article reported 75% of treated liver cysts found in left lobe of liver.<sup>7</sup> Patients usually remain symptom free and don't need any kind of treatment. Only when the cyst becomes quite large patients seek treatment for distention of abdomen and pain due to rupture, infection or hemorrhage. Most of these cysts are considered congenital and chromosome 16 was considered as trigger.<sup>7</sup> Simple liver cysts are more common in females because these cysts are considered having a possible etiological link to oestrogens.<sup>8</sup>

The cyst contained 4.8liters of clear fluid and there was no communication with intra hepatic biliary tree. Author reported this case because of its size, diagnostic difficulties, and treatment options available with limited resources setting and affordable treatment options for poor patients. The largest size liver cyst was reported by Burch JC et al, where 17liters fluid was drained.<sup>9</sup> Preferred treatment is laparotomy or laparoscopic fenestration and drainage.<sup>9,10</sup> Percutaneous drainage under ultrasound guidance is not an option because of high rates of recurrence.

## CONCLUSION

Simple liver cysts are common in female patients in 6<sup>th</sup> decades. Three fourth of the cases remain asymptomatic. Surgery by open or laparoscopic fenestration or marsupialization is the standard treatment of choice with close follow-up. The limits of minimally invasive approach in hepatic cystic disease are location of the cyst, liver segments involved, technical expertise available, and affordability of the patients.

*Funding: No funding sources*

*Conflict of interest: None declared*

*Ethical approval: Not required*

## REFERENCES

1. Asuquo M, Nwagbara V, Agbor C, Ootobo F, Omotoso A. Giant simple hepatic cyst: a case report and review of relevant literature. African Health Sci. 2015;15(1):293-8.
2. Martin IJ, McKinley AJ, Currie EJ, Holmes P, Garden OJ. Tailoring the management of nonparasitic liver cysts. Ann Surg. 1998;228(2):167.
3. Tocchi A, Mazzoni G, Costa G, Cassini D, Bettelli E, Agostini N, et al. Symptomatic nonparasitic hepatic cysts: options for and results of surgical management. Arch Surg. 2002;137(2):154-8.
4. Nardello O, Muggianu M, Cabras V, Farina GP, Cagetti M. Dysplastic cysts of the liver: our experience. Minerva Chirurgica. 2004;59(4):351-62.
5. Tucker ON, Smith J, Fenlon HM, McEntee GP. Giant solitary non-parasitic cyst of the liver. Irish J Med Sci. 2005;174(2):60.
6. Regev A, Reddy KR, Berho M, Sleeman D, Levi JU, Livingstone AS, et al. Large cystic lesions of the liver in adults: a 15-year experience in a tertiary center. J Am Coll Surg. 2001;193(1):36-45.
7. Stănescu CA, Păduraru DN, Cîrîmbei C, Brătuțu E. The laparoscopic management of simple hepatic cysts. J Medicine Life. 2015;8(3):342.
8. Tan YM, Chung A, Mack P, Chow P, Khin LW, Ooi LL. Role of fenestration and resection for symptomatic solitary liver cysts. ANZ J Surg. 2005;75(7):577-80.
9. Burch JC, Jones HE. Large nonparasitic cyst of the liver simulating an ovarian cyst. Am J Obstet Gynecol. 1952 Jan 1;63(2):441-4.
10. Tocchi A, Mazzoni G, Costa G, Cassini D, Bettelli E, Agostini N, et al. Symptomatic nonparasitic hepatic cysts: options for and results of surgical management. Arch Surg. 2002;137(2):154-8.

**Cite this article as:** Muthammal R, Natarajan A, Raj M, Radhakrishnan R. A retrospective study of colorectal carcinoma in Central India. Int Surg J 2019;6:627-9.