

Original Research Article

Effectiveness of ultrasound guided fine needle aspiration cytology of axillary node in women with clinically node negative breast cancer

T. Mohamed Rizwan, Moothedathparambil Ramakrishnan Babu*, Krishnakumar Marar

Department of General Surgery, Amala Institute of Medical Sciences, Amala Nagar, Thrissur, Kerala, India

Received: 29 October 2018

Accepted: 30 November 2018

***Correspondence:**

Dr. Moothedathparambil Ramakrishnan Babu,

E-mail: mrbabuaqu@gmail.com

Copyright: © the author(s), publisher and licensee Medip Academy. This is an open-access article distributed under the terms of the Creative Commons Attribution Non-Commercial License, which permits unrestricted non-commercial use, distribution, and reproduction in any medium, provided the original work is properly cited.

ABSTRACT

Background: The preoperative ultrasound (USG) guided fine needle aspiration cytology (FNAC) of axillary metastasis may avoid unnecessary axillary dissections and time consuming and costly sentinel lymph node biopsy. This study was aimed to evaluate the accuracy of USG guided FNAC in preoperative assessment of clinically node negative breast cancer patients.

Methods: An observational study was done in patients who fall within the inclusion criteria. USG guided FNAC of suspicious nodes was done. All the selected patients were taken up for modified radical mastectomy. The resected specimens were sent for detailed histopathological (HPR) evaluation, which was taken as the gold standard for the comparison with the pre-operative FNAC report.

Results: Among a total of 33 patients with early breast cancer subjected to USG guided FNAC and compared with the HPR results. The sensitivity, specificity, positive predictive value and negative predictive value of FNAC were 44.44%, 100%, 100% and 28.57% respectively.

Conclusions: The sensitivity of USG guided FNAC of suspicious axillary lymph nodes was low, whereas the specificity and positive predictive values were high. Moreover, the negative predictive value is very less. Hence, the results suggested that USG guided FNAC has not proved to be sufficiently accurate for routine preoperative assessment in patients with early breast cancer.

Keywords: Axillary metastasis, Breast cancer, FNAC, Radical mastectomy, Sentinel lymph node

INTRODUCTION

Breast cancer is one of the major public health problems in the world. It ranks second among the leading cause of cancer related death worldwide. The overall incidence of breast cancer showed an increasing trend until 1999, after which survival rates improved and incidence showed decreased rates. In developing countries, still the incidence remains high due to late detection and late seeking of treatment measures. In India, according to ICMR about 12-13% increase has been noted over the past 20 years. In Kerala, breast cancer accounts for 28.9% of all cancers incidence in women.¹

Triple assessment of patient with suspected cancer of breast remains the most integral part in the detection and treatment care. Despite the technological advancements clinical examination of breast and axilla holds the maximum relevance even today. Many prognostic factors have been described in carcinoma of breast, including tumor size, lymph node status, grading, lymphovascular invasion, etc. Yet, axillary lymph node status remains as the single most important factor. Sentinel lymph node biopsy has replaced axillary lymph node dissection as the primary staging procedure in many centres because sentinel lymph node biopsy is associated with less morbidity.² Ultrasound (USG)-guided fine needle

aspiration cytology (FNAC) is a quick non-morbid method of staging disease in the axilla. Percutaneous evaluation of axilla is still not routinely used in many centres despite of growing body of evidence that it is very valuable in planning the appropriate management of patients and can spare surgical procedure in some patients.³⁻¹⁰ A multidisciplinary effort is thus needed to design a less invasive approach to accurately stage the disease and reduce unnecessary axillary dissections in breast carcinoma patients. Sentinel lymph node scintigraphy and biopsy is a definitive procedure that can be carried out to decide whether axillary dissection is to be carried out or not, but it has its own disadvantages, mainly the involvement of high costs, high setup and time-consuming. USG-guided axillary lymph node FNAC can be utilized as a substitute for sentinel lymph node scintigraphy and biopsy.

However, studies are fragmentary and, thus, needed further studies. This study was aimed to evaluate the accuracy of USG guided FNAC in preoperative assessment of clinically node negative breast cancer patients.

METHODS

An observational study was conducted among the patients who attended the General Surgery department and Surgical Oncology department during the period between January 2016-June 2017. Previously untreated, histologically proven invasive breast cancer with clinical stage of T1, T2, T3, N0 and M0 cases coming under the age group of 18-65 years with clinically node negative were included in the study. Prior treatment for breast cancer and patients unfit to undergo general anesthesia were excluded from the study. The calculated sample size for the standard error of 5% was 16. The actual sample size had been increased to 33 in order to increase the accuracy of the study.

Study procedure

Detailed clinical history and demographical data were collected using a questionnaire. After getting an informed consent, a detailed clinical examination of the breast and axilla was done. Ultrasound guided fine needle aspiration cytology was done in those patients who fall within the inclusion criteria by an experienced radiologist. The patient was placed supine/contralateral side-down oblique position on the table, with the ipsilateral hand placed behind the head. Metastatic lymph node features include rounded shape, hypoechoogenicity, cortical thickening and loss of central fatty hilum. The lymph nodes are considered significant if any three of the above four characteristics were met. All necessary preoperative investigations were done and the patients were taken up for modified radical mastectomy. The resected specimens were sent for detailed histopathological evaluation, which was taken as the gold standard for comparison with the pre-operative FNAC report.

Statistical analysis

The sensitivity, specificity, positive predictive value and negative predictive value of USG guided FNAC in staging axilla in women with early breast cancer were estimated. Analysis was done using Chi square test and Fisher exact test. The software used for analysis was SPSS, version 23.

RESULTS

Total 33 patients with early breast cancer and clinically node negative was subjected to USG guided FNAC. The prevalent age group is depicted in Figure 1. The maximum number of cases was seen in 41-60 age group (51.5%) while the 61-80 age group showed only 15.2 % incidence (Figure 1).

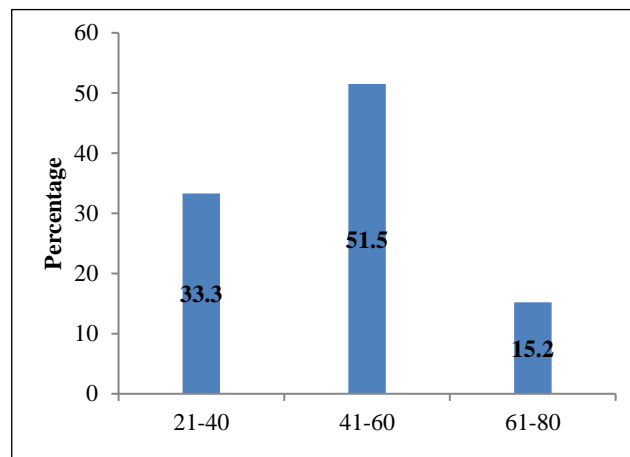


Figure 1: Age wise distribution of cases.

Clinical examination of breast is about 54% sensitive and 94% specific and is the most important component of triple assessment. Most common presenting complaint was breast lump (78.8%) while 5 cases (15.2%) were asymptomatic. Heaviness was detected in only 2 cases. The site of presentation was not showed any significant change. The left side 51.5% cases the presentation was right side and remaining was left side. The demographic data revealed that most of the patients had their first child birth during 18-20 years of age and the upper outer quadrant 75.2% was the major site involved. Number of pregnancies was 2 in most of the cases (48.5%). Incidence rate in the lower outer quadrant was 24.2%. Age at menarche was 12 years in 27.3% of the cases. Only 2 were 15 years of age. Age at menarche was 49-52 in 6.1% of cases while majorities of the cases, the age was less than 45 years. No family history of breast cancer was found in 81.8% of the cases and in 90.9% cases, no family history of ovarian cancer found. Preoperative staging showed 12 cases in the T2N0M0 staging and 5 cases were T2N1M0 stage (Table 1). The post-operative pathological staging showed 14 cases were in the T1N1M0 stage whilst only 2 cases were in the T1N0M0 (Table 1).

Table 1: Comparison of pre-and post-operative TNM staging.

Pre-operative TNM staging	Pathological TNM staging				Total
	T1N0M0	T1N1M0	T2N0M0	T2N1M0	
T1N0M0	2	7	0	0	9
T1N1M0	0	7	0	0	7
T2N0M0	0	0	4	8	12
T2N1M0	0	0	0	5	5
Total	2	14	4	13	33

Fisher's exact p value = 0.00001

Table 2: Comparison of pre-and post-operative node status.

FNAC node status	HPR node status		Total
	+ve	-ve	
+ve	12	0	12
-ve	15	6	21
Total	27	6	33

A comparison of preoperative and post-operative composite staging has been depicted in Table 2. Preoperative composite staging showed 19 cases (57.6%) were in stage IIA and IIB whereas it was 18 in the postoperative analysis. The comparison of the node status in FNAC with that of HPR showed the sensitivity, specificity, positive predictive value and negative predictive value of FNAC were 44.44%, 100%, 100% and 28.57% respectively.

DISCUSSION

The single most important prognostic factor in carcinoma breast is metastatic involvement of axillary lymph nodes. Positive axillary involvement determines staging of the disease and the patient's survival and hence plays an important role in local control. In some situations, axilla may be negative clinically but may be positive on pathological examination. USG of the axilla has an important place in the preoperative workup. If USG detects axillary metastasis, axillary lymph node dissection can be performed directly by avoiding sentinel lymph node biopsy, which requires high setup, operating costs and complex techniques, thereby limiting its widespread application. Ciatto et al, reported the sensitivity of node FNAC between 67% and 78%, while the specificity was between 92% and 99%.¹¹ In this study, FNAC sensitivity was lower at 64.6%. FNAC sensitivity was highest in cases with sonologically abnormal and clinically negative nodes (50%). Specificity was high in both the groups, 81.2% and 97.2% respectively. The false negative rate was 15.3%, the false positive rate was 1.4%, and the inadequacy rate was 10.8%. The likelihood of node FNAC being positive was significantly associated with tumor grade and stage, and the number of nodes involved with metastasis. Alkuwari et al, reported the sensitivity of 65% and specificity of 100% in detecting

axillary lymph node metastasis in early breast cancer.¹² PPV was 100% and NPV was 60%. Leenders et al, reported the sensitivity, specificity, PPV and NPV of axillary ultrasound alone to be 43.8%, 81%, 57% and 71%.¹³ When combining axillary ultrasound with FNAC of suspicious lymph nodes, sensitivity was 28%, specificity was 99.9%, PPV was 99.1% and NPV was 69%.

In this study, node positive axillae were identified by USG guided FNAC and spared unnecessary sentinel node biopsy. Unfortunately, the percentage of false negative results of USG guided FNAC was very high (28%). Pessoa et al, reported that there is no statistically significant correlation between clinical examination and pathologically positive axillae.¹⁴ However, in axillae considered suspicious by USG, the risk of positive anatomopathological findings increased 12-fold. Receiver Operating Characteristics (ROC) analysis demonstrated that a cortical thickness of 2.75mm corresponded to the highest sensitivity and specificity in predicting axillary metastasis (82.7% and 82.2%, respectively). Park et al, reported in retrospective analysis of 382 breast cancer patients with clinically negative axillary lymph node that 121 patients with suspicious findings on axillary ultrasound were subjected to axillary lymph node FNAC under USG guidance.¹⁵ The sensitivity of axillary USG alone was 56.6%, specificity was 81%, positive predictive value was 60.3% and negative predictive value was 78.5%. Addition of USG-guided FNAC resulted in sensitivity, specificity, positive predictive value and negative predictive value of 39.5%, 95.7%, 82.3% and 75.6%, respectively. The study concluded that combination of axillary USG and USG-guided FNAC is useful in preoperative work up of breast cancer patients and in deciding whether or not to perform axillary dissection. In another study conducted by Park et al.¹⁶ found that rate of false negative results was 42.4% in both USG and USG-guided FNAC of axillary lymph node but among them, 57.6% showed only one metastatic axillary lymph node. Breast cancers with false negative axillary lymph node on USG and USG-guided FNAC was significantly related to positive oestrogen receptor ($p = 0.003$), positive progesterone receptor ($p = 0.001$), and the presence of lymphovascular invasion ($p = 0.004$). Also, high T-stages showed significant correlation with false negative axillary lymph nodes on USG and USG-

guided FNAC. Krishnamurthy et al, reported the role of USG-guided FNA of indeterminate and suspicious axillary lymph nodes in the initial staging of breast carcinoma.¹⁷ They reported a sensitivity of 76.7%, specificity of 100%, positive predictive value of 100% and negative predictive value of 53.3%. Rocha et al, reported the sensitivity of USG-guided FNAC of suspicious lymph nodes was 87.1%.¹⁹ No false positive result was identified from USG-guided FNAC, characterizing 100% specificity and positive predictive value. On the other hand, USG guided FNAC produced 14 false negative results, determining a negative predictive value of 69.5%. They found out that axillary USG alone had a sensitivity of 53.1% and the negative predictive value was 73.9%. They also added that the utilization of USG guided FNAC to avoid sentinel lymph node biopsy in 54% of patients. In this study, we have found that there is a strong positive correlation for the detection of lymph nodes between USG guided FNAC and histopathology. The sensitivity was found to be 44.44% and specificity of 100% was obtained. PPV was 100% and NPV was found to be 28.57%. The results are consistent to the previous studies.

CONCLUSION

USG guided FNAC is moderately sensitive and highly specific in diagnosing axillary nodal metastasis. It has a high positive predictive value and a low negative predictive value and hence negative FNAC node status results cannot definitely exclude axillary nodal metastasis.

ACKNOWLEDGEMENTS

The authors acknowledge the valuable help of Dr. Ajith TA, Professor, Department of Biochemistry, Amala Institute of Medical Sciences, Thrissur, Kerala, India during the preparation of this manuscript.

Funding: No funding sources

Conflict of interest: None declared

Ethical approval: The study was approved by the Institutional Ethics Committee

REFERENCES

1. Annual ICMR. Indian Council of Medical Research; 2004-2005. Available at: www.icmr.nic.in.
2. Cox CE, Salud CJ, Cantor A, Bass SS, Peltz ES, Ebert MD, et al. Learning curves for breast cancer sentinel lymph Node mapping based on surgical volume analysis. *J Am Coll Surg.* 2001;193:593-600
3. de Kanter AY, van Eijck CH, van Geel AN, Kruijt RH, Henzen SC, Paul MA, et al. Multicentre study of ultrasonographically guided axillary node biopsy in patients with breast cancer. *Br J Surg.* 1999;86:1459-62.
4. Krishnamurthy S, Sneige N, Bedi DG, Edieken BS, Fornage BD, Kuerer HM, et al. Role of ultrasound-guided fine-needle aspiration of indeterminate and suspicious axillary lymph nodes in the initial staging of breast carcinoma. *Cancer.* 2002;95:982-8.
5. Kuenen-Boumeester V, Menke-Pluymers M, de Kanter AY, Obdeijn IM, Urich D, Van Der Kwast TH. Ultrasound-guided fine needle aspiration cytology of axillary lymph nodes in breast cancer patients: a preoperative staging procedure. *Eur J Cancer* 2003;39:170-4.
6. Deurloo EE, Tanis PJ, Gilhuijs KG, Muller SH, Kröger R, Peterse JL, et al. Reduction in the number of sentinel lymph node procedures by preoperative ultra-sonography of the axilla in breast cancer. *Eur J Cancer.* 2003;39:1068-73.
7. van Rijk MC, Deurloo EE, Nieweg OE, Gilhuijs KG, Peterse JL, Rutgers EJ, et al. Ultrasonography and fine-needle aspiration cytology can spare breast cancer patients unnecessary sentinel lymph node biopsy. *Ann Surg Oncol.* 2006;13:31-5.
8. Sapino A, Cassoni P, Zanon E, Fraire F, Croce S, Coluccia C, et al. Ultrasonographically-guided fine-needle aspiration of axillary lymph nodes: role in breast cancer management. *Br J Cancer.* 2003;88:702-6.
9. Koelliker SL, Chung MA, Mainiero MB, Steinhoff MM, Cady B. Axillary lymph nodes: US guided fine-needle aspiration for initial staging of breast cancer-correlation with primary tumor size. *Radiol.* 2008;246:81-9.
10. Oruwari JU, Chung MA, Koelliker S, Steinhoff MM, Cady B. Axillary staging using ultrasound-guided fine needle aspiration biopsy in locally advanced breast cancer. *Am J Surg.* 2002;184:307-9
11. Ciatto S, Brancato B, Risso G, Ambrogetti D, Bulgaresi P, Maddau C, et al. Accuracy of fine needle aspiration cytology (FNAC) of axillary lymph nodes as a triage test in breast cancer staging. *Breast Cancer Res Treat.* 2007 May 1;103(1):85-91.
12. Alkuwari E, Auger M. Accuracy of fine needle aspiration cytology of axillary lymph node in breast cancer patients: a study of 115 cases with cytologic-histologic correlation. *Cancer.* 2008;114:89-93.
13. Leenders MW, Broeders M, Croese C, Richir MC, Go HL, Langenhorst BL, et al. Ultrasound and fine needle aspiration cytology of axillary lymph nodes in breast cancer. To do or not do? *Breast.* 2012;21:578-83.
14. Pessoa EC, Rodrigues JR, Pessoa CP, Véspoli HM, Uemura G. Axillary lymph node aspiration guided by ultrasound is effective as a method of predicting lymph node involvement in patients with breast cancer. *Rev Bras Ginecol Obstet.* 2014;36:118-23.
15. Park SH, Kim MJ, Park BW, Moon HJ, Kwak JY, Kim EK, et al. Impact of preoperative ultrasonography and fine needle aspiration of axillary lymph nodes on surgical management of primary breast cancer. *Ann Surg Oncol.* 2011;18:738-44.

16. Park SH, Kim EK, Park BW, Kim SI, Moon HJ, Kim MJ. False negative results in axillary lymph nodes by ultrasonography and ultrasonography guided fine needle aspiration in patients with invasive ductal carcinoma. *Ultraschall Med.* 2013;34:559-67.
17. Krishnamurthy S, Sneige N, Edieken BS, Fornage BD, Kuerer HM, et al. Role of ultrasound guided FNAC of indeterminate and suspicious axillary lymph nodes in the initial staging of breast carcinoma. *Cancer.*2002;95:982-8.
18. Oz A, Demirkazik FB, Akpınar MG, Soygur I, Baykal A, Onder SC, et al. Efficiency of ultrasound and ultrasound guided FNAC in preoperative assessment of axillary lymph node metastases in breast cancer. *Breast Cancer.* 2012;15:211-7.
19. Rocha RD, Andre Ricardo, Pinto RR, Rolim de Freitas VA. Axillary ultrasound and fine needle aspiration cytology in preoperative staging of axillary lymph nodes in patients with invasive breast cancer. *Radiol Bras.* 2015;48:345-52.

Cite this article as: Rizwan TM, Babu MR, Marar K. Effectiveness of ultrasound guided fine needle aspiration cytology of axillary node in women with clinically node negative breast cancer. *Int Surg J* 2019;6:211-5.