

## Original Research Article

# A study on comparison of conventional suturing and tissue adhesive (2-octyl cyanoacrylate) for skin closure in inguinal hernia surgeries

Shanthi Ponnandai Swaminathan, Arun Victor Jebasingh,  
Anbuselvi Annadurai, Mannar Mannan\*

Department of General Surgery, Madras Medical College, Chennai, Tamil Nadu, India

**Received:** 23 October 2018

**Revised:** 06 December 2018

**Accepted:** 10 December 2018

**\*Correspondence:**

Dr. Mannar Mannan,

E-mail: [mannarg@gmail.com](mailto:mannarg@gmail.com)

**Copyright:** © the author(s), publisher and licensee Medip Academy. This is an open-access article distributed under the terms of the Creative Commons Attribution Non-Commercial License, which permits unrestricted non-commercial use, distribution, and reproduction in any medium, provided the original work is properly cited.

### ABSTRACT

**Background:** Wound closure techniques have evolved from suture material to advanced techniques that include skin staplers, skin glue and adhesive tapes. Based on efficacy of advanced suturing techniques patient may be benefited with better cosmesis, lesser postoperative pain, less wound infection and lesser hospital stay. The aim of the study was to compare the results of adhesive glue with suture material in skin closure in hernia surgeries.

**Methods:** This study involves 100 patients undergoing open inguinal hernia surgery. In 50 of the patient's skin closure was done with conventional suturing (3-0 ETHILON) and other 50 patients with tissue glue (2-octyl cyanoacrylate). Observation regarding postoperative pain, skin closure time and scar assessment were made, and their results were compared.

**Results:** The mean time taken for skin closure in adhesive group was  $2.72 \pm 1.32$  minutes and that of suture group was  $4.88 \pm 1.533$  minutes. This difference was of great significance with p value of  $<0.001$ . The visual analogue scale shows mean value of  $5.3 \pm 0.68$  for suture group and for skin group it was  $3.68 \pm 0.62$ . This value was of great significance with p value  $<0.001$ . Postoperative pain was comparatively less in tissue glue group. Postoperative scar was analysed with Vancouver scar scale at regular intervals. The mean score for suture group was  $8.3 \pm 0.8$  and for skin glue group it was  $2.8 \pm 0.75$ . These differences of score was of great significance with p value  $<0.001$ .

**Conclusions:** Adhesive glue is superior to conventional suturing in clean elective surgeries. It is a safe and an effective method of skin closure with less postoperative pain and better cosmesis of the scar.

**Keywords:** 2-octyl-cyanoacrylate, Adhesive glue

### INTRODUCTION

A basic need for skin closure is tissue approximation. A good tissue reunion and cosmetically acceptable scar is an ideal surgeon's practice. Wound closure techniques have evolved from early developments in suturing material to advanced resources that include skin staplers, skin glue and adhesive tapes. Based on efficacy of advanced suturing techniques patient may be benefited with better cosmesis, lesser postoperative pain and less

wound infection, lesser hospital stay. Hence it is wise to study and compare adhesive glue with suture material for the better outcome.

When a surgeon sutures a clean incision, healing takes place with minimal loss of tissue and without significant bacterial infection with minimal scarring and with glue the results are better in comparison with suture material. Moreover, the usage of glues shows a reduction in operating time in comparison with the usage of sutures.<sup>1,2</sup>

Tissue adhesives offer barrier to microorganism to the site of healing and therefore have a success towards reducing wound infection. Best cosmesis is achieved with glue when compared with sutures.<sup>3,4</sup>

In skin suture group, patients needed postoperative dressing but there was minimal cost in postoperative management of wound closure with glue. Certainly, there is no risk of needle stick injury to the surgeon while using adhesive rather than suture. In case of sutured wound, multiple puncture sites are the source of infection, which is avoided in adhesive glue thereby reducing wound infection.<sup>5</sup>

While applying adhesive glue for skin closure dead space is obliterated and complete hemostasis should be achieved for better results. The cost-effectiveness of both glue and suture was found that although the cost of glue is high, total effective cost including transportation charge for follow up, loss of wages, local dressing and anti-bacterial medicaments was high with suture material.

The overall cost-effectiveness was almost equal with adhesive glue and suture material. Adhesive glue plays very vital role in wound closure technique. This study involves comparing tissue glue with conventional suturing in hernia surgeries.

## METHODS

This was a prospective comparative study included 100 patients in two groups in Institute of general surgery, Madras medical college and Rajiv Gandhi government general hospital, Chennai, India.

All patients of more than 13years of age upto 60years undergoing open inguinal hernia repair and the patients with unilateral or bilateral inguinal hernia are included.

Patients of less than 12years and 60years, patients who underwent previous hernia repair, diabetic and immune-compromised individual and patients with skin disease over operating area are excluded.

All patients with unilateral or bilateral inguinal hernia who get admitted in Rajiv Gandhi hospital and who fit the inclusion criteria will be observed and the data collected are details of participants including disease characteristics, type of intervention, outcomes were reported.

Written informed consent was taken from the patients. Group was divided into two by randomization software. Patients who get operated for inguinal hernia will be divided into two groups as group 1 and group 2.

Patients in group 1 were skin closure done with tissue glue (2-octyl cyanoacrylate). Patients in group 2 were skin closure done with intermittent non-absorbable 3-0 ethilon.

## Parameters

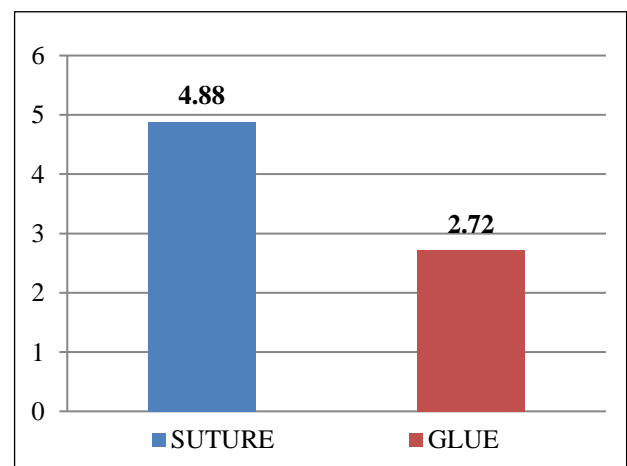
- Time taken for skin closure with suture material and skin glue,
- Postoperative scar assessed using Vancouver scar scale,
- Postoperative pain studied with visual analogue scale,
- Wound cosmesis assessed with modified Hollander scale.

The results were averaged (mean±standard deviation) for continuous data and number and percentage for dichotomous data are presented in Tables and Figures. Univariate analysis of the dichotomous variables encoded was performed by means of the chi-Square test with Yates correction if required.

Students 't' test was used to determine whether there was a statistical difference between male and female subjects in the parameters measured. P value less than 0.05 were taken to be statically significant. The data was analysed using spas package.

## RESULTS

100 Patients were enrolled in the study. 50 patients underwent closure by conventional suturing and 50 patients by adhesive tissue glue. The mean time taken for skin closure was studied in minutes. The mean time taken for adhesive glue was 4.88±1.53minutes and for skin suturing group the mean time taken was 2.72±1.32minutes. This difference in minimum time taken of skin closure for adhesive group was significant with p value <0.001.

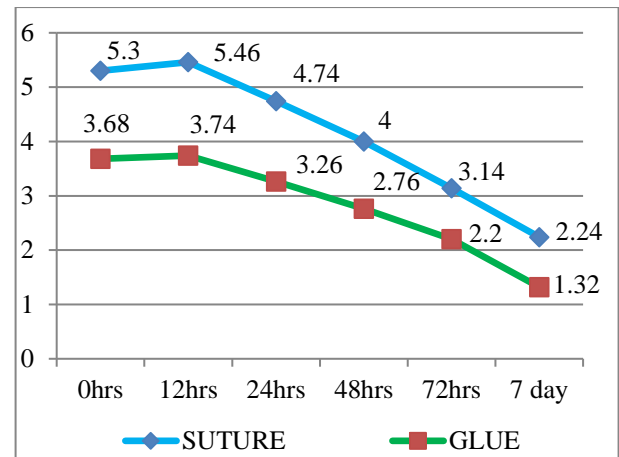


**Figure 1: Mean time taken for skin closure.**

The postoperative pain for both skin glue and skin suturing was compared at 0hrs, 12hrs, 48hrs, 72hrs and 7<sup>th</sup> post-operative day. Post-operative pain was assessed using visual analogue scale.

In the present study it was seen that postoperative pain was less with skin glue group than with suturing techniques during early postoperative hours and late postoperative hours. This difference was of great significance with p value <0.001. Postoperative scar following skin closure with adhesive glue and skin suturing was studied using vancouver scar scale. Vancouver scar scale was burn scar scale which studies five parameters such as pigmentation, pliability, scar height, color and vascularity. Score ranges from 0-13.

In the present study, it was observed that hyperpigmentation with increased scar height and band like texture was associated with skin sutured group. Adhesive glue group were associated with less pigmentation, normal skin color and pliable skin. The difference was of great significance with p value <0.01.



**Figure 2: Comparison of postoperative pain among study groups.**

**Table 1: Comparison of postoperative scar among study group using vancouver scar scale.**

Independent t-test						
	Suture	N	Mean	Std. deviation	Std. error mean	t-value
Vancouver Scar Scale	Suture	50	8.3600	0.85141	0.12041	34.152**
	Glue	50	2.8600	0.75620	0.10694	

**Table 2: Comparison of wound cosmesis score using modified hollander scale.**

	Suture	N	Mean	Std. deviation	Std. error mean	t-value
Modified hollander scale	SUTURE	50	5.7400	0.69429	0.09819	16.070**
	GLUE	50	3.1000	0.93131	0.13171	

The outcome of wound was assessed with modified Hollander scale at various intervals. This scale allows assessment of four parameters with patient and observer satisfaction score. Edge inversion, step off border, contour irregularities, margin separation and excessive distortion. In the present study, early results are in favor of adhesive glue and later follow up also shows significant difference. Adhesive glue had got good cosmetic than with skin suturing.

## DISCUSSION

Approximation of skin incision in wound closure technique is essential for a good cosmetic and functional result. The main goal of all wound closure technique is to approximate the wound edges without disturbing the natural process of healing. Traditionally, skin closure technique was performed with suture material because of cost effectiveness and availability but current trend runs towards a faster, comfortable and cosmetically better technique.

Moreover, the usage of glues shows a reduction in operating time in comparison with the usage of sutures.

Hence tissue adhesives can be considered as an alternative option to sutures, staples, adhesive strips.<sup>6</sup> Suture material remains standard material for skin closure but however use of suture material is associated with postoperative pain and one must come for suture removal which in turn causes anxiety or pain.

Since suture material is associated with puncture site near the wound edge, there is high chance of microbial invasion which in turn leads on to surgical site infection (SSI). Also, SSI are found to be less with the usage of glues compared to stapler usage.<sup>7</sup> There are suggestions that usage of glue is cosmetically equivalent to the usage of sutures.

Needle stick injury is highly associated with suture material and hence there is high chance of transmission of HIV and other diseases. Despite all shortcomings of suture material technique, it still retains the maximum tensile strength. Again, coming onto stapler device, application is faster, associated with lowest rate of tissue reaction and infection. However, these stapler devices do not produce meticulous closure and removal of staples produces pain.

Surgical tapes which is used for wound closure technique is least inducers of tissue reactivity but however it requires the use of adhesive adjuncts like tincture of benzoin which increases the local induration and skin toxicity.

An ever-ending research for a material to overcome the shortcomings of various closure techniques led to discovery of skin adhesive glue (octyl-2-cyanoacrylate). Tissue adhesive were discovered in 1949 but clinically it came into surgeon's practice in 1959. In earlier generation short carbon atoms were used which results in faster degradation and producing toxic products. Cyanoacrylate is topical adhesive glues that forms bond over outer surface of skin. It contains long chain plasticizer and forms strong flexible bond. Octyl-2-cyanoacrylate is a long carbon chain cyanoacrylate derivative that is stronger and more pliable than its shorter derivatives.<sup>8,9</sup>

There are evidence that usage of glue can elicit foreign body reaction rarely.<sup>10</sup> The Cochrane review in which eight RCTs (630 patients) on comparison of tissue adhesives and sutures were included. No statistically significant difference was found for dehiscence, infection or cosmetic appearance.

However, a statistically significant difference was found for surgeon's assessment of cosmetic appearance with mean difference 13 (95% CI 5 to 21), the higher mean rating for the tissue adhesive group.<sup>11</sup>

In 2010 this was updated in which an additional six trials resulting in a total of fourteen RCTs (1152 patients).<sup>10</sup> Trials showed that sutures were significantly better than tissue adhesives for minimizing dehiscence. On the contrary to previous studies, sutures were also found to be significantly faster to use.

There was no significant difference between sutures and tissue adhesives for in terms of infection, patient and operator satisfaction and cost. One of the trials had compared tissue adhesives with a variety of methods of wound closure and found that both patients and clinicians were significantly more satisfied with the alternative closure methods than the adhesives.<sup>12</sup> This study showed faster wound closing time, decreased postoperative pain and better wound cosmesis with tissue glue.

## CONCLUSION

From this study, it can be concluded that the use of 2-octyl cyanoacrylate has an advantage of cosmetically better scar when compared to conventional suturing. However, there are no differences in the early complications between the tissue adhesive and suturing. 2-octyl cyanoacrylate is a safe and effective method for closure of skin incisions without any short-term side effect related to the product and using 2-octyl cyanoacrylate has better short-term cosmetic appearance.

*Funding: No funding sources*

*Conflict of interest: None declared*

*Ethical approval: The study was approved by the Institutional Ethics Committee*

## REFERENCES

1. Matin SF. Prospective randomized trial of skin adhesive versus sutures for closure of 217 laparoscopic port-site incisions. *J Am Coll Surg.* 2003;196(6):845-53.
2. Quinn J, Wells G, Sutcliffe T, Jarmuske M, Maw J, Stiell I, et al. A randomized trial comparing octyl-cyanoacrylate tissue adhesive and sutures in the management of lacerations. *JAMA.* 1997;277(19):1527-30.
3. Sniezek PJ, Walling HW, Debloom III JR, Messingham MJ, Vanbeek MJ, Kreiter CD, et al. A randomized controlled trial of high-viscosity 2-octyl cyanoacrylate tissue adhesive versus sutures in repairing facial wounds following Mohs micrographic surgery. *Dermatol Surg.* 2007;33(8):966-71.
4. Zempsky WT, Parrotti D, Grem C, Nichols J. Randomized controlled comparison of cosmetic outcomes of simple facial lacerations closed with Steri Strip™ skin Closures or Dermabond™ tissue adhesive. *Pedia Emerg Care.* 2004;20(8):519-24.
5. Ando M, Tamaki T, Yoshida M, Sasaki S, Toge Y, Matsumoto T, et al. Surgical site infection in spinal surgery: a comparative study between 2-octyl-cyanoacrylate and staples for wound closure. *Euro Spine J.* 2014;23(4):854-62.
6. Beam JW. Tissue adhesives for simple traumatic lacerations. *J Athletic Training.* 2008;43(2):222-4.
7. Souza EC, Fitaroni RB, Januzelli DM, Macruz HM, Camacho JC, Souza MR. Use of 2-octyl cyanoacrylate for skin closure of sternal incisions in cardiac surgery: observations of microbial barrier effects. *Current Med Res Opinion.* 2008;24:151-5.
8. Toriumi DM, O'grady K, Desai D, Bagal A. Use of octyl-2-cyanoacrylate for skin closure in facial plastic surgery. *Plastic Reconstructive Surg.* 1998;102(6):2209-19.
9. Bernard L, Doyle J, Friedlander SF, Eichenfield LF, Gibbs NF, Cunningham BB. A prospective comparison of octyl cyanoacrylate tissue adhesive (dermabond) and suture for the closure of excisional wounds in children and adolescents. *Arch Dermatol.* 2001;137(9):1177-80.
10. Dragu A, Unglaub F, Schwarz S, Beier JP, Kneser U, Bach AD, et al. Foreign body reaction after usage of tissue adhesives for skin closure: a case report and review of the literature. *Arch Orthopaedic Trauma Surg.* 2009;129(2):167-9.
11. Coulthard P, Worthington H, Esposito M, Elst M, Waes OJ. Tissue adhesives for closure of surgical incisions. *Cochrane Database Syst Rev.* 2004;(2):CD004287.

12. Coulthard P, Esposito M, Worthington HV, van der Elst M, van Waas OJ, Darcey J. Tissue adhesives for closure of surgical incisions. *Cochrane Database Sys Rev*. 2010;(5).

**Cite this article as:** Swaminathan SP, Jebasingh AV, Annadurai A, Mannan M. A study on comparison of conventional suturing and tissue adhesive (2-octyl cyanoacrylate) for skin closure in inguinal hernia surgeries. *Int Surg J* 2019;6:188-92.