

## Case Report

# Terminal ileal stricture caused by eosinophilic gastroenteritis: a postoperative histopathological finding

Sandeep Moolchandani<sup>1\*</sup>, Arun Damodharan<sup>1</sup>, Lokesh Kumar<sup>2</sup>, Divya Prakash<sup>1</sup>

<sup>1</sup>Department of General Surgery, Kilpauk Medical College and Hospital, Chennai, Tamil Nadu, India

<sup>2</sup>Department of Pathology, Kilpauk Medical College and Hospital, Chennai, Tamil Nadu, India

**Received:** 24 May 2016

**Accepted:** 02 July 2016

### \*Correspondence:

Dr. Sandeep Moolchandani,

E-mail: [drsandeep.net@gmail.com](mailto:drsandeep.net@gmail.com)

**Copyright:** © the author(s), publisher and licensee Medip Academy. This is an open-access article distributed under the terms of the Creative Commons Attribution Non-Commercial License, which permits unrestricted non-commercial use, distribution, and reproduction in any medium, provided the original work is properly cited.

## ABSTRACT

Eosinophilic gastroenteritis is a rare disease of unknown cause characterised by eosinophilic infiltration of one or more segments of gastrointestinal tract. Stricture formation is one of the uncommon occurrences seen in the muscular and serosal type of the disease. Stricturing disease of oesophagus, pylorus and proximal small bowel has been reported earlier. We report a rare case of 48 year old male presenting with intestinal obstruction due to stricture formation in the terminal ileum. CECT of abdomen showed a segmental stricture of terminal ileum. Intraoperatively multiple dense adhesions were seen around ileocaecal junction along with a strictured segment in the terminal ileum. Initially the diseased ileal segment was resected followed by an end ileostomy with a distal mucous fistula. The histopathological examination of the resected sample revealed ulcerated and edematous ileal mucosa with dense inflammatory cells rich in eosinophils infiltrating lamina propria, muscularis propria and serosal layer. After a month of the first surgery, a right hemicolectomy with end to end ileotransverse anastomoses was done as a definitive procedure. Patient was put on oral glucocorticoid regimen. He has been asymptomatic during the follow up period of 6 months.

**Keywords:** Eosinophilic, Gastroenteritis, Terminal, Ileal, Stricture, Intestinal, Obstruction, Enteritis

## INTRODUCTION

Eosinophilic gastroenteritis (EGE) includes a spectrum of diseases characterised by eosinophilic infiltration of one or more segments of gastrointestinal tract. The standardised estimated prevalence for the US population has been calculated to be 8.4/100,000.<sup>1</sup> Earlier studies showed a higher incidence in third to fifth decade of life but eventually this disease has been found to affect age groups from infancy to the seventh decade.<sup>2</sup> It most commonly involves stomach and proximal small bowel,<sup>3</sup> but it can also involve oesophagus, distal small bowel, colon, pancreas, biliary tracts and gallbladder.

Based on the depth of eosinophilic infiltration it has been classified into mucosal, muscular and subserosal types.<sup>2</sup> Stricture formation in EGE is one of the uncommon

occurrences seen in the muscular and serosal type of disease. Stricturing disease of oesophagus, pylorus and proximal small bowel has been reported earlier. But stricture formation in the terminal ileum due to EGE is a very rare occurrence which the authors intend to report.

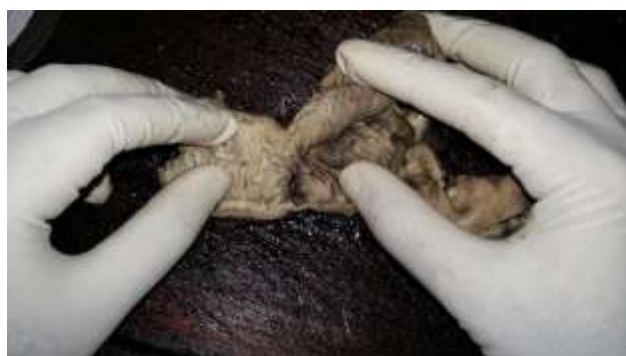## CASE PRESENTATION

A 48 years old male patient from low socioeconomic status presented with complaints of early satiety, nausea, constipation and progressive abdominal distension for past 1 month. He had multiple episodes of vomiting for 1 week which was bilious and not projectile. Patient was a known alcoholic from past 15 years with heavy consumption almost everyday over the last 5 years. He had no history suggestive of allergy, asthma or parasitic infestation. There was no history of previous abdominal

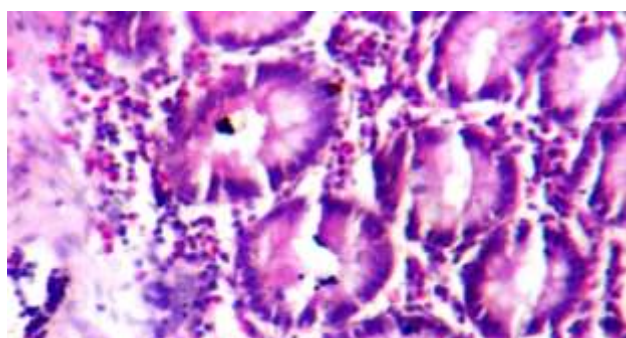
surgery. The general condition of the patient was poor with dehydration, tachycardia, anaemia and confusion. The abdomen was grossly distended with mild tenderness. However there was no guarding or rigidity.

Laboratory routine investigations showed hyponatraemia with Sodium 128 mmol/L. There was no peripheral eosinophilia. Erect X-Ray of abdomen showed multiple air fluid levels. USG abdomen showed dilated fluid filled bowel loops with peristalsis, no peritoneal free fluid was seen. CECT of abdomen showed a segmental stricture of distal ileum measuring 5.2 cm in length with proximal dilatation.

The patient was initially managed with tight fluid and electrolyte resuscitation, no oral intake, Ryle's tube decompression and antibiotics. Intraoperatively multiple dense adhesions were seen around ileocaecal junction. A strictured segment of around 6cm was seen in the terminal ileum 8 cm proximal to the ileocaecal junction. Instead of a one stage resection and anastomoses, at first stage, the ileal segment of around 20cm was resected including the diseased area followed by an end ileostomy with a distal mucous fistula. During post operative period general condition of the patient improved.



**Figure 1: Strictured segment of terminal ileum with patchy erosions.**



**Figure 2: Eosinophilic infiltrate more than 20 per high power field.**

The histopathological gross examination of the resected sample revealed strictured segments having congested mucosa with patchy erosions (Figure 1). Multiple sections from the resected mucosa showed ulcerated ileal

mucosa with lamina propria showing dense inflammatory cell infiltrate composed of lymphoid aggregates and numerous eosinophils (Figure 2). The inflammatory cells were seen extending into the muscularis propria and serosal layer also. Consequently the diagnosis of eosinophilic gastroenteritis was established.

Before the interiorisation procedure, colonoscopy and barium enema were performed and no further distal obstructive lesions were identified. After a month of the first surgery, a right hemicolectomy with end to end ileotransverse anastomoses was performed as a definitive procedure.

At discharge the patient was prescribed Prednisone 40mg for 10 days which was gradually tapered over 6 weeks. The patient has been asymptomatic from past 6 months.

## DISCUSSION

EGE is a rare disease which was first described by Kaijer in 1937.<sup>4</sup> A few hundred cases have been reported since. The diagnostic criteria were first proposed by Klein et al in 1970<sup>2</sup> and updated by Talley et al in 1990.<sup>5</sup>

The three main diagnostic criteria used are presence of GI symptoms, biopsy demonstrating eosinophilic infiltrates and no evidence of any parasitic or extra intestinal disease. The criteria for the pathological diagnosis is presence of eosinophilic infiltrate more than 20 per high power field.<sup>3</sup> The association with peripheral eosinophilia may be absent in up to 25% of patients and hence is not mandatory for diagnosis.<sup>3</sup> Table 1 summarises the three anatomical patterns of EGE based on the primary layer of bowel wall infiltrated.<sup>3</sup>

**Table 1: Anatomical patterns of EGE based on the primary layer of bowel wall infiltrated.**

| Type           | Clinical features                                      | Pathology   |
|----------------|--|---|
| <b>Mucosal</b> | Diarrhoea, haemorrhage, protein losing enteropathy     | Mucosal eosinophils with degranulation, crypt abscess, mild villous blunting      |
| <b>Mural</b>   | Abdominal pain, obstruction, nausea, vomiting          | Thickened wall, mural & subserosal eosinophils, edema. Normal mucosa              |
| <b>Serosal</b> | Abdominal pain, obstruction, ascites, nausea, vomiting | Eosinophils & edema limited to subserosa, ascitic fluid with abundant eosinophils |

There are several conditions which may present with eosinophilic gut infiltration. These are food allergies, drug idiosyncrasies, parasitic infestation, connective

tissue disorders, Crohn's disease, vasculitis, malignancy and non-topical sprue.<sup>6</sup> The conditions which can present with terminal ileal strictures and obstruction are tuberculosis, Crohn's disease, pelvic inflammatory disease, mesenteric ischemia, radiation enteritis, carcinoid infiltration, lymphoma and diffuse enteropathy.<sup>7</sup> The diseases which show both eosinophilic infiltration and possible presentation as intestinal obstruction are Crohn's disease, vasculitis and parasitic infestation.<sup>3,8</sup> Focally enhanced neutrophilic exudates & granulomas are seen in Crohn's disease but are absent in eosinophilic gastroenteritis. In case of vasculitis, inflammation tends to be centred in and around blood vessels along with visible ischemic changes. The identification of parasitic infestation relies upon eosinophilic picture with identification of organism by HPE and stool examination.

The treatment of EGE mainly relies on dietary modification and oral glucocorticoids. A surgical intervention may be required in cases of pyloric or intestinal obstruction. The surgical resection of the strictured segment may have to be performed even before pathological diagnosis has been established, as it is difficult to take biopsy if mucosa is not involved or if it cannot be sampled. However in an early presentation, a more proactive approach can be adopted by evaluating patients with persistent abdominal symptoms and peripheral eosinophilia by doing lab workup, endoscopy, and biopsies.

## CONCLUSION

EGE may present with a stricture of terminal ileum and thus may be one of the differential diagnosis amongst other aetiologies affecting this region. Though EGE presenting with acute intestinal obstruction, the diagnosis of EGE is more often a post-operative discovery rather than a carefully worked up diagnosis. A detailed work up along with mucosal biopsy in patients presenting with peripheral eosinophilia and abdominal pain can prevent

the disease progression and a surgical intervention by timely introduction of dietary modification and oral glucocorticoids.

*Funding: No funding sources*

*Conflict of interest: None declared*

*Ethical approval: Not required*

## REFERENCES

1. Jensen E, Martin C, Kappelman M, Dellon E. Prevalence of Eosinophilic Gastritis, Gastroenteritis, and Colitis. *Journal of Pediatric Gastroenterology and Nutrition*. 2016;62(1):36-42.
2. Klein NC, Hargrove RL, Sleisenger MH, Jeffries GH. Eosinophilic gastroenteritis. *Medicine (Baltimore)*. 1970;49(4):299-319.
3. Odze RD, Goldblum JR. *Surgical pathology of the GI tract, liver, biliary tract, and pancreas*. 2nd ed. Philadelphia, Pa, Saunders; 2009.
4. Kaijser R. Zur Kenntnis der allergischen affektionen des verdauungskanal vom standpunkt des chirurgen aus. *Arch Klin Chir* 1937;188:36-64.
5. Talley NJ, Shorter RG, Phillips SF, Zinsmeister AR. Eosinophilic gastroenteritis: a clinicopathological study of patients with disease of the mucosa, muscle layer, and subserosal tissues. *Gut*. 1990;31(1):54-8.
6. Daneshjoo RJ, Talley N. Eosinophilic gastroenteritis. *Curr Gastroenterol Rep*. 2002;4(5):366-72.
7. Terminal ileal stricture. *Postgraduate Medical Journal*. 2002;78(924):631.
8. DiLauro S, Crum-Cianflone NF. Ileitis: When It Is Not Crohn's Disease. *Curr Gastroenterol Rep*. 2010;12(4):249-58.

**Cite this article as:** Moolchandani S, Damodharan A, Kumar L, Prakash D. Terminal ileal stricture caused by eosinophilic gastroenteritis: a postoperative histopathological finding. *Int Surg J* 2016;3:1685-7.