

Case Report

Spigelian hernia: a rare abdominal hernia

Sajid Hussain¹, Shakil Jawed¹, Zamurrad Parveen², Md. Asjad Karim Bakhteyar^{3*}

¹Department of General Surgery, AIIMS, Patna, Bihar, India

²Department of Obstetrics and Gynecology, ³Department of General Surgery, PMCH, Patna, Bihar, India

Received: 28 September 2018

Accepted: 30 October 2018

*Correspondence:

Dr. Md. Asjad Karim Bakhteyar,
E-mail: asjadskm@gmail.com

Copyright: © the author(s), publisher and licensee Medip Academy. This is an open-access article distributed under the terms of the Creative Commons Attribution Non-Commercial License, which permits unrestricted non-commercial use, distribution, and reproduction in any medium, provided the original work is properly cited.

ABSTRACT

Spigelian hernia is a rare variety of abdominal wall hernia occurring through the spigelian fascia which is composed of the aponeurotic layer between rectus muscle medially and semilunar line laterally. Generally it is difficult to diagnose because of their location and non specific symptoms. Diagnosis is aided by ultrasonography and Computerized Tomography. Once the diagnosis is confirmed, it is repaired surgically as risk of incarceration is high. We reported this interesting case of spigelian hernia with associated port site hernia in a 53 year old female patient from Arwal district, Bihar who presented with occasional lower abdominal pain. The hernia was reduced and defect was repaired. Her recovery was uneventful.

Keywords: Arcuate line, Incarceration, Rectus muscle, Spigelian Hernia, Semilunar line

INTRODUCTION

Spigelian hernia is rare hernia occurring along the semilunar line which traverses a vertical space along the lateral rectus border from the costal margin to the pubic symphysis. Most of these hernia occur in the lower abdomen where posterior rectus sheath is deficient.

The etiology of spigelian hernia is thought to be multifactorial including both congenital and acquired factors. But many reports suggest that up to 50% of spigelian hernia occur in patients with history of prior abdominal surgery.¹

Diagnosis of spigelian hernia is difficult because of lack of specific clinical features.² Patient may present with only localized pain in the area without any clinically evident bulge. Ultrasonography and CT scan of abdomen establishes the diagnosis. Once diagnosis is confirmed, it is repaired either by open surgery or laparoscopically as soon as possible, as risk of incarceration is high.³

Here we report an interesting case of spigelian hernia with associated port site hernia, in a 53-year-old female, post-laparoscopic hysterectomy. Patient with symptom of occasional lower abdominal pain with a clinically evident lump which was spontaneously reducible

CASE REPORT

A 53 years old female patient presented to us with history of sharp abdominal pain since 3 years with a palpable lump at the right lower quadrant of the abdomen since last 3 years. On examination, there was tender, reducible swelling in the area just lateral to the rectus muscle. Abdominal muscle tone was good.

Her routine investigations were within normal range. X-ray abdomen was normal. Abdominal ultrasonography report suggested an abdominal wall defect of size 18.5 mm in the right infraumbilical region with small bowel as content. Another defect of size 15.6 mm was seen in umbilical region was also present.

After adequate preparation she was explored, under combined spinal and epidural anaesthesia by a transverse incision between umbilicus and symphysis pubis on right side and a defect was found along the lateral border of rectus sheath (Figure 1) with the external oblique aponeurosis intact over it. The defect was about 2 cm x 2 cm and was through the musculoaponeurotic sheath of the internal oblique and transverse abdominis muscle. There was herniation of small bowel, which was viable and healthy. The defect was repaired with prolene 1/0 suture, and wall was strengthened by applying polypropylene mesh (Figure 1). Port site hernia was also repaired with mesh. Drain was kept in situ. Postoperatively the patient had an uneventful recovery.

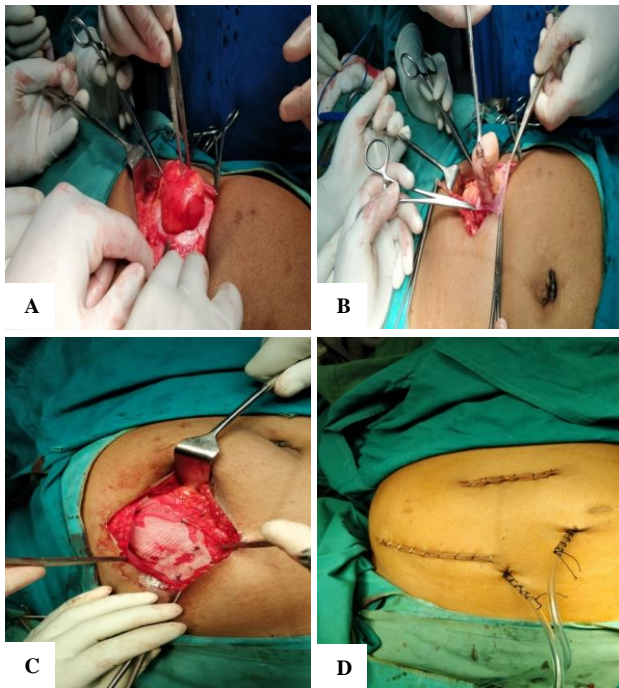


Figure 1 (A-D): Intra-operative image showing spigelian hernia with bowel as content for which mesh repair was done and abdomen closed with drain.

DISCUSSION

Spigelian hernia is named after Spighel (an anatomist from Belgium) who described semilunar line in 1645.⁴ But the hernia is thought to be first described by Klinkosch in 1764.⁵

Spigelian hernia is a rare ventral hernia which occurs secondary to a defect in the transversus abdominal muscle and rectus sheath aponeurosis which allows abdominal contents to protrude through the linea semilunaris (also known as spigelian line or belt). It is a protrusion of preperitoneal fat, a sac of peritoneum through a congenital defect or acquired weakness in the spigelian fascia.⁶ The spigelian fascia is widest where the semilunar line intersects the arcuate line of Douglas. Most of the spigelian hernia occur within this belt.⁷ The rearrangement of muscle and fascial fibers at the

intersection of the arcuate and semilunar lines is thought to cause an area of functional weakness that is predisposed to hernia formation. The hernia cannot develop medially as due to resistance for the intact rectus muscle and sheath. Therefore a large Spigelian hernia is most often found lateral and inferior to its defect in the space directly posterior to the internal oblique muscle. Spigelian hernia most often contains small intestine, but it can also contain sigmoid colon, appendix, omentum.⁸ There are high chances of intestinal obstruction and incarceration, if not diagnosed and managed early.⁹

Spigelian hernias are very uncommon and constitute only 0.12% of all the abdominal wall hernia.² Hernia appear to peak in 4th to 7th decades. The male to female ratio is 1:1.18.

20% of Spigelian hernia will present as incarcerated hernias.¹⁰ Symptoms can vary from abdominal pain to lump in the anterior abdominal wall.

Clinical diagnosis of spigelian hernia is very difficult as symptoms are non specific and variable. Pain, localized to the site is the most common symptom. USG² has been found to be the most reliable for diagnosis. Abdominal CT scan will confirm the diagnosis.

Treatment of spigelian hernia is surgical repair, as risk of incarceration is high. Suture repair with or without mesh fixation is used depending on the size of the hernia. Repair is done either open or laparoscopic.³

CONCLUSION

This case report of spigelian hernia which is a rare variety of abdominal wall hernia. Clinical diagnosis is challenging and radiological imaging may be necessary. Once diagnosed, it is repaired surgical intervention either by open or laparoscopic approach, owing to the high risk of incarceration.

Funding: No funding sources

Conflict of interest: None declared

Ethical approval: Not required

REFERENCES

1. Baucom C, Nguyen QD, Hidalgo M, Slakey D. Minimally invasive spigelian hernia repair. JSLs. 2009;13(2):263-8.
2. Mittal T, Kumar V, Khullar R, Sharma A, Soni V, Bajjal M, et al. Diagnosis and management of Spigelian hernia: A review of literature and our experience. 2008;4(4):95-8.
3. Mederos R, Lamas JR, Alvarado J, Matos M, Padron I, Ramos A. Laparoscopic diagnosis and repair of Spigelian hernia: A case report and literature review. Int J Surg Case Rep. 2017;31:184-7.

4. Mhatre HP, Kanake VB, Nandu VV. Spigelian hernia: a rare case presentation. *Int Surg J.* 2015;2(4):717-20.
5. Klinkosch JT. *Programma quo divisionem herniarum, novumque herniae ventralis specium proponit.* Rotterdam: Benam;1764.
6. Yi-ChunShih. Hsien-PinSun. Spigelian hernia showing itself as a left lower abdominal mass. *Formosan J Surg.* 2014;47(2):78-81.
7. Skandalakis PN, Zoras O, Skandalakis JE, Mirilas P. Spigelian hernia: surgical anatomy, embryology, and technique of repair. *Am Surg.* 2006;72:42-8.
8. Foster D, Nagarajan S, Panait L. Richter-type Spigelian hernia: A case report and review of the literature. *Int J Surg Case Rep.* 2015;6:160-2.
9. Belekar D, Dewoolkar V, Desai A, Anam J, Parab M. A rare case of spigelian hernia presenting with intestinal obstruction. *Int J Surg.* 2008;8(2):1-3.
10. Salemis NS, Kontoravdis N, Gourgiotis S, Panagiotopoulos N, Gakis C, Dimitrakopoulos G. Colonic obstruction secondary to incarcerated Spigelian hernia in a severely obese patient. *Int J Surg Case Rep.* 2010;1(3):27-9.

Cite this article as: Hussain S, Jawed S, Parveen Z, Bakhteyar MAK. Spigelian hernia: a rare abdominal hernia. *Int Surg J* 2018;5:4078-80.