

Original Research Article

Study on esthetic appearance of reconstructed pinna in microtia

G. Gopalan¹, M. K. Rajendran^{1*}, R. Shankar²

¹Department of Plastic Surgery, Govt. Mohan Kumaramangalam Medical College, Salem, Tamil Nadu, India

²Department of Preventive Medicine, VMKVMCH, Salem, Tamil Nadu, India

Received: 28 September 2018

Accepted: 30 October 2018

*Correspondence:

Dr. M. K. Rajendran,

E-mail: drmkrajendran@yahoo.com

Copyright: © the author(s), publisher and licensee Medip Academy. This is an open-access article distributed under the terms of the Creative Commons Attribution Non-Commercial License, which permits unrestricted non-commercial use, distribution, and reproduction in any medium, provided the original work is properly cited.

ABSTRACT

Background: The normal external ear is a complex three-dimensional structure and, as such, reconstruction of the ear is a demanding undertaking. A new era in ear reconstruction began in 1959 when Tanzer introduced his multistage autologous rib cartilage technique and it gained wide acceptance from the surgeons. The aim of the present study was reconstruction of pinna in microtia cases using esthetic component and to study its surgical outcome.

Methods: A prospective longitudinal study was conducted in the department of plastic, reconstructive and facio-maxillary surgery, Government Mohan Kumaramangalam Medical College, Salem, for a period of 2 years. A total of 26 patients with microtia were included in our study. The reconstruction of microtia was done by the following steps; a. first stage – removal of the rib cartilage and framework implantation; b. second stage - rotation of the ear lobule by Z plasty incision; c. third stage– creation of cephaloauricular sulcus; d. fourth stage - tragus construction and concha excavation. All the socio-demographic details and the clinical parameters related to the reconstructed ear were measured and tabulated.

Results: The mean age of the study subjects was 14.3 years with a male: female ratio of 2:1. Based on the Tanzer classification all the patients were either in grade IIA or grade III of microtia with 35% of the patients had the hearing loss exceeding 40db. The mean length, breadth, degree of protrusion and degree of inclination of the reconstructed ear were 58.5mm, 34.6mm, 25° and 13° respectively. The most common complication reported in present study subjects was malposition of the reconstructed pinna (21.7%) followed by hematoma infection (8.6%) and hidden helix. Post-operatively the mean hearing loss was only 25db.

Conclusions: The esthetic results of each of these techniques can be excellent when performed by an experienced surgeon in appropriately selected patients.

Keywords: Costal cartilage, Microtia, Reconstruction

INTRODUCTION

Microtia means a small, abnormal shaped or absent external ear. Studies had shown that the incidence of microtia is one in every 6,000-12,000 births and quoted as the most common congenital anomaly of the external ear.¹ The affected ear usually has conductive hearing loss (about 40-60dB) secondary to lack of an external auditory canal and to ossicular fixation.² Genetic studies have revealed several possible etiologic factors chromosomal

aberrations, multifactorial inheritance and autosomal and recessive traits. The most common syndromes associated with microtia are Goldenhar syndrome, hemifacial microsomia and Treacher-Collins syndrome.

Microtia is classified into grade I: all anatomic subunits present but misshapen, grade II: anatomic subunits either deficient or absent and grade III: classic “peanut ear” and anotia.³ Another classification into lobule-type and concha type is also useful. The lobule type is common among microtic auricular disorders. It is characterized by

the presence of a sausage shaped skin remnant of the ear and ear lobule without a concha, acoustic meatus and tragus. The other type of microtia is the concha type which is characterized by ear remnant with a lobule, concha, acoustic meatus, tragus and incisura intertragica. It is thought to be milder than the lobule type.⁴

The normal external ear is a complex three-dimensional structure and, as such, reconstruction of the ear is a demanding undertaking. A new era in ear reconstruction began in 1959 when Tanzer introduced his multistage autologous rib cartilage technique. Since then, modifications have been made to the original technique of Tanzer, mainly by Brent and then Nagata, to improve esthetic results and decrease complication rates.^{5,6} The autologous rib cartilage graft has gained wide acceptance by surgeons; however, some other methods have been devised for auricular reconstruction including prosthetic and implant reconstruction, among others.⁷

Nagata defined five types of microtia based on the surgical technique for each deformity. In the anotia type, the external ear is completely absent.⁷ Lobule type includes a variably shaped remnant cartilaginous anlage and a vertically oriented lobule, with no acoustic meatus, concha or tragus. Large conchal type is characterized by the presence of lobule, concha (with or without acoustic meatus), tragus, and intertragal notch but with varying degrees of deformity of the upper pole of the auricle. The small conchal type is similar to the lobule type but with a small indentation in the region of the conchal bowl. Atypical type includes all of the deformities that do not fit in the other categories.⁸

Fukuda stated, in order to achieve all the necessary features for total auricular reconstruction, a one-piece three-dimensional costal cartilage framework consisting of a base frame, a valve like tragus, incisura intertragica, antitragus, antihelix, superior crus, inferior crus and helices were fabricated.⁹ Furthermore in order to cover the fabricated frame various flaps and grafts in multiple stages were necessary before finally arriving at the end results.

Aim

Reconstruction of pinna in microtia cases using esthetic component and to study its surgical outcome.

METHODS

A prospective longitudinal study was conducted in the department of plastic, reconstructive and facio-maxillary surgery, Government Mohan Kumaramangalam Medical College, Salem for a period of 2 years. The study was started after getting the clearance from the institutional ethical committee and the informed consent was obtained from all the patients involved in the study. Patients in the age group of 6 to 30 years of either sex with microtia type IIA and IIB based on Tanzer classification were included

for the study. Patients with microtia associated with other syndromes like Treacher Collin syndrome, hemifacial microsomia were excluded from the study. A complete history and clinical examination was conducted on all patients included in the study. A total of 26 patients were included in the study satisfying our inclusion and exclusion criteria. A complete blood examination was done based on the requirement of anesthesia fitness, pure tone audiometry was done for evaluating the hearing loss and a CT scan for temporal bone of both side was also performed.

Preoperative planning and preparation

All the patients were admitted one day prior to surgery, preoperative study photographs were obtained and an X-ray film pattern is traced from the opposite normal ear. This pattern is reversed and the framework pattern is designed for the new ear. After sterilization, these patterns serve as guidelines for frame work fabrication at the time of surgery.

The location of reconstructed ear is predetermined by first noting the topographic relationship of the opposite normal ear with facial features and then duplicating its position at the proposed reconstruction site. It is noted that the ear's axis is roughly parallel to the nasal profile. Finally the distance between lateral canthus and the normal helical root is noted and recorded. The surgery was performed under GA for all the cases.

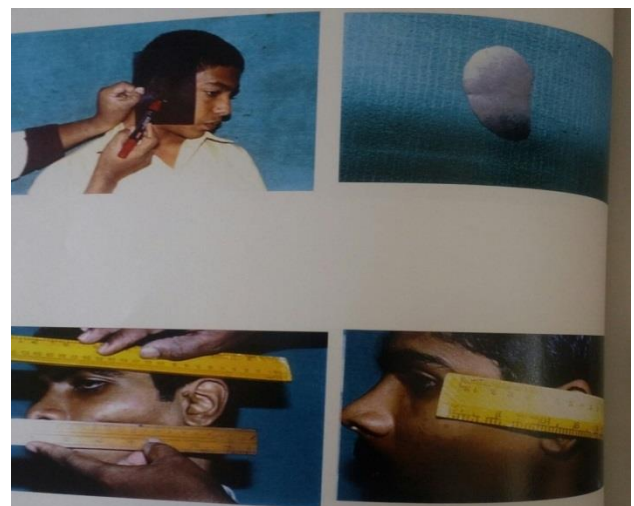


Figure 1: Preoperative planning.

First stage of reconstruction

The rib cartilage was removed through a horizontal incision which is made just above contralateral side of the costal margin. After the division of external oblique and rectus muscle, the film pattern is placed on the exposed cartilage to determine the necessary extent of rib resection. The helical rim is fashioned separately with the cartilage from 8th rib excision, with 6th and 7th rib supplying a sufficient block to carve the frame work

body. After removal of the cartilage the wound is flushed with saline and the anesthetist provided positive pressure to the lungs (Figure 3).

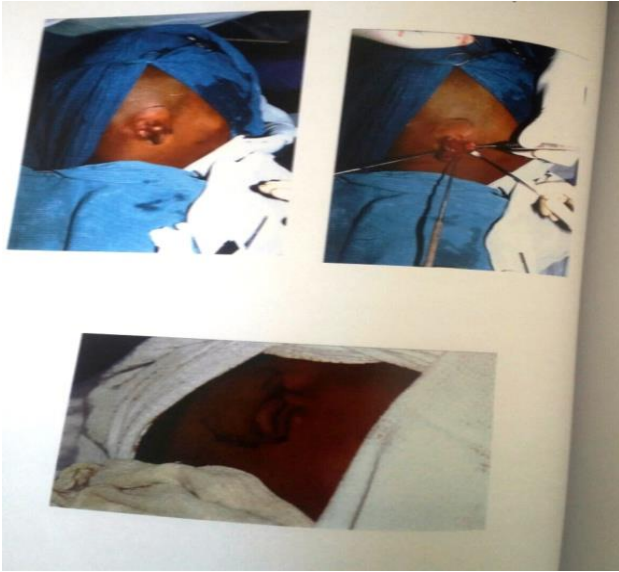

Figure 2: First stage auricle reconstruction subdermal pocket creation.



Figure 3: Framework fabrication.

Framework implantation

After the framework fabrication, the framework implantation was done through a small preauricular incision anterior to auricular vestige, a thin flap is raised by sharp dissection, care being taken to preserve the subdermal plexus. Insertion of the framework into the cutaneous pocket takes up the valuable skin slack that was created when the native cartilage remnant was removed. The dressing was applied accurately confirming the convolutions of newly created auricle (Figure 5).

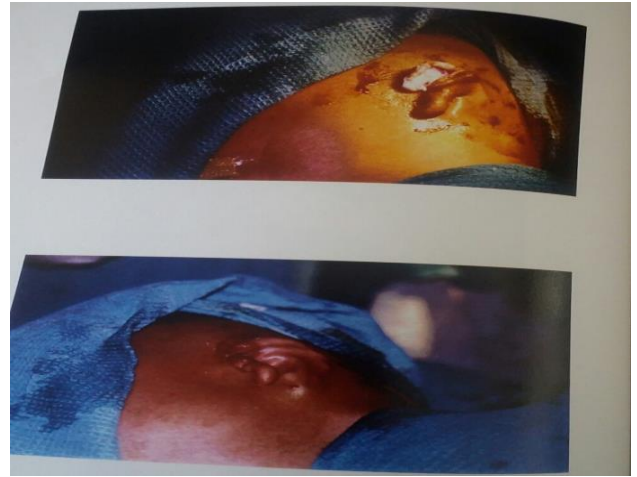

Figure 4: Implantation of the framework.

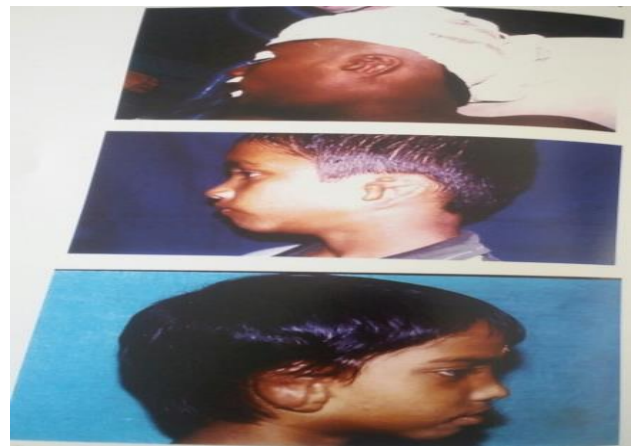

Figure 5: Cases of cartilage implantation.

Second stage

Rotation of the lobule was done two months later, Z plasty incision was made over the upper pole lobule and a narrow inferiorly based triangular flap was created to receive the lower end of the framework.

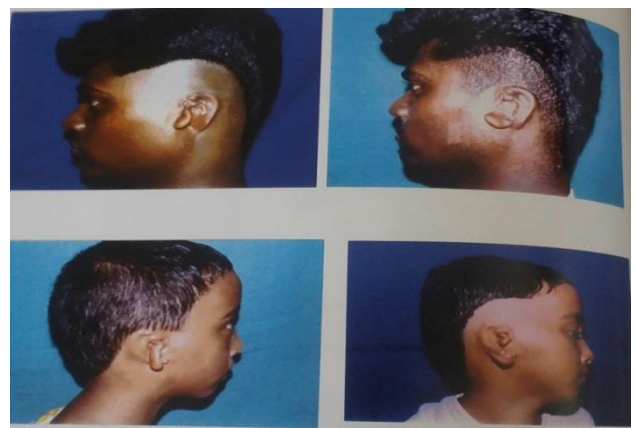

Figure 6: Second stage of auricle reconstruction.

Third stage

Creation of cephaloauricular sulcus

Three months after the initial surgery ear cartilage elevation was done. An incision was made 5mm behind the rim leaving behind adequate soft tissue over the posterior surface cartilage framework and the framework is elevated until the correct amount of projection is achieved. The retroauricular skin is advanced into the newly created sulcus and the full thickness skin graft from groin is applied over the postauricular defect. To secure the graft, the sutures are left long and tied over a gauze bolster dressing.

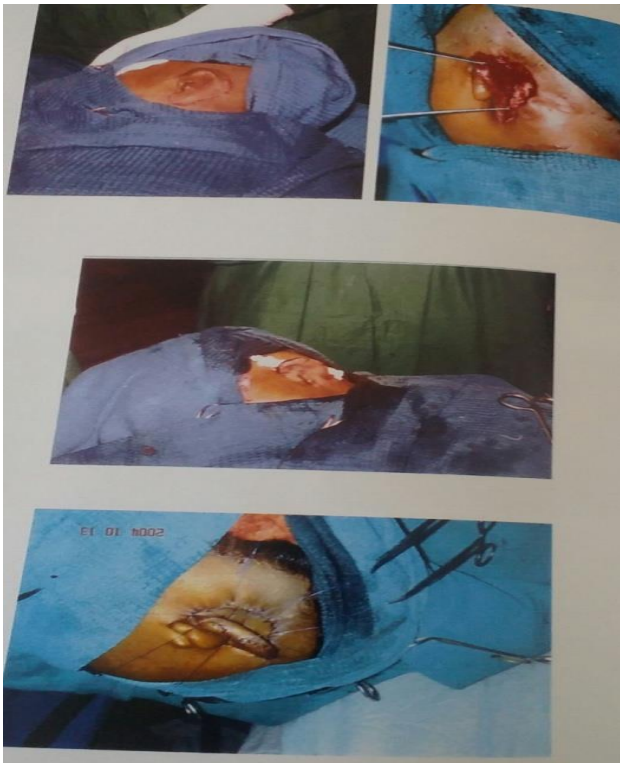

Figure 7: Third stage of auricle reconstruction - creation of cephaloauricular sulcus.

Fourth stage

Tragus construction concha excavation

The tragus is formed using a composite skin cartilage graft from contralateral conchal vault through an anterior approach. A 'J' shaped incision is fashioned along the posterior tragal margin and the composite graft is inserted and positioned so that it produces both projection of the neotragus and cavitation of the retrotragal hollow. The subcutaneous tissue is then excavated to deepen the conchal bowl. Postoperatively the patients were advised to wear postural acrylic splint for 6 months to maintain the cephaloauricular sulcus. The complete reconstruction of microtia using tissue expander was shown in Figure 9.

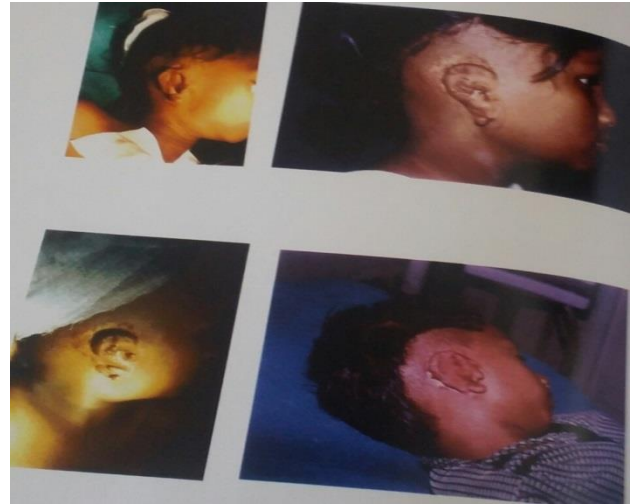

Figure 8: Fourth stage of auricle reconstruction - deepening of concha and formation of tragus.

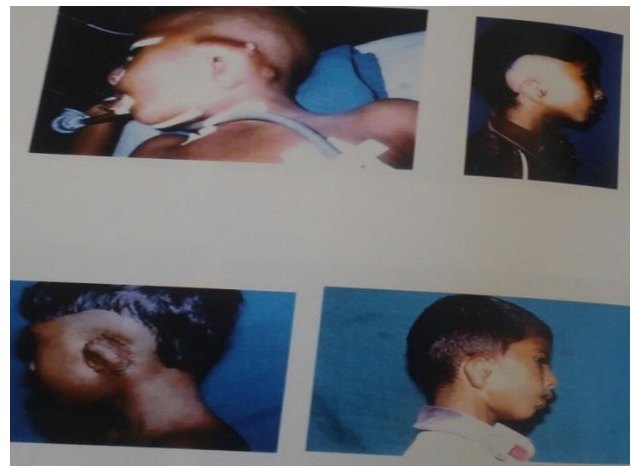

Figure 9: Reconstruction of microtia using tissue expander.

All the socio demographic details of the patients and the clinical parameters such as length, breadth, degree of protrusion and degree of inclination of the reconstructed ear were measured and the mean and SD were derived using Microsoft excel analysis.

RESULTS

Table 1 shows the age and sex wise distribution of the study subjects. Majority of the study subjects were in the age group between 11 and 20 years. The male: female ratio was found to be 2:1. Most of the subjects belong to lower middle socio-economic class.

The grading of microtia was based on Tanzer classification and based on that 65% of the patients had grade IIA and the remaining 35% had grade III microtia. Right sided ear (74%) was found to be more commonly involved than the left ear (26%) (Table 2).

Table 1: Age and gender wise distribution of the study subjects.

Age group	Gender		Total
	Male	Female	
6 - 10	6 (40%)	2 (25%)	8 (34.7%)
11 - 15	5 (33.3%)	1 (12.5%)	6 (26%)
16 - 20	1 (6.6%)	3 (37.5%)	4 (17.3%)
21 - 25	3 (20%)	2 (25%)	5 (21.7%)
Total	15 (100%)	8 (100%)	23 (100%)

Table 2: Distribution of the study subjects based on the side and grading of microtia.

Grading	Side of involvement		Total
	Right	Left	
II A	11 (64.7%)	4 (66.6%)	15 (65.2%)
III	6 (35.3%)	2 (33.3%)	8 (34.8%)
Total	17 (100%)	6 (100%)	23 (100%)

All the 23 patients had hearing loss and among them 35% of the patients had the hearing loss exceeding 40 db and for the remaining it was between 30 and 40 db. CT findings showed malformed ossicle in 56.5% of the patients and 43.5% had fused ossicle (Table 3).

Table 3: Hearing loss and CT findings among the study subjects.

Variables		Frequency	Percentage
Hearing loss	30-40db	15	65.2%
	41-70db	8	34.8%
CT scan findings	Malformed ossicle	13	56.5%
	Fused ossicle	10	43.5%

The mean and SD of the length, breadth, degree of protrusion and degree of inclination of the reconstructed ear was shown in Table 4.

Table 4: Length, breadth, degree of protrusion and degree and inclination of the reconstructed ear.

Variables	Mean	SD
Length	58.5mm	8.4
Breadth	34.6mm	3.5
Degree of protrusion	25°	3.4
Degree of inclination	13°	2.5

The most common complication reported in our study subjects was malposition of the reconstructed pinna (21.7%) followed by hematoma infection (8.6%) and hidden helix (8.6%), resorption of cartilage framework and cartilage exposure (4.3%) were other least reported complications in our study (Table 5).

Table 5: Various type of complications reported among the study subjects.

Type of complication	Frequency (n=23)	Percentage
Hematoma infection	2	8.6%
Malposition of reconstructed pinna	5	21.7%
Hidden helix	2	8.6%
Framework exposure	1	4.3%
Resorption of cartilage framework	1	4.3%

DISCUSSION

Auricular reconstruction is one of the greatest challenges in facial plastic surgery and, with the advances in both surgical techniques and biotechnology, a variety of options can be taken into consideration by surgeons and patients. Initially described by authors such as Converse, Tanzer, and Brent dealing with large numbers of patients, auricular reconstruction was later developed by Nagata and Firmin, also with large numbers of patients, and has now been reduced to an operation of two stages.¹⁰⁻¹⁴

Reviewing the literature, there have also been many other authors reporting on auricular reconstruction within the last three decades with big advances in the autologous, alloplastic but also prosthetic reconstruction. Most surgeons still favour autologous reconstruction; many have adopted the Nagata approach in many variations. These variations include the shaping of the framework, flaps to cover the framework, and the amount of cartilage that is used. He employs a temporoparietal fascial flap to cover the cartilage.¹⁵ Authors utilize a vascularised flap to cover the cartilage. The flap is thinner and we can thus save the temporoparietal fascial flap in cases of complications such as skin necrosis.

The ideal time for reconstruction of the ear is after the child is 7 years old when the physical development of the ear has already reached a certain size and it will not cause a severe distortion between the reconstructed ear and the normal one. Another important factor to obtain good surgical detail is the thickness of the costal cartilage that we use to sculpture the new framework. Before the age of seven this structure is still very fragile and thin, without adequate conditions for the creation of the new auricular framework once this is explained to the parents their anxiety will diminish, thus contributing to the success of the surgery.¹⁶

The final decision on the timing the repair should depend on the physical development and the girth of the lower chest so as to obtain an ideal costal cartilage complex. For acquiring the ideal form and size of the earlobe by reconstruction, the technique used should satisfy some factors as follows:

- Sufficient soft tissue is easily available.
- The symmetrical balance is satisfactory.
- The smooth margin and thin form are maintained.
- The technique is simple and safe.
- The color and texture can be well matched compared with surrounding tissues.

Many techniques are available for reconstruction of the ear in lobule-type microtia, each has advantages and disadvantages.¹⁷ Basically, authors' need at least two components in total auricular reconstruction: The first is a framework matching the shape and contour of the ear and second is a soft tissue cover which must be thin and adequate. The use of alloplastic frameworks was attractive at the beginning and several materials were used as silicon rubber and polyethylene.¹⁸ This technique was thought to be less invasive and reliable method of total ear reconstruction in comparison to many other techniques. But, in the last few years many authors reported high incidence of extrusion of all these alloplastic frames.^{4,19}

The other obvious limitation of these alloplastic frames is the difficulty of an accommodating the great variation in size and shape that must be produced to match the opposite normal ear. When sculpting directly from rib cartilage these limitations do not exist because the surgeon creates the required specific size and shape each time. So, we discontinued using all these alloplastic frames in favor of costal cartilage frames. Serious attempts at tissue engineering began in the early 1980s. Cartilage, being avascular with modest nutritional requirement, was an ideal medium to begin work in this arena. This quickly lead to applications in microtia repair.²⁰

CONCLUSION

The major methods of ear reconstruction include the use of autologous costal cartilage grafts, tissue expansion, implants, osseointegration and prostheses. All techniques have their associated advantages and disadvantages, which should be discussed with the patient and family before confirming a surgical plan for ear reconstruction. The experience of the surgeon is another important factor. The esthetic results of each of these techniques can be excellent when performed by an experienced surgeon in appropriately selected patients.

Funding: No funding sources

Conflict of interest: None declared

Ethical approval: The study was approved by the Institutional Ethics Committee

REFERENCES

1. Naki H. Reconstruction of microtia with a contour accentuated framework and supplemental coverage. *Plast Reconstr Surg.* 1986;78:604.

2. Brent B. The correction of microtia with autogenous rib cartilage grafts: II. Atypical and complex deformities. *Plast Reconstr Surg.* 1980;66:13
3. Brent B. Auricular repair with autogenous rib cartilage grafts: two decades of experience with 600 cases. *Plast Reconstr Surg.* 1992;90:355.
4. Chauhan DS, Guruprasad Y. Auricular Reconstruction of Congenital Microtia Using Autogenous Costal Cartilage: Report of 27 Cases. *J Maxillofac Oral Surg.* 2012;11(1):47-52.
5. Tanzer RC. Total reconstruction of the external ear. *Plast Reconstr Surg Transplant Bull.* 1959;23:1-15.
6. Brent B. Auricular repair with autogenous rib cartilage grafts: Two decades of experience with 600 cases. *Plast Reconstr Surg.* 1992;90:355-74.
7. Nagata S. A new method of total reconstruction of the auricle for microtia. *Plast Reconstr Surg.* 1993;92(2):187-201.
8. Marx H. Die Missbildungen des ohres. In: Denker AK, editor. *Handbuch der Spez Path Anatomie Histologie.* Berlin: Springer; 1926: 131.
9. Narges Baluch, Satoru Nagata, Chul Park, Gordon H Wilkes, John Reinisch, Leila Kasrai and David Fisher. *Plast Surg (Oakv).* 2014;22(1):39-43.
10. Converse JM. Construction of the auricle in unilateral congenital microtia. *Transactions Am Academy Ophthalmol Otolaryngol.* 1968;72:995-1013.
11. Tanzer RC. Total reconstruction of the auricle. The evolution of a plan of treatment. *Plastic Reconstructive Surg.* 1971;47:523-33.
12. Brent B. The correction of microtia with autogenous cartilage grafts: I. The classic deformity. *Plastic Reconstructive Surg.* 1980;66:1-12.
13. Nagata S. Modification of the stages in total reconstruction of the auricle: part III. Grafting the three-dimensional costal cartilage framework for small concha-type microtia. *Plastic Reconstructive Surg.* 1994;93(2):243-53.
14. Firmin F. Ear reconstruction in cases of typical microtia. Personal experience based on 352 microtic ear corrections. *Scandinavian J Plastic Reconstructive Surg Hand Surg.* 1998;32(1):35-47.
15. Nagata S, Brent BD. Modification of the stages in total reconstruction of the auricle: part IV. Ear elevation for the constructed auricle. *Plastic Reconstructive Surg.* 1994;93(2):254-68.
16. Brent B. The pediatrician's role in caring for patients with congenital microtia and atresia. *Pediatr Ann.* 1999;28:374.
17. Yotsuyanag T, Yamashital K, Sawada Y. Reconstruction of congenital and acquired earlobe deformity. *Clin Plast Surg.* 2000;29:249.
18. Cao Y, Vacanti JP, Paige KT. Transplantation of chondrocytes utilizing polymer-cell construct to produce tissue-engineered cartilage in the shape of human ear. *Plast Reconstr Surg.* 1997;100:297.
19. Brent B. Technical advances in ear reconstruction with autogenous rib cartilage graft. Personal

experience with 1200 cases. *Plast Reconstr Surg.* 1999;104:319.

20. Saadeh PB, Brent B, Longacre M. Human cartilage engineering: chondrocyte extraction, proliferation and characterization for construct development. *Ann Plast Surg.* 1999;42:509.

Cite this article as: Gopalan G, Rajendran MK, Shankar R. Study on esthetic appearance of reconstructed pinna in microtia. *Int Surg J* 2018;5:3940-6.