

Original Research Article

Comparative study of outcome following primary posterior sagittal ano-rectoplasty and primary anterior sagittal ano-rectoplasty for vestibular fistula

Rajendra Saoji, Nilesh G. Nagdeve*

Department of Pediatric Surgery, Government Medical College, Nagpur, Maharashtra, India

Received: 25 September 2018

Accepted: 30 October 2018

***Correspondence:**

Dr. Nilesh G. Nagdeve,

E-mail: nileshngn74@yahoo.co.in

Copyright: © the author(s), publisher and licensee Medip Academy. This is an open-access article distributed under the terms of the Creative Commons Attribution Non-Commercial License, which permits unrestricted non-commercial use, distribution, and reproduction in any medium, provided the original work is properly cited.

ABSTRACT

Background: To compare the postoperative complications and bowel function following primary PSARP and primary ASARP.

Methods: This prospective study was carried out over a period of 4 years. Patients above 4 months, who needed surgical repair for vestibular fistula were included in study. They were randomly allocated into PSARP group and ASARP group. After surgical intervention, patients of both groups were compared with respect to post-operative complications, voluntary bowel control, constipation, need for laxatives.

Results: 44 patients were enrolled in the study. Of these, 22 patients were allocated to primary PSARP group while remaining patients underwent ASARP. One patient from each group was lost to follow-up and hence, excluded from the final analysis. The two groups were comparable with respect to age, maturity at birth, weight at the time of surgery, blood investigations. Total 16 patients had associated congenital anomalies. During the postoperative period, four patients from PSARP group and two patients from ASARP group had superficial wound infection of perineal incision which was managed conservatively. One patient in PSARP group had a major breakdown of perineal wound with retraction of pulled rectum which required colostomy. There was no recurrence of fistula in any patient. No patient had stenosis of neo-anus or anterior displacement of rectum. Functional assessment of bowel function was done in 25 patients who completed 3 years of age. Voluntary bowel movements were observed in 75% of cases in the ASARP group compared to 38 % in PSARP group. 15% patients of PSARP group and 7.5% patients with ASARP had soiling. Though the difference was not statistically significant, nearly 38% of the patients after PSARP, needed laxative for normal bowel habit compared to 8% patients in ASARP group.

Conclusions: ASARP promises many advantages in the treatment of vestibular fistula in comparison to PSARP. Comparable post-operative complications, good cosmetic results, excellent continence with less need for laxatives are the advantages of ASARP.

Keywords: Anterior sagittal ano-rectoplasty, Posterior sagittal ano-rectoplasty, Voluntary bowel control

INTRODUCTION

Anorectal malformations (ARM) are among the most frequent congenital anomalies encountered in paediatric surgery, with an estimated incidence ranging between 1

in 3500 and 1 in 5000 live births. In India, various studies have quoted up to 15% prevalence of admission due to ARM.^{1,2} ARM represents a spectrum of disorders from simple low malformations like anal stenosis, perineal fistula which requires ano-rectoplasty to high complex

malformations like recto-bladder neck fistula or cloaca which requires difficult and challenging staged or multi-staged operative procedures.

Vestibular fistula is the most common type of ARM in females.³ This is a low malformation where the anal opening lies between the vagina and the fourchette (vestibule). It carries an excellent functional prognosis when managed correctly. Paradoxically, girls with these defects suffer from more complications after a failed attempt to repair. Historically, there are various operative techniques described for the treatment of vestibular fistula patients which include cutback anoplasty, perineal anal transplant, sacroperineal repair, Y-V and X-Z-plasty, limited posterior sagittal anorectoplasty (PSARP) and anterior sagittal anorectoplasty (ASARP).³⁻⁷ Limited PSARP as described by de Vries and Pena for vestibular fistula, had improved significantly functional and clinical postoperative outcome.^{6,8,9} Traditionally, the procedure is done in three stages which includes a colostomy, PSARP and colostomy closure. However, there are various studies which suggest the PSARP can be done in single stage without colostomy with equally good results.^{10,11}

ASARP with or without colostomy is being practiced as an alternative to PSARP in some centers with better cosmetic and functional outcome by reducing postoperative constipation compared to PSARP.^{12,13} The primary advantage of ASARP is that, only the anterior aspect of the sphincteric muscle complex is divided and continence mechanism is preserved.¹⁴ Though differences of opinion still exist, primary ASARP is a good and acceptable technique for RVF.^{15,16}

However, there are very few studies which compare the outcome following primary PSARP and primary ASARP.¹⁷ With this background, we designed this prospective study, to compare the postoperative complications and bowel function following primary PSARP and primary ASARP.

METHODS

A prospective comparative study of patients who needed a surgical repair for vestibular fistula was performed over 4 years at our institute (Figure 1). Approval was obtained from the Institutional Ethical Committee. Patients were subsequently enrolled only after obtaining consent from the patient's legal guardian.

Study population

All patients who presented with vestibular fistula beyond 4 months of age constituted study population. If a baby with vestibular fistula was decompressing well, presented in neonatal period, she was followed for six months. Colostomy was done in those neonates who were not decompressing and were excluded from the study. Failure to get consent from parents, neonates, babies with large fecoliths which could not be managed with washes,

patients operated outside, patients with associated pouch colon and patients with major vertebral anomaly that affect continence were excluded from the study.

Intervention

The subjects were randomly allocated into two groups: Group I were planned for limited PSARP and group II for ASARP.

Protocol

The data were collected from these patients included demographic, clinical history, physical findings, detailed investigations, operative details, and postoperative findings. All the parents/guardians were informed regarding details of surgery, complications, postoperative care, and follow-up protocol.

Operative technique

PSARP: The patients were operated in jack-knife position. The incision runs usually from the coccyx down to the fistula site. Multiple 4/0 sutures are placed in a circumferential manner in the fistula opening. The parasagittal and sphincter complex are divided keeping levator ani muscles intact. The posterior rectal wall is identified and perirectal fascia divided. The vagina meticulously separated from the rectum. The limits of the sphincter are determined with muscle stimulator and perineal body reconstructed. The rectum is then placed within the limits of the sphincter as well as the muscle complex. The rectum is anchored to the posterior edge of the muscle complex and the anoplasty is performed.

ASARP: Under general anaesthesia, the child is positioned in the lithotomy position, with elevation of the lower back to ensure good access to the perineal area. The site of the new anus was identified and marked by the presence of the anal dimple, and ascertained by muscle stimulation and marked. A vertical midline incision was carried out extending from the fistula until the center of the muscle complex. Only anterior fibers were cut, while the posterior limit was left untouched. 4/0 silk stay sutures were circumferentially applied to the vestibular fistula. The rectal wall was then dissected carefully, separating it completely from the posterior vaginal wall. Mobilization of the rectal pouch was continued until it reached the new anal site without tension. Creation of the posterior fourchette and repair of perineal body were performed from within outwards. The rectum was placed inside the center of the muscle complex, and anchored using 4/0 polygalactin sutures. The perineal skin was closed in a fashion to simulate normal perineum.

Intraoperative and post-operative management

In both groups, the patients received a single dose of intravenous cefotaxime, in a dose of 50mg/Kg. The anus

and wound were dressed with sterile gauze soaked in povidone-iodine for at least 6 hours postoperatively. The child was allowed to start oral feeding four hours postoperatively. Parents were taught how to care for the wound through regular squirting of diluted povidone iodine solution every 3-4 hour or when the baby passes the stool and local antibiotics ointments. They were prescribed oral cefixime and analgesic. Patients were kept admitted for 5 days post-surgery for wound examination and teaching parents the wound care. After discharge they were asked to review on 15th post-operative day for regular anal dilatation programme as described by Penna.⁶ They were asked to visit early if they notice any

wound infection, dehiscence, retraction of rectum or any features of systemic infection like not accepting feeds, irritability, fever, abdominal distension etc. The follow up then done after a month; every three monthly for a period of one year and 6-monthly for next two years. At initial visit, early complications like wound infection, dehiscence, rectal retraction or perianal excoriation were looked for and need for colostomy was noted. Afterword, emphasis at follow-up was given on bowel habits, continence, need for laxatives, neo-anal stenosis, anterior anal displacement. The functional assessment of bowel function was done after 3 years of age with Krickenbeck assessment system.¹⁸

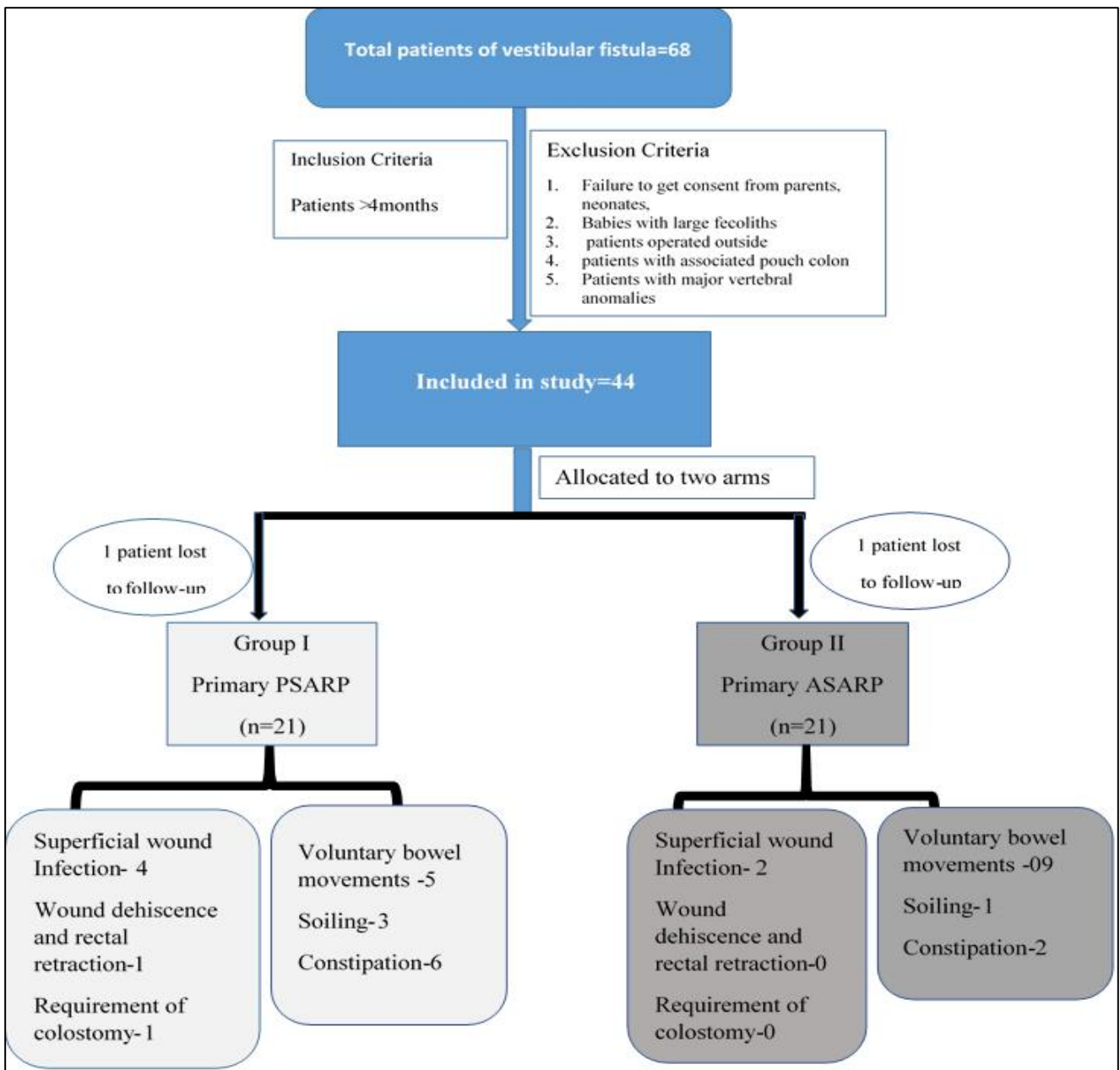


Figure 1: Study flow chart.

Statistical analysis

Continuous variables that were not normally distributed (e.g., age) were compared using the Mann–Whitney U-test, while others were compared using Student’s t-tests. Categorical variables such as complications were compared using the Chi-squared test. For small numbers, Fisher’s exact test was used. All tests were two sided and P>0.05 was considered statistically significant. Statistical analysis was performed using Stata Software version 10.0 (Stata Corp, Texas, USA).

RESULTS

Total 68 patients with vestibular fistula attended our department during study period. After applying exclusion

criteria 44 patients were enrolled in the study. Of these, 22 patients were allocated to group I and were managed by primary PSARP while remaining patients underwent ASARP and constituted group II. One patient from each group was lost to follow-up and hence, excluded from the final analysis.

The two groups were comparable with respect to age, maturity at birth, weight at the time of surgery, blood investigations (Table 1). Total 16 patients (38%) had associated congenital anomalies. Table 2 outlines the other congenital anomalies present in these patients. Atrial septal defect, ventricular septal defect and patent ductus arteriosus were the cardiac anomalies found in our study population.

Table 1: Patients characteristics.

Parameter	PSARP group	ASARP group	P-value
Age (Mean±SD)	14.35±9.73	15.93±9.04	0.7263
Age median (Range)	14.2 (4.2-35.2)	16.65 (30.3)	-
Maturity at birth (in weeks)	36.54±1.65	36.27±1.28	0.4295
Weight at the time of surgery	11.44±4.02	11.52±3.77	0.9760
Hemoglobin (gm/dl)	9.97±1.05	9.96±1.04	0.8698
Total leucocyte count	7860±1691.29	7504.02±1584.87	0.4285
Sr creatinin (mg/dl)	0.90±0.10	0.98±0.10	0.8936
Sr albumin (gm/dl)	3.89±0.5	3.82±0.51	0.7263

Table 2: Associated congenital anomalies.

Associated congenital anomalies	PSARP group	ASARP group
Cardiovascular (n=5)	ASD	1
	VSD	1
	PDA	1
Genito-urinary system (n=7)	Renal agenesis	1
	Hydronephrosis	1
	Unilateral multicystic kidney disease	0
	Primary unilateral vesicoureteric reflux	0
	MRKH syndrome	1
Neuro-skeletal anomalies (n=3)	Vertebrae deformities	1
	Radial agenesis	1
	Polydactily	0
Miscellaneous (n=1)	First arch anomalies	0

Table 3: Complications in early post-operative period.

Complications	PSARP group	ASARP group	P-value
Superficial wound infection	4	2	0.6628
Wound dehiscence and rectal retraction	1	0	1
Requirement of colostomy	1	0	1

Intra-operatively, no difficulty was encountered while separating the rectum from vagina in both PSARP and

ASARP. Post-operatively, all patients had good perineal body and neo-anal contraction. The neo-anus for all patients was calibrated to size 12 Hegar dilator. During

the postoperative period, four patients in PSARP group and two patients in ASARP group had superficial wound infection of perineal incision (not involving neo-anus) which was managed conservatively. The wound healed well in all these patients.

At 1 month follow-up, all patients (including patients with superficial wound infection) had normal looking perineal body and neo-anus with good contraction. One patient in PSARP group had a major breakdown of perineal wound with retraction of pulled rectum. This patient required colostomy. In follow up, she required re-do PSARP and colostomy closure. Table 3 describes the complications noted in post-operative period. There was no recurrence of fistula in any patient. No patient had stenosis of neo-anus or anterior displacement of rectum.

Functional assessment of bowel function was done in 25 patients (13 of PSARP group and 12 of ASARP group) who completed 3 years of age. Table 4 summaries the functional outcome after PSARP and ASARP. Voluntary bowel movements characterised by feeling of urge, capacity to verbalize and hold the bowel movement; without any soiling or the need for diet changes or laxative was observed in 75% of cases in the ASARP group compared to 38 % in PSARP group. 15% patients of PSARP group and 7.5% patients with ASARP had soiling. The patient who had re-do PSARP, had grade 2 soiling. Of the 6 patients who had constipation in PSARP group, 5 required laxatives while only one patient in ASARP group required laxatives for management of constipation. Though the difference was not statistically significant, nearly 38% of the patients after PSARP, needed laxative for normal bowel habit compared to 8% patients in ASARP group.

Table 4: Assessment of functional outcome.

Assessment of outcome		PSARP group (n=13)	ASARP group (n=12)	P-value
Voluntary bowel movements		05	09	0.48
Soiling	Grade 1 occasionally (once or twice per week)	02	01	0.593
	Grade 2 every day, no social problem	1	0	
	Grade 3 constant, social problem	0	0	
Constipation	Grade 1 manageable by changes in diet	1	1	0.2016
	Grade 2 requires laxatives	5	1	
	Grade 3 resistant to diet and laxatives	0	0	

DISCUSSION

The primary goal in the management of ARM is early repair with restoration of ano-rectal continuity with optimal sphincter function. Minimising the number of stages without affecting the results, early establishment of the defecation reflex, reduction of physical and psychological stress to the patient and family; are the other objectives. Limited PSARP is a widely practised technique for the management of vestibular fistula.

Various studies describe its benefits in these patients. ASARP, originally described for various conditions like postoperative fecal incontinence, vestibular anus, rectal prolapse, and perineal trauma was used as an alternative approach to PSARP with equally good outcome. However, very few studies directly compared the outcome following PSARP and ASARP.^{17,19}

Our study addresses this issue. It describes the postoperative results and bowel function after PSARP and ASARP in a well matched cohort.

Overall results of both procedures were comparable. Superficial wound infection was seen two times more common in PSARP group than ASARP group. The infection rate for ASARP was nearly 10% in this series, comparable with previous series.^{17,20} However, all these patients were managed conservatively with local wound management with squirting with povidone-iodine solution and antibiotic ointment application. In all patients wound healed nicely with good local outcome. At 6-month follow-up, the perineum of these patients was indistinguishable from other patients. Factors responsible for better results include better surgical technique and dissection with growing experience, less tissue trauma, adequate rectal mobilization, and absence of haemorrhage leading to hematoma. One patient in PSARP group had wound major complication i.e. wound dehiscence and rectal retraction. This patient had grade 2 soiling on follow-up. Soiling is normally attributed to children who develop complications post-surgery requiring revision surgery. The most important anatomical consideration during the repair is the long common wall between rectum and vagina. Separation of the two structures creating a plane of dissection where it does not exist, is

the critical step during surgery. No patients in both groups had neo-anal stenosis or anterior anal displacement. Thus, though statistically not significant, ASARP has marginally better results than PSARP in terms of post-operative complications in the management vestibular fistula.

Authors used the Krickbeck assessment system for functional assessment of bowel function. Bowel control implies the ability to detect and retain flatus and stool until the appropriate time for evacuation. In children with vestibular fistula, the sphincter muscles are well developed and hence the bowel control is expected to be good. Various studies describe constipation rather than faecal soiling following PSARP. Functional assessment was carried out for 25 patients. Nearly 40% of our patients after PSARP, needed laxative for normal bowel habit compared to 8% patients in ASARP group. In a series of 416 patients, Wakhlu et al found 90% normal bowel habits without the use of laxatives after ASARP.¹² Other studies also quote similar satisfactory results following ASARP.^{17,20}

In vestibular fistula, the rectal pouch has already descended through levator ani muscle and adequate mobilization of the rectal pouch can be successfully and sufficiently achieved without cutting the levator muscle. Thus, minimal dissection for mobilization of rectum without dividing the posterior part of sphincter provides a good alternative to primary PSARP. Several advantages of ASARP have been described by various authors. ASARP allows placement and anchoring of the mobilized rectum within the muscle complex; the sphincteric muscle and the perineal body are accurately reconstituted, and a normal perineum is constructed.¹² Meticulous closure of the anterior fibers in front of the anus, prevents anterior anal migration. The perineal body and posterior fourchette are closed precisely from within outwards and this resulted into proper cosmetic appearance of the perineum in all cases. Meticulously performed primary ASARP reduces tissue dissection and causes less vascular compromise, prevents stricture formation.²¹ Authors have also practised no anal dilataion following primary ASARP. ASARP minimizes the damage to posterior nervi erigentes and prevents excessive damage to puborectalis and internal and external sphincters to preserve normal rectoanal reflexes.²² Also, comfortable position of both the patient and operative surgeon with good anatomical orientation during procedure.²⁰ Although encouraging, a better conclusion on post-operative conclusion and functional bowel assessment would require bigger numbers of samples from both groups and longer follow-up.

To conclude, ASARP promises many advantages in the treatment of vestibular fistula in comparison to PSARP. Comparable post-operative complications, Good cosmetic results, excellent continence with less need for laxatives are the advantages of ASARP.

Funding: No funding sources

Conflict of interest: None declared

Ethical approval: The study was approved by the Institutional Ethics Committee

REFERENCES

1. Hashmi MA, Hashmi S. Anorectal malformations in female children– 10 years' experience. *J R Coll Surg Edinb.* 2000;45:153–8.
2. Chowdhary SK, Chalapathi G, Narasimhan KL, Samujh R, Mahajan JK, Menon P, et al. An audit of neonatal colostomy for high anorectal malformation: the developing world perspective. *Pediatr Surg Int.* 2004;20:111–3.
3. Stephens FD, Smith ED. Operative management of rectal deformities. In: *Anorectal Malformations in Children.* Chicago, IL: Year Book Medical Publishers; 1971: 212–257.
4. Chatterjee SK. Lesions in the wingspread list management in the neonatal period. In: Chatterjee SK, editor. *Anorectal Malformations: A Surgeon's Experience.* Chap 8. New Delhi, India: Oxford University Press; 1991: 48–64.
5. Smith ED. The bath water needs changing, but don't throw out the baby: an overview of anorectal anomalies. *J Pediatr Surg.* 1987;22:335–48.
6. Pena A, Devries P. Posterior sagittal anorectoplasty: important technical considerations and new applications. *J Pediatr Surg.* 1982;17:796–811.
7. Okada A, Shinkichi K, Imura K, et al. Anterior sagittal anorectoplasty for rectovestibular and anovestibular fistula. *J Pediatr Surg.* 1992;27:85–8.
8. Rintala R, Lindahl H. Is normal bowel function possible after repair of intermediate and high anorectal malformations? *J Pediatr Surg.* 1995;30:491–4.
9. Javid PJ, Barnhart DC, Hirschl RB, Coran AG, Harmon CM. Immediate and long term results of surgical management of low imperforate anus in girls. *J Pediatr Surg.* 1998;33:198–203.
10. Amanollahi O, Ketabchian S. One-stage vs. three-stage repair in anorectal malformation with rectovestibular fistula. *Afr J Paediatr Surg.* 2016;13:20–5.
11. Adeniran J. One-stage correction of imperforate anus and rectovestibular fistula in girls: Preliminary results. *JPS.* 2002;37:16-9.
12. Wakhlu A, Pandey A, Prasad A, Kureel SN, Tandon RK, Wakhlu AK. Anterior sagittal anorectoplasty for anorectal malformations and perineal trauma in the female child. *J Pediatr Surg.* 1996;31(9):1236–40.
13. Waheeb SM. The anterior sagittal anorectoplasty technique (ASARP) for treatment of recto-vestibular fistulae and vestibular anus in children and neonates. *Ann Pediatr Surg.* 2005;1:54–8.
14. Rangel SJ, de Blaauw I. Advances in pediatric colorectal surgical techniques. *Semin Pediatr Surg.* 2010;19(2):86–95.

15. Kulshrestha S, Kulshrestha M, Singh B, Sarkar B, Chandra M, Gangopadhyay AN. Anterior sagittal anorectoplasty for anovestibular fistula. *Pediatr Surg Int*. 2007;23:1191-7.
16. Kumar M, Kandpal DK, Sharma SB, Agrawal LD, Jhamariya VN. Single-stage repair of vestibular and perineal fistulae without colostomy. *J Pediatr Surg*. 2008; 43:1848-52.
17. Shehata S. Prospective long-term functional and cosmetic results of ASARP versus PASRP in treatment of intermediate anorectal malformations in girls. *Pediatr Surg Int*. 2009;25:863-8
18. Holschneider A, Hutson J. Krickenbeck consensus for the classification, grouping of surgical techniques and scoring for follow up of anorectal malformations. In editor: Holschneider A, Hutson J *Anorectal Malformations in Children*. Springer-Verlag Berlin Heidelberg; 2006.
19. Harjai MM, Sethi N, Chandra N. Anterior sagittal anorectoplasty: An alternative to posterior approach in management of congenital vestibular fistula. *Afr J Paediatr Surg*. 2013;10:78-82.
20. Aziz MA, Banu T, Prasad R, Khan AR. Primary anterior sagittal anorectoplasty for rectovestibular fistula. *Asian J Surg*. 2006;29:22-4.
21. Temple SJ, Shawyer A, Langer JC. Is daily dilatation by parents necessary after surgery for Hirschsprung disease and anorectal malformations? *J Pediatr Surg*. 2012;47:209-12.
22. Sigalet DL, Laberge JM, Adolph VR, Guttman FM. The anterior sagittal approach for high imperforate anus: a simplification of the Mollard approach. *J Pediatr Surg*. 1996;31:625-9.

Cite this article as: Saoji R, Nagdeve NG. Comparative study of outcome following primary posterior sagittal ano-rectoplasty and primary anterior sagittal ano-rectoplasty for vestibular fistula. *Int Surg J* 2018;5:3919-25.