

Case Report

Necrotising Fasciitis of lower anterior abdominal wall post lower segment caesarian section

Mahmood A. Makhdoomi^{1*}, Abdelhamid Haraga¹, Moly Joseph², Yasser Al Habeeb³

¹Department of General Surgery, ²Department of Plastic Surgery, ³Department of Clinical Pharmacy, King Khalid Hospital Hail, KSA

Received: 12 September 2018

Accepted: 08 October 2018

*Correspondence:

Dr. Mahmood A. Makhdoomi,
E-mail: drmahmoodsonu@gmail.com

Copyright: © the author(s), publisher and licensee Medip Academy. This is an open-access article distributed under the terms of the Creative Commons Attribution Non-Commercial License, which permits unrestricted non-commercial use, distribution, and reproduction in any medium, provided the original work is properly cited.

ABSTRACT

Necrotising fasciitis is a rapidly progressive inflammatory infection of the fascia with secondary necrosis of the subcutaneous tissue. The speed of spread is directly proportional to the thickness of the subcutaneous layer. It moves along the fascial plane. We are presenting a case report of 27 years old Saudi female with status post Lower segment caesarian section of 10 days' duration presented with bluish discoloration of the lower anterior abdominal wall around the surgical scar with necrotic patches and surrounding induration with foul smelling discharge from the one pocket within this area. She underwent successful simultaneous incision and wide debridement of gross necrotic tissues; together with evacuation of the pus followed by secondary closure. Both general and plastic surgical teams were involved. Patient made uneventful recovery and discharged home in good condition.

Keywords: Anterior abdominal wall, Lower segment caesarian section, Necrotizing fasciitis, Post op infection

INTRODUCTION

Necrotizing fasciitis is a progressive inflammatory infection of the fascia with secondary necrosis of the subcutaneous tissue. It moves along the fascial plane.^{1,2}

Necrotizing fasciitis may occur as a complication of a variety of surgical procedures or medical conditions, including cardiac catheterisation, vein sclerotherapy and diagnostic laparoscopy among others.³⁻¹¹ It may also be idiopathic as in scrotal or penile NF. The causative bacteria may be aerobic, anaerobic or mixed flora.¹² A few distinct NF syndrome should be recognized. The 3 most important as follows: Type 1 polymicrobial, Type 2 or group A streptococcal, Type 3 gas gangrene or clostridia myonecrosis. Historically, group A beta-hemolytic Streptococcus (GABS) has been identified as a

major cause of this infection. This monomicrobial infection is usually associated with an underlying cause, such as diabetes, atherosclerotic vascular disease, or venous insufficiency with edema. GABS usually affect the extremities; approximately two thirds of the GABS infections are located in the lower extremities.^{13,14}

Organisms spread from the subcutaneous tissue along the superficial and deep fascial planes, presumably facilitated by bacterial enzymes and toxins. This deep infection causes vascular occlusion, ischemia, and tissue necrosis. Superficial nerves are damaged, producing the characteristic localized anesthesia. Septicemia ensues with systemic toxicity.

The poor prognosis associated with necrotizing fasciitis has been linked to infection with certain streptococcal

strains. Community-acquired methicillin-resistant *S aureus* (MRSA) has also been associated with necrotizing fasciitis.¹⁵

Since 1883, more than 500 cases of necrotizing fasciitis have been reported in the literature. There may be an increased incidence in African and Asian countries; however, because of the lack of recorded cases, the true incidence is not known.

The mean age of a patient with necrotizing fasciitis is 38-44 years. This disease rarely occurs in children. Pediatric cases have been reported from resource-poor nations where poor hygiene is prevalent. The male-to-female ratio is 2-3:1.

These infections can be difficult to recognize in their early stages, but they rapidly progress. They require aggressive treatment to combat the associated high morbidity and mortality.

CASE REPORT

A 27 yrs. old Saudi female was brought to an emergency department known to have a long history of psychiatric illness, being status post lower segment caesarian section 10 days back, with bluish discoloration of lower anterior abdominal wall around the previous scar (necrosis of the wall) with a small pocket of discharging the pus laterally with surrounding induration and redness. She denied any history of fever, altered sensorium, vomiting and dyspnea. Clinically, Generally, average built female, conscious with BP:110/70mmHg, Pulse 88/min, temp 37.4 degrees, O2 saturation: 93% on room air. There was no dyspnea, stridor or cyanosis.

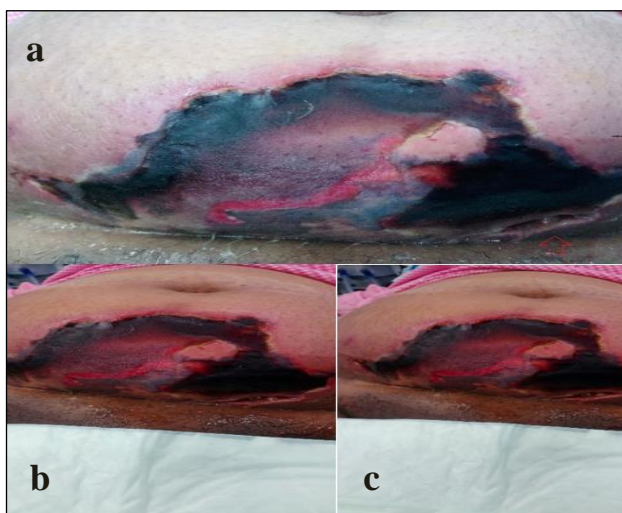


Figure 1: (a) Preoperative photo showing diffuse necrosis with a pocket (arrows); (b) view of diffuse necrosis of lower ant. abdominal wall; (c) another view of diffuse necrosis just above the Pfannenstiel incision reaching to both flanks and up to the umbilicus.

A huge part of suprapubic area above the Pfannenstiel scar reaching just below the umbilicus and both flanks, infected with necrotic tissue with pocket of pus discharge and surrounding induration. The area was very tender, tense, with hotness and redness of the covering skin that showed areas of gangrene with some sinuses discharging pus (Figure 1a).

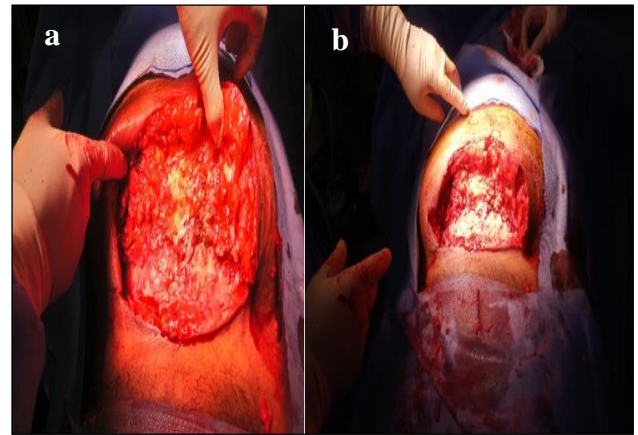


Figure 2: (a) the area of lower ant. abdominal wall after wide debridement up to the fascia; (b) view of the debrided area.

she was resuscitated with IV fluids, O₂, samples were taken for bloodwork's that showed WBC: 20,000, Hb: 9.8 gm/dl, random blood sugar was 18, creatinine 130 micromol /l and urea 8mmole/l. PT, PTT, INR were: 15 sec, 46 sec, 1.9 respectively, serum calcium: 1.9 mmol /l and albumen: 25 gm/l. An impression of neglected necrotizing fasciitis of lower anterior abdominal wall was made, and patient was prepared for contrast enhanced computerized scan (CECT) of abdomen, which showed no signs of extension of the infection to the intraabdominal cavity. Patient was seen by medical, endocrinologist, nephrologist, psychiatric, neurosurgery, anesthesia. Patient was stabilized soon in high dependency unit. The situation was discussed with her husband and she was consented for high risk under general anesthesia.

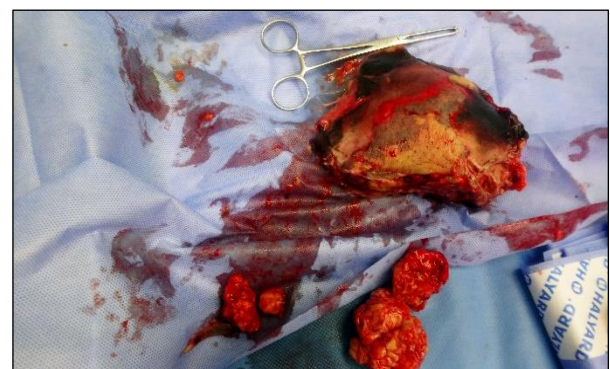

Figure 3: The part of anterior abdominal wall which was removed (wide area of necrotic tissue).

After induction our patient was placed in the supine position and the general surgery (GS) team started with excision of the necrotic skin including all sinuses, together with aggressive debridement of the necrotic tissues. 200 ml of pus was found. A wide debridement of necrotic area upto the both flanks and to lower pole of umbilicus, down to the suprapubic area was done, which left a big defect in the lower anterior abdominal wall and it was found to be extra peritoneal and no track or sinus was detected which could have connected with the intraperitoneal space. (Figure 2a,2b)

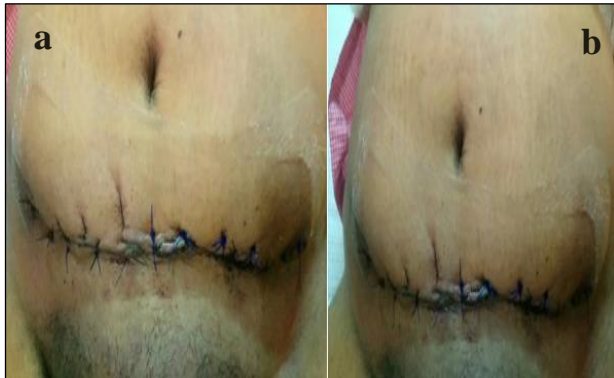

Figure 4: (a) defect closed by secondary suturing (b) closed defect by secondary suturing without using skin grafts or flap.

Post wide debridement a wide area of anterior abdominal wall was excised (figure 3). All areas were packed lightly with saline gauze. The whole area was thoroughly washed with saline. A Samples of pus and a piece of tissue were taken for culture and sensitivity. An opsite dressing was placed. Postoperatively, patient was shifted to high dependency unit under observation on IV antibiotic. He started fluid diet and gradually to DM diet. Cultures were only positive for *Staphylococcus aureus*. She was taken to theatre on the third postoperative day for secondary debridement and dressing. Regular daily dressing was done with saline and wet saline gauze packs. A vacuum-assisted closure device (VAC system) was applied on the 5th postoperative day. Plastic surgery consultation was sought out and she was seen by them with daily aggressive dressing. Plastic surgery consultation confirmed that no need for coverage with graft or local flaps

After the infection subsided completely the patient was taken to operative room for secondary closure and which was done successfully by the plastic surgery team. (Figure 4a,4b).

DISCUSSION

NF is a rapidly progressing disease causing extensive soft tissue necrosis commonly involving the limbs, perineum and anterior abdominal wall. Post-operative patients account for 20% of cases, though in many the infection follows trivial trauma.

Most of the cases of post-operative NF in obstetrics and gynecology have been reported before the era of prophylactic antibiotics.¹⁶ Only few cases have been reported after 2000, the latest reported in 2012 by DeMuro et al.¹⁷ In most of the previous studies obesity, hypertension and diabetes have been implicated as risk factors but recent case reports have highlighted the possible role of post-operative NSAID (non-steroidal anti-inflammatory drug).^{16,17}

Aggressive and multiple surgical debridement despite patient's unstable condition should be done as there is no role of wait and watch policy. Leaving the abdomen open as in this case, timely performed serial debridement followed by delayed secondary closure with good supportive treatment where the key to favorable outcome. Individualization of therapy should also be done to address specific risk factors like malnutrition and anemia. Though we could not find any specific risk factors in our patient, we are of view that surgery itself was a risk factor in our case.

NF in post-partum patients is a challenge from both diagnosis and management perspective. High clinical suspicion and aggressive management are the foundation for favorable outcome.

While skin grafts or flaps are the recommended techniques for coverage of large carbuncle defects not amenable to direct surgical closure.^{5,6} The results of continued daily dressings and good sugar control may be quite surprising as evidenced by the remarkable wound healing that occurred in this case - an option of management that was undertaken solely on the behest of the patient's attendants.

CONCLUSION

Necrotizing fasciitis in diabetic patients can result in significant morbidity like large soft tissue defects of the involved skin region that may need a plastic reconstruction or left to heal. Cooperation between the members of multi-disciplinary team is crucial with high index of suspicion of possible complications. Proper diagnosis, preparation and management of comorbidities, surgical reconstruction if needed.

Another purpose to present this rare case to discuss the processes of wound healing that may have had an impact on this patient's remarkable cosmetic outcome despite no use of plastic surgical techniques used for skin coverage.

ACKNOWLEDGEMENTS

Authors would like to thanks Dr. S. P. Sharma for his valuable support during study.

Funding: No funding sources

Conflict of interest: None declared

Ethical approval: Not required

REFERENCES

1. Misiakos EP, Bagias G, Patapis P, Sotiropoulos D, Kanavidis P, Machairas A. Current concepts in the management of necrotizing fasciitis. *Frontiers in Surgery.* 2014;29(1):36.
2. Hakkarainen TW, Kopari NM, Pham TN, Evans HL. Necrotizing soft tissue infections: review and current concepts in treatment, systems of care, and outcomes. *Curr Probl Surg.* 2014;51(8):344-62.
3. Federman DG, Kravetz JD, Kirsner RS. Necrotizing fasciitis and cardiac catheterization. *Cutis.* 2004;73(1):49-52.
4. Chan HT, Low J, Wilson L, Harris OC, Cheng AC, Athan E. Case cluster of necrotizing fasciitis and cellulitis associated with vein sclerotherapy. *Emerg Infect Dis.* 2008;14(1):180-1.
5. Bharathan R, Hanson M. Diagnostic laparoscopy complicated by group A streptococcal necrotizing fasciitis. *J Minim Invasive Gynecol.* 2010;17(1):121-3.
6. Akcay EK, Cagil N, Yulek F. Necrotizing fasciitis of eyelid secondary to parotitis. *Eur J Ophthalmol.* 2008;18(1):128-30.
7. Anwar UM, Ahmad M, Sharpe DT. Necrotizing fasciitis after liposculpture. *Aesthetic Plast Surg.* 2004;28(6):426-7.
8. Bisno AL, Cockerill III FR, Bermudez CT. The initial outpatient-physician encounter in group A streptococcal necrotizing fasciitis. *Clinical infectious diseases.* 2000;31(2):607-8.
9. Gibbon KL, Bewley AP. Acquired streptococcal necrotizing fasciitis following excision of malignant melanoma. *Br J Dermatol.* 1999;141(4):717-9.
10. Sewell GS, Hsu VP, Jones SR. Zoster gangrenosum: necrotizing fasciitis as a complication of herpes zoster. *Am J Med.* 2000;108(6):520-1.
11. Tung-Yiu W, Jehn-Shyun H, Ching-Hung C, Hung-An C. Cervical necrotizing fasciitis of odontogenic origin: a report of 11 cases. *J Oral Maxillofac Surg.* 2000;58(12):1347-52.
12. Kihiczak GG, Schwartz RA, Kapila R. Necrotizing fasciitis: a deadly infection. *J Eur Acad Dermatol Venereol.* 2006;20(4):365-9.
13. Bahebeck J, Sobgui E, Loic F, Nonga BN, Mbanya JC, Sosso M. Limb-threatening and life-threatening diabetic extremities: clinical patterns and outcomes in 56 patients. *J Foot Ankle Surg.* 2010;49(1):43-6.
14. Stone DR, Gorbach SL. Necrotizing fasciitis. The changing spectrum. *Dermatol Clin.* 1997;15(2):213-20.
15. Cheng NC, Chang SC, Kuo YS, Wang JL, Tang YB. Necrotizing fasciitis caused by methicillin-resistant *Staphylococcus aureus* resulting in death. A report of three cases. *J Bone Joint Surg Am.* 2006;88(5):1107-10.
16. Gallup DG, Freedman MA, Meguiar RV, Freedman SN, Nolan TE. Necrotizing fasciitis in gynecologic and obstetric patients: a surgical emergency. *Am J Obstet Gynecol.* 2002;187:305-10.
DeMuro JP, Hanna AF, Chalas E, Cunha BA. Polymicrobial abdominal wall necrotizing fasciitis after cesarean section. *J Surg Case Rep.* 2012;9:10.

Cite this article as: Makhdoomi MA, Haraga A, Joseph M, Habeeb YA. Necrotising Fasciitis of lower anterior abdominal wall post lower segment caesarian section. *Int Surg J* 2018;5:3760-3.