

## Case Report

# Trichobezoar in the absence of trichotillomania: a consequence of occupational hazard

Rajiv Jain\*, Devendra Mahor

Department of Surgery, Sri Aurobindo Institute of Medical Sciences, Indore, India

**Received:** 05 April 2016

**Accepted:** 10 May 2016

### \*Correspondence:

Dr. Rajiv Jain,

E-mail: [rajivrameshjain@gmail.com](mailto:rajivrameshjain@gmail.com)

**Copyright:** © the author(s), publisher and licensee Medip Academy. This is an open-access article distributed under the terms of the Creative Commons Attribution Non-Commercial License, which permits unrestricted non-commercial use, distribution, and reproduction in any medium, provided the original work is properly cited.

## ABSTRACT

Trichobezoars are concretions of hair, which accumulate in the gastrointestinal tract. Trichotillomania is a psychiatric illness with compulsive desire to pull out ones hair. Trichobezoars are rarely described in the absence of trichotillomania. We report a case of trichobezoar associated with trichophagia in the absence of trichotillomania. An 18 year old thin built girl presented with complaints of pain in abdomen and upper abdominal fullness with loss of appetite and weight loss for the last 2 months. Ultrasound abdomen and upper gastrointestinal endoscopy were suggestive of gastric bezoars. Exploration of history revealed that the patient works as a hairstylist. However, she denied of pulling her own hairs. Physical examination of scalp and other body parts did not show any evidence of alopecia or pulling of hair/short hair. She was managed surgically and was counseled about the consequences of eating hairs and was discouraged from eating hair. The absence of trichotillomania should not be considered as absence of trichophagia and sometime the occupational history of the patient can be helpful in leading to the diagnosis.

**Keywords:** Trichobezoar, Trichotillomania, Trichophagia, Hairstylist

## INTRODUCTION

Bezoars are foreign bodies in the gastrointestinal tract that increases in size by accretion of nonabsorbable foods and fibers. Bezoar usually originates in the stomach may contain vegetable fibers (phytobezoar) hair, (trichobezoar), persimmons (disopyrobezoar) or inspissated milk or formula (lactobezoar).<sup>1</sup>

Trichobezoars are often associated with psychiatry disorder like trichotillomania, mental retardation, emotional disturbances and/or pica.<sup>1</sup> Most of the cases of trichobezoars are described in adolescent girls/young females.<sup>2,3</sup> The first description of postmortem human bezoar was by swain 1854.

Although trichobezoars mostly involve the stomach, in rare condition trichobezoar can extends to other parts of the intestine like, duodenum, jejunum and colon. This

condition is called the Rapunzel syndrome first described in 1968.<sup>1,4-6</sup> Although the prevalence of bezoar in humans are low but if treatment is not administered the mortality may be as high as 30% primarily because GI bleeding, destruction or perforation.<sup>6</sup> This case report describes trichobezoar in an 18 year old female who was a hairstylist by profession.

## CASE REPORT

An 18-year-old girl presented in surgery department out patient at Sri Aurobindo medical college and PG institute, indore, india with the complaints of pain in abdomen with epigastric fullness and sensation of lump since 2 months. Initially the pain was mild and the intensity of pain has increased since 8-10 days. Pain was of dull aching and continuous in nature which was localized in the epigastric and left lumbar region. The intensity of pain increase after heavy meals.

She also had a history of loss of appetite within the due course of illness and she also had history of weight loss of around 5 kg in the last 6 months. Bowel and bladder habits of the patient were normal.

On physical examination, she was thin built and total body weight (TBW) was 40 kg. She was pale but hemodynamically stable and there was no clubbing, edema or lymphadenopathy and her neurologic examination was normal.

She had a scaphoid abdomen with bulge in the epigastric region on inspection and fullness was palpable in that region. There was a single, firm, mobile lump in the upper abdomen of around 8×6 cm in the epigastric region which was extending into umbilical area. It had smooth surface and irregular margin. Fingers can be insinuated between the lump and the left costal margin. The lump was moving with respiration. Carnett's sign was negative suggesting it to be an intraabdominal lump.

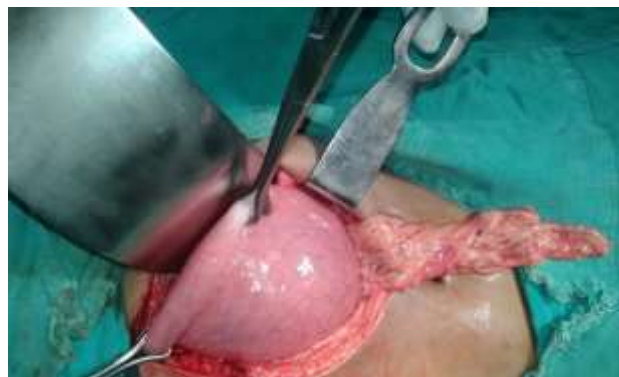Routine blood investigations were normal except for mild anemia hemoglobin was 9 gm/dL and PCV was 29.5%.

Ultrasonography revealed well circumscribed intragastric mass measuring 11×5×5 cm without any lymphadenopathy or any other abdominal pathology. Further evaluation was done by upper gastrointestinal endoscopy which was suggestive of trichobezoar. CECT Scan of the abdomen was done in which there was evidence of nonenhancing intragastric well circumscribed inhomogenous mass consisting of "mottled gas pattern" in the body and antropyloric region of the stomach measuring 13.2×5.0×6.0 cm suggestive of gastric bezoar.

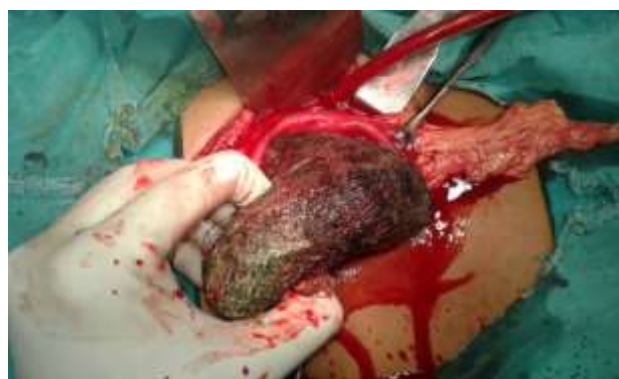On further probing about the relevant history, the patient denied pulling out her own hairs and eating any abnormal things like hair etc. Physical examination of scalp and other body parts did not reveal any evidence of alopecia or pulling of hair/short hair. But, she confirmed that she works at a local Beauty Saloon as a hair stylist.

Past history did not reveal any evidence of depressive disorders, obsessive compulsive disorder, other anxiety disorders, eating disorders, emotional disturbances, mental sub normality and other impulse control disorders. Also, there was no family history of any mental illness.

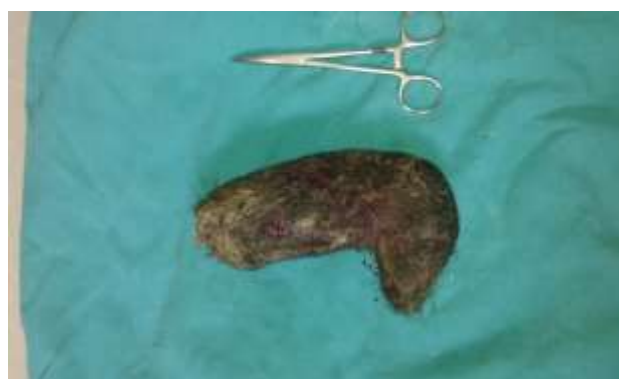Psychiatry opinion of the patient was done as well and they opined for narcoanalysis/hypnosis of the patient. After adequate evaluation, the patient was planned for exploratory laparotomy. During surgery, abdominal wall opened in layers and stomach was found hugely dilated occupying a large part of peritoneal cavity. Rest of the abdominal viscera was found normal. The stomach was opened by anterior gastrotomy over the body of the stomach.



**Figure 1: Intraoperative photograph showing hugely distended stomach.**



**Figure 2: Intra operative photograph after gastrotomy and showing the en masse removal of a huge trichobezoar.**

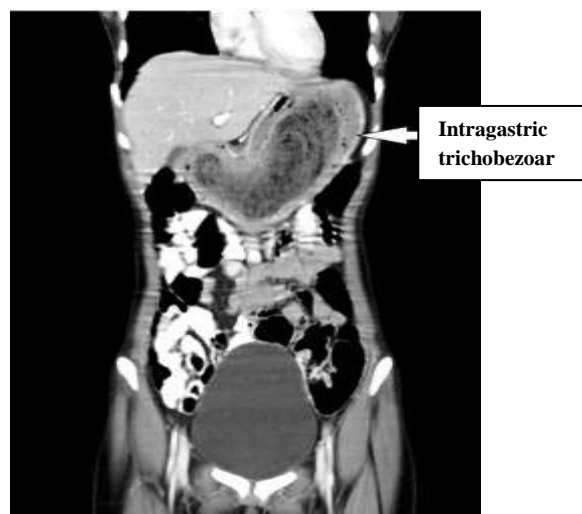


**Figure 3: Specimen of Stomach-shaped trichobezoar of weight approximately 550.**

A huge stomach-shaped trichobezoar lump occupying almost whole of the stomach which was extending up to the pylorus. The hair ball was evacuated en masse from the stomach and gastrotomy closure was done in double layers by PDS 2-0 suture as shown in Figure 3.

The trichobezoar weighed 550 grams. The surgery and the post op recovery were uneventful and the patient was discharged in a healthy condition after review psychiatry opinion. Counseling of the patient and her family was

done regarding abstinence from eating hairs and change of profession.



**Figure 4: Contrast enhancing CT scan in axial reconstruction.**

The Figure 4 is showing non enhancing intragastric well circumscribed inhomogenous mass consisting of “mottled gas pattern” in the body and antropyloric region of the stomach s/o trichobezoar.

## DISCUSSION

The term “bezoar” is understood to be derived from the arabic word “bazehr” or the persian word “padzhar”, which are used for antidote, because traditionally stones from the stomach or intestine of various animals were considered to have medicinal value.<sup>7</sup>

In terms of pathogenesis of trichobezoar, it is believed that because of its smooth surface the hairs do not move forward with the peristaltic movement and resultantly get accumulated.<sup>8</sup>

Trichophagia and trichobezoar are abundantly described in surgical literature.<sup>1-15</sup> In majority of the literature trichotillomania and trichophagia has coexisted with trichobezoar. Majority patient suffers from trichotillomania, a type of pica that was first described in 1889 as an irresistible urge to pull one’s hair and subsequent trichophagia, the oral ingestion of hair.<sup>9</sup>

In few cases, no evidence of trichotillomania was found in patients presenting with trichobezoar.<sup>10,11</sup> Trichobezoar should be considered as a differential diagnosis in young females who present with non-specific symptoms such as epigastric pain, fatigue, weight loss and epigastric mass.

The complications of trichobezoar are including bowel obstruction, nausea and vomiting, sensation of mass and fullness, loss of appetite and in severe cases perforation and bleeding have been reported.<sup>12,13</sup> Especially in

patients with mental retardation or any psycho-logical problem we should keep this diagnose in mind to avoid severity in this condition.

Treatment for symptomatic gastrobezoar is usually surgical intervention but some advocate primary non-surgical attempts such as transendoscopic fragmentation and extraction or transendoscopic lytic enzyme administration although the success of these methods depends on the size of trichobezoar and its duration of formation. Older trichobezoar is much harder to treat with transendoscopic lytic enzyme administration.<sup>12</sup>

The most important step in this disease is primary diagnosis and post treatment prophylaxis against further bezoar formation by the patient.

Management of trichotillomania and pica involves psychoeducation, behaviour therapy (habit reversal therapy in case patient has trichotillomania) and teaching adaptive coping skills. Due to the increased risk of recurrence the patients of trichobezoar must be followed up regularly.<sup>14,15</sup>

In this patient, the uncommon presentation was absence of trichotillomania but presence of trichophagia and subsequent trichobezoar. The uniqueness of the case lies in the absence of alopecia on physical examination and the correlation of disease progression and probably the origin of disease with her occupation that’s as a hairstylist. Present case had no psychiatric history, any evidence of psychological distress or specific personality traits which could be considered to be associated with trichophagia.

## CONCLUSION

We conclude that the presence of trichotillomania should not be considered as an essential prerequisite for the diagnosis of trichobezoar and trichophagia can be present without trichotillomania. The occupational history of the patient should be carefully sought as it can help us reaching an important diagnosis and apply preventive methods.

*Funding: No funding sources*

*Conflict of interest: None declared*

*Ethical approval: Not required*

## REFERENCES

1. Gonuguntla V, Joshi DD. Rapunzel syndrome: A comprehensive review of an unusual case of trichobezoar. Clin Med Res. 2009;7:99-102.
2. De Baek M, Ochsner W. Bezoars and concretions: A comprehensive Review of the literature with an analysis of 303 collected cases and a Presentation of 8 additional cases. Surgery. 1938;4:934-63.

3. Chintamani, Durkhure R, Singh JP, Singhal V. Cotton bezoar—a rare cause of intestinal obstruction: Case report. *BMC Surg*. 2003;3:5.
4. Gorter RR, Kneepkens CM, Mattens EC, Aronson DC, Heij HA. Management of trichobezoar: case report and literature review. *Pediatr Surg Int*. 2010;26:457-63.
5. Naik S, Gupta V, Naik S, Rangole A, Chaudhary AK, Jain P, Sharma AK. Rapunzel syndrome reviewed and redefined. *Dig Surg*. 2007;24:157-61.
6. Vaughan ED, Jr Sawyers JL, Scott HW. The Rapunzel syndrome. An unusual complication of intestinal bezoar. *Surgery*. 1968;63:339-43.
7. Williams RS. The fascinating history of bezoars. *Med J Aust*. 1986;145:613-4.
8. Frey AS, McKee M, King RA, Martin A. Hair apparent: Rapunzel syndrome. *Am J Psychiatry*. 2005;162:242-8.
9. Greenberg HR, Sarner CA. Trichotillomania: signs and symptoms. *Arch gen psychiatry*. 1965;12:482-9.
10. Tiago S, Nuno M, João A, Carla V, Gonçalo M, Joana N. Trichophagia and trichobezoar: Case report. *Clin Pract Epidemiol Ment Health*. 2012;8:43-5.
11. Islek A, Sayar E, Yılmaz A, Boneval C, Artan R. A rare outcome of iron deficiency and pica: Rapunzel syndrome in a 5 year old child iron deficiency and pica. *Turk J Gastroenterol*. 2014;25:100-2.
12. Gorter RR, Kneepkens CM, Mattens EC, Aronson DC, Heij HA. Management of trichobezoar: case report and literature review. *Pediatr Surg Int*. 2010;26:457-63.
13. Avissar E, Goldberg M, Lernau O. Bezoar-induced ulceration and perforation of the upper gastrointestinal tract in mentally retarded patients. *Pediatr Surg Int*. 1994;9:279-80.
14. Gurzu S, Jung I. Gastric trichowool bezoar in an 18 - year - old girl. *S Afr J Surg*. 2013;51:33-4.
15. Kırpınar I, Kocacenk T, Koçer E, Memmi N. Recurrent trichobezoar due to trichophagia: A case report. *Gen Hosp Psychiatry*. 2013;35:439-41.

**Cite this article as:** Jain R, Mahor D. Trichobezoar in the absence of trichotillomania: a consequence of occupational hazard. *Int Surg J* 2016;3:1630-3.