

Original Research Article

Evaluation of combined use of modified Alvarado score and Ultrasound in predicting acute appendicitis: a prospective study

Nirajan Kansakar^{1*}, P. N. Agarwal¹, Rajdeep Singh¹, Anurag Mishra¹,
Jyoti Kumar², N. S. Hadke¹, Srushti Sheth¹

¹Department of Surgery, ²Department of Radio-diagnosis, Maulana Azad Medical College, New Delhi, India

Received: 17 August 2018

Accepted: 28 September 2018

*Correspondence:

Dr. Nirajan Kansakar,

E-mail: nirajankansakar@gmail.com

Copyright: © the author(s), publisher and licensee Medip Academy. This is an open-access article distributed under the terms of the Creative Commons Attribution Non-Commercial License, which permits unrestricted non-commercial use, distribution, and reproduction in any medium, provided the original work is properly cited.

ABSTRACT

Background: Appendicitis is notorious in its ability to simulate other conditions and accurate diagnosis is imperative for preventing complications of appendicitis on one hand and avoiding negative appendectomy on other. Despite extraordinary advances in modern radiography imaging and diagnostic laboratory investigations, the accurate diagnosis of acute appendicitis remains an enigmatic challenge.

Methods: We evaluated 32 patients with features suggestive of acute appendicitis between September 2013 to March 2015. It was a cross-sectional observational study that included modified Alvarado score (MAS) and ultrasound (USG) in predicting appendicitis and correlated both these individually as well as combined, with histopathological findings. Statistical analysis was done by Chi-square test with Yates correction, Fischer's exact test and unpaired Students' t test.

Results: Ultrasound was found to be more sensitive (74.19%) and accurate (75.0%) as compared to MAS (41.94% and 43.75% respectively). The specificity and positive predictive value (PPV) were similar in both the parameters (100% each). Also, when both the MAS and Ultrasound were combined in predicting acute appendicitis, the sensitivity, negative predictive value and accuracy increased to 80.64%, 14.29% and 81.25% respectively with specificity and PPV being the same as when MAS and USG were considered individually.

Conclusions: It is advised that both modified Alvarado score and ultrasound whenever available should be used to predict acute appendicitis to increase the number of positive cases and reduce negative appendectomy and hence reduce the morbidity and mortality.

Keywords: Appendicitis, Appendectomy, Modified Alvarado score, Ultrasound

INTRODUCTION

Acute appendicitis is the most common surgical abdominal emergency with a life time prevalence of one in seven.¹ It has been 100 years since Fitz presented his classic paper describing the clinical features of appendicitis and recommended early removal of the inflamed appendix.² The diagnosis is mainly clinical, but appendicitis can mimic a variety of acute medical and surgical conditions. Early diagnosis of appendicitis is

important to prevent morbidity and mortality due to its complications like abscess and perforation leading to peritonitis. It has been shown that appendicular abscess occur in 2-6% and appendicular perforation in 25.8% of untreated patients.³ Performing an appendectomy on clinical suspicion alone will lead to 15-30% of negative appendectomies.^{4,5} In order to improve the diagnostic accuracy, a number of diagnostic modalities have been proposed, including clinical scoring systems, ultrasonography, CT scans, MRI and laparoscopy.⁶⁻⁸ The

commonly used clinical scoring system is the Alvarado Scoring System and its modifications. Since shift of neutrophilic maturation to left was not available in all emergency hospitals, modified Alvarado score was devised in which this parameter was not considered.⁹⁻¹¹ Among imaging modalities, graded compression ultrasonography is an inexpensive, fast and non-invasive method with an accuracy rate of 71-90% for the diagnosis of acute appendicitis.¹²⁻¹⁴ It is particularly useful in female patients when a differential diagnosis of twisted ovarian cyst, ectopic pregnancy or some other gynecological pathology is being suspected. It is proposed that a combination of these two modalities, i.e. modified Alvarado score and ultrasound, will lead to a higher accuracy rate and so decrease the negative appendectomy rate.¹⁵

METHODS

This study included 32 patients suspected of having acute appendicitis and was conducted in the Department of Surgery and Radio-diagnosis, Maulana Azad Medical College and associated Lok Nayak Hospital, New Delhi between September 2013 to March 2015 over a period of 18 months.

It was a cross-sectional observational study and included patients of 13 years and above with features of acute appendicitis. Patients with appendicular lump, appendicular perforation/ evidence of generalized peritonitis, appendicular abscess and pregnancy were excluded from the study. Written informed consent was taken from patients and assent form from parents/guardians of patients between 13 and 18 years of age.

The patients presenting with features suggestive of acute appendicitis were assessed clinically and modified Alvarado score was calculated and subsequently ultrasound abdomen (right iliac fossa) was done and findings were noted. Then the patients underwent appendectomy by open technique using grid-iron incision.

Table 1: The modified Alvarado score.

Features	Score	
Symptoms	Migratory right iliac fossa pain	1
	Nausea/vomiting	1
	Anorexia	1
Signs	Right iliac fossa (RIF) tenderness	2
	Fever 37.3°C	1
	Rebound tenderness in RIF	1
Laboratory test	Leucocytosis (>10000/mm ³)	2
Total		9

Modified Alvarado score ≥ 7 indicated high likelihood of acute appendicitis. Sonographic examinations were

performed in all cases by experienced sonographers using a linear array transducer of 5 MHz or 7.5 MHz and a standardized protocol involving graded compression, longitudinal and transverse images of the right lower quadrant. The ultrasound findings suggestive of acute appendicitis were noted and graded using a 5-point scale (Table 2).¹⁶

Table 2: Ultrasound score.

Score	Findings
1	Represented identification of a normal appendix
2	Indicated that the appendix was not seen, but no inflammatory changes or free fluid were evident
3	Indicated that the appendix was not seen, but secondary signs of appendicitis were present, such as a fecalith, pericecal fluid, or increased pericecal echogenicity consistent with infiltration of the mesenteric fat
4	Represented identification of an appendix of borderline enlarged size (5-6 mm)
5	Indicated acute appendicitis, defined as an enlarged non-compressible appendix with an outer diameter of greater than 6 mm

Findings graded 1 or 2 were classified as negative, and those graded 3 to 5 were classified as positive for acute appendicitis. MAS ≥ 7 indicated high likelihood of appendicitis, while USG score ≥ 3 was taken as positive for appendicitis. Hence combined score of ≥ 10 was taken as positive for appendicitis.

In patients undergoing appendectomy, the intra-operative findings suggestive of acute appendicitis were noted. Final diagnosis of acute appendicitis was made based on histopathology report. Patients were discharged when not running fever for 24hrs, accepting orally and passing flatus and faeces. Statistical analysis was done by Chi-square test with Yates correction, Fischer's exact test and unpaired Students' t test.

RESULTS

The mean age (SD) of the patients in the study was 27.41 \pm 7.14 years (15-50 years). Out of 32 patients evaluated, 13 patients had MAS ≥ 7 and 19 had MAS < 7 , while 23 had positive USG score for appendicitis and 9 had negative score in USG. When both the scores were combined, 25 patients had positive score (≥ 10) for appendicitis and 7 had negative score.

Nausea/vomiting (90.62%) was the commonest symptom, present in 29 patients, followed by anorexia (87.50%), present in 28 patients, while right iliac fossa tenderness (100%) was the commonest sign present in all the 32 patients. USG had a higher sensitivity (74.19%), NPV (11.11%) and accuracy (75.0%) as compared to MAS (41.94%, 5.26% and 43.75%).

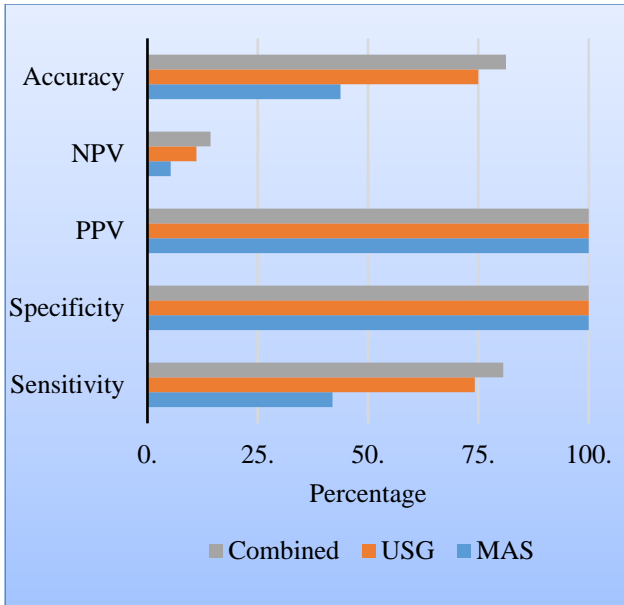


Figure 1: Comparison chart.

Combined use of MAS and USG had a higher sensitivity (80.64%), NPV (14.29%) and accuracy (81.25%) as compared to either of them individually -MAS (41.94%, 5.26% and 43.75% respectively), USG (74.19%, 11.11% and 75.0% respectively). MAS alone, USG alone and combined MAS & USG had similar specificity and PPV of 100% each. (Table 3 and Figure 1).

Table 3: Modified Alvarado score, ultrasound and combined MAS and ultrasound compared with histopathology.

	MAS		USG		Combined MAS and USG	
	≥7	<7	+ve	-ve	+ve	-ve
Appendicitis*	13	18	23	8	25	6
No appendicitis	0	1	0	1	0	1
Total	13	19	23	9	25	7
	32		32		32	

*Histopathologically proven

Negative appendectomy rate in this study was found to be 3.12%, as only one patient had normal appendix intra-operatively as well as on histopathology. The patient was a female with MAS of 6 and USG score of 1. Later on she was further worked up and a provisional diagnosis of right ureteric calculus was made.

DISCUSSION

Suspected acute appendicitis is one of the most common diagnostic dilemmas encountered in clinical practice. Although the diagnosis is primarily based on clinical findings, the presentation can be confusing, and classic features may be subtle or difficult to elicit more

commonly in children and elderly.¹⁷ According to some studies, negative appendectomy has been reported in 15-30% of appendectomies because of difficulty in making the diagnosis.^{5,18} This can impose a significant burden on the health system. For instance, 39901 patients underwent negative appendectomies in the US in 1997, which resulted in an estimated total hospital charge of 741.5 million dollars.¹⁹ Imaging plays an important role in the modern evaluation of abdominal pain, although a definitive consensus on the appropriate imaging workup protocol remains elusive.

Sonography can be performed at the bedside, involves a short acquisition time, does not use ionizing radiation, and may show evidence of other causes of abdominal pain such as ovarian cysts, tubo-ovarian mass, and mesenteric adenitis. Prior studies have suggested that a normal appendix should be identified to exclude acute appendicitis.¹⁹ In the evaluation of acute appendicitis, the visualization rate varies from institution to institution, from a high of 98% to a low of 22%.²⁰ Sonography can be limited by patient body habitus as well as the variable and at times inaccessible position of the appendix.

Patient undergoing appendectomy on clinical judgement alone had a diagnostic accuracy of 62-80%, negative appendectomy rate of 15-30% had been found in studies conducted by Jess et al, Dunn et al, Chang et al, Nasiri et al, Singh et al.²¹⁻²⁵ Diagnostic accuracy less than our study (81.25%) and negative appendectomy rate much more than our study (3.12%). Clinical scoring systems devised by Teicher et al, Gallego et al, Alvarado, Nasiri et al, Kurane et al had sensitivity ranging from 48 to 78%, while specificity of 73 to 87%, which is less than sensitivity (80.64%) and specificity (100%) of our diagnostic approach.^{7,26,9,24,27}

On comparing our diagnostic approach with our USG results, our diagnostic approach is more sensitive (80.64%) and more accurate (81.25%). Though negative appendectomy rate of USG in our study is low, but positive USG cannot be a pre-requisite for appendectomy as there is high false negative rate of 88.89%. It can only complement clinical scores or clinical judgement because in few cases inflamed appendix could not be visualised due to bowel gases or is missed due to inexperience of the radiologists.

CONCLUSION

It is advised that both modified Alvarado score and ultrasound whenever available should be used to predict acute appendicitis to increase the number of positive cases and reduce negative appendectomy and hence reduce the morbidity and mortality.

Funding: No funding sources

Conflict of interest: None declared

Ethical approval: The study was approved by the Institutional Ethics Committee

REFERENCES

1. Stephens PL, Mazzucco JJ. Comparison of ultrasound and the Alvarado score for the diagnosis of acute appendicitis. *Conn Med.* 1999;63:137-40.
2. Fitz RH. Perforating inflammation of the vermiform appendix with special reference to it's early diagnosis and treatment. *Am J Med Sci.* 1886;92:321-46.
3. Jaffe BM, Berger DH. The Appendix. In: Brunicaardi FC, Andersen DK, Billiar TR, Dunn DL, Hunter JG, Pollock RE. *Schwartz's Principle of Surgery.* New York: McGraw-Hill; 2005:1119-38.
4. Chan I, Bicknell SG, Graham M. Utility and diagnostic accuracy of sonography in detecting appendicitis in a community hospital. *Am J Roentgenol.* 2005;184:1809-12.
5. Flum DR, McClure TD, Morris A, Koepsell T. Misdiagnosis of appendicitis and the use of diagnostic imaging. *J Am Coll Surg.* 2005;201:933.
6. Olsen JB, Myren CJ, Haahr PE. Randomized study of the value of laparoscopy before appendectomy. *Br J Surg.* 1993;80:922-3.
7. Teicher I, Landa B, Cohen M, Cabnick LS, Wise L. Scoring system to aid in the diagnosis of appendicitis. *Ann Surg.* 1983;198:753-9.
8. Kalan M, Rich AJ, Talbot D, Cunliffe WJ. Evaluation of the modified Alvarado score in the diagnosis of acute appendicitis: a prospective study. *Ann R Coll Surg Engl.* 1994;76:418-9.
9. Alvarado A. A practical score for early diagnosis of acute appendicitis. *Ann Emerg Med.* 1986;15:557-64.
10. Horzic M, Salamon A, Kopljar M. Analysis of scores in diagnosis of acute appendicitis in women. *Coll Antropol.* 2005;11:4.
11. Flum DR, Koepsell T. The clinical and economic correlates of misdiagnosed appendicitis: nationwide analysis. *Arch Surg.* 2002;137:799-804.
12. Balthazar EJ. Appendicitis: prospective evaluation with high-resolution CT. *Radiol.* 1991;180:21-4.
13. Rao PM, Boland GWL. Imaging of acute right lower abdominal quadrant pain. *Clin Radiol.* 1998;53:639-49.
14. Horzic M, Salamon A, Kopljar M. Analysis of scores in diagnosis of acute appendicitis in women. *Coll Antropol.* 2005;29:133-8.
15. Nautiyal H, Ahmad S, Keshwani NK, Awasthi DN. Combined use of modified Alvarado score and USG in decreasing negative appendectomy rate. *Indian J Surg.* 2010;72:42-8.
16. Preeyacha P, Ying J, Linam LE, Brody AS, Babcock DS. Sonography in the evaluation of acute appendicitis: are negative sonographic findings good enough?. *J Ultrasound Med.* 2010;29:1749-55.
17. Rodriguez DP, Vargas S, Callahan MJ, Zurakowski D, Taylor GA. Appendicitis in young children: imaging experience and clinical outcomes. *Am J Roentgenol.* 2006;186:1158-64.
18. Macklin CP, Radcliffe GS, Merei JM, Stringer MD. A prospective evaluation of the modified Alvarado score for acute appendicitis in children. *Ann R Coll Surg Engl.* 1997;79:203-5.
19. Old JL, Dusing RW, Yap W, Dirks J. Imaging for suspected appendicitis. *Am Fam Physician.* 2005;71:71-8.
20. Taylor GA. Suspected appendicitis in children: in search of the single best diagnostic test. *Radiol.* 2004;231:293-5.
21. Jess P, Bjerregaard B, Brynitz, S, Christensen HJ, Kalaja E, Kristenssen LJ. Acute appendicitis prospective trial concerning diagnostic accuracy and complications. *Am J Surg.* 1981;141:232-4.
22. Dunn EL, Moore EE, Elderling SC, Murphy JR. The unnecessary laparotomy for appendicitis: can it be decreased? *Am Surg.* 1982;48:320-3.
23. Chang FC, Hogle HH, Welling DA. The fate of the negative appendix. *Am J Surg.* 1974;126:752-4.
24. Nasiri S, Mohebbi F, Sodagari N, Hedayat A. Diagnostic values of ultrasound and the modified Alvarado scoring system in acute appendicitis. *Int J Emerg Med.* 2012;5:26.
25. Singh K, Gupta S, Pargal P. Application of Alvarado scoring system in diagnosis of acute appendicitis. *JK Sci.* 2008;10:84-6.
26. Gallego MG, Fadrique B, Nieto MA. Evaluation of ultrasonography and clinical diagnostic scoring in suspected appendicitis. *Br J Surg.* 1998;85:37-40.
27. Kurane SB, Sangolli MS, Gogate SA. A one-year prospective study to compare and evaluate diagnostic accuracy of modified Alvarado score and ultrasonography in acute appendicitis, in adults. *Indian J Surg.* 2008;70:125-9.

Cite this article as: Kansakar N, Agarwal PN, Singh R, Mishra A, Kumar J, Hadke NS, Sheth S. Evaluation of combined use of modified Alvarado score and Ultrasound in predicting acute appendicitis: a prospective study. *Int Surg J* 2018;5:3594-7.