

Case Report

Fracture penis: rare occurrence

Akhilesh Kumar Yadav^{1*}, Sankalp Dwivedi¹, Sagar Bassi¹, Sunil Kumar Singh²

¹Department of General Surgery, MM Institute of Medical Sciences and Research, Mullana Ambala, Haryana, India

²Department of General Surgery, Teerthanker Mahaveer Medical College and Research Centre Moradabad, Uttar Pradesh, India

Received: 17 August 2018

Accepted: 27 September 2018

***Correspondence:**

Dr. Akhilesh Kumar Yadav,

E-mail: drakkicool91@gmail.com

Copyright: © the author(s), publisher and licensee Medip Academy. This is an open-access article distributed under the terms of the Creative Commons Attribution Non-Commercial License, which permits unrestricted non-commercial use, distribution, and reproduction in any medium, provided the original work is properly cited.

ABSTRACT

Fracture Penis is not usual. It is a tear in the tunica albuginea of the corpora cavernosa with or without involvement of corpus spongiosum and urethra. The usual cause is abrupt bending of the erect penis by blunt trauma, most commonly during sexual intercourse. A crackling sound, pain, detumescences, bruising, swelling, and bleeding per urethra are the common symptoms reported by the patients. Early surgical management is treatment of choice. Diagnosis of Penile Fracture refers to a rupture of the corpus cavernosum induced by blunt trauma to erect penis. Mainly diagnosed clinically from their stereotypical crackling sound from the erect penis at the moment of injury, rapidly followed by acute swelling, pain and penile deformity. Treatment recommendations include immediate exploration and repair. Surgical repair requires evacuation of hematoma, identification of tear, repair of the tear and ligation of any disrupted vasculature. Long term complications after repair include penile deviation, painful intercourse, painful erection and erectile dysfunction. The diagnosis of penile fracture is mostly clinical. Based on physical examination and typical crackling sound at the time of injury. Prompt surgical exploration and repair are advocated in almost all cases. Immediate surgery reduces long term complication which is post-traumatic penile curvature.

Keywords: Corpus cavernosum, Crackling sound, Fracture Penis, USG

INTRODUCTION

Fracture Penis is not usual. It is a tear in the tunica albuginea of the corpora cavernosa with or without involvement of corpus spongiosum and urethra. Diagnosis is usually clinical examination and history told by the patient.

And urethral injury should always be suspected, especially in cases with bilateral cavernoma rupture. The usual cause is abrupt bending of the erect penis by blunt trauma, most commonly during sexual intercourse or by exotic masturbation. A crackling sound, pain, detumescences, bruising, swelling, and bleeding per

urethra are the common symptoms reported by the patients.

Early surgical management is the treatment of choice with low incidence of complications. And also, treatment should be directed to preserve the erectile function and length of the penis and to maintain the ability to urinate.^{1,2}

We here presented a case report of successful management by surgical intervention for rupture of cavernous body, which is diagnosed by taken full history and clinical examination and also taken help of contrast-enhanced ultrasound in a patient of penile fracture.

CASE REPORT

We report a case of 40 years male patient admitted in emergency. Presented with acute penile pain for 15 hours associated with penile swelling post blunt trauma during sexual intercourse and he noticed no erection after trauma.

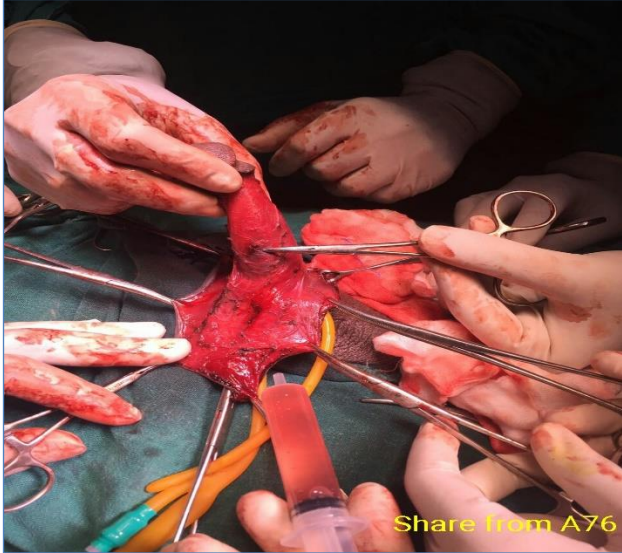


Figure 1: Intra-operative finding.

Patient details acquired. Complete history taken, vitals noted, hemogram, Blood grouping, with USG Pelvis and genitals was done. Patient received good post-op care. And scrotal support was followed.

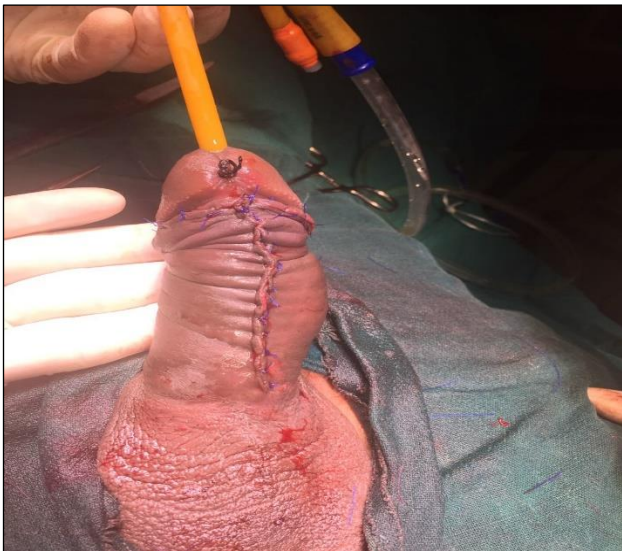

Figure 2: After Surgical Intervention with folly's in-situ.

Case history

Patient came with history of pain, swelling and discoloration of the penis. Patient gave history of sudden

acute pain in penis post blunt trauma while having sexual intercourse for 15 hours. With no associated history of hematuria and no dysuria.

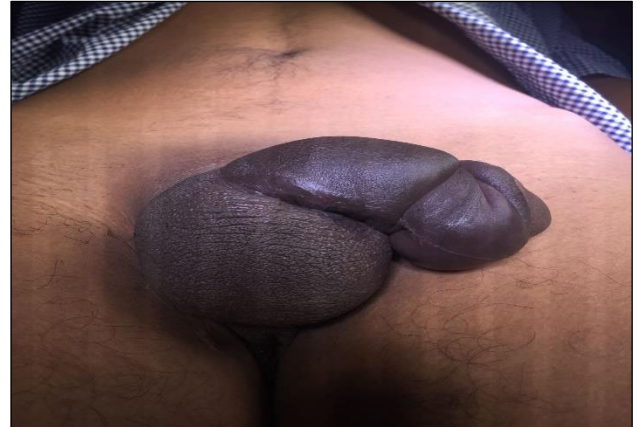

Figure 3: On Clinical Examination.

Clinical examination

- Physical examination revealed swollen, echymotic penis.
- Tenderness present over the shaft of the penis.
- Penis was flaccid and deviated to the left side with discoloration of shaft.
- Swelling of prepuce with detumescence.
- USG penis results that focal discontinuity of proximal tunica albuginea. Suggestive of a penile fracture and there was heterogeneous lesion suggestive hematoma of the left corpus cavernosum of penis adjacent to penile (Figure 4, 5 and 6).

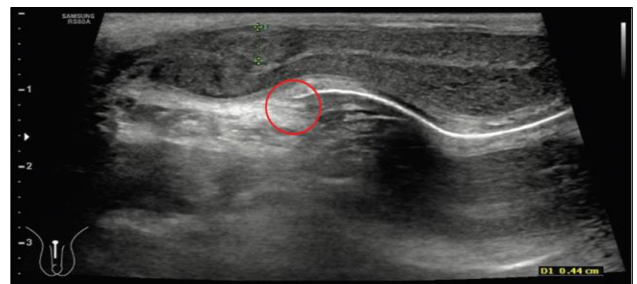


Figure 4: Ultrasonography of penis.

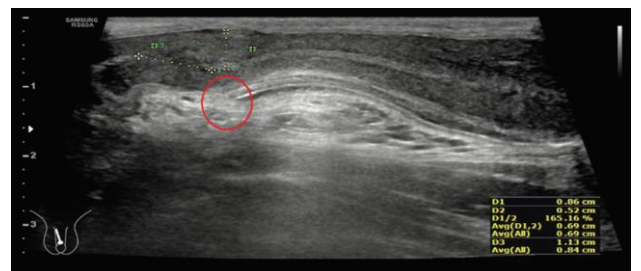


Figure 5: Ultrasonography of the penis: Focal discontinuity of proximal tunica albuginea is pointed by the red circle.

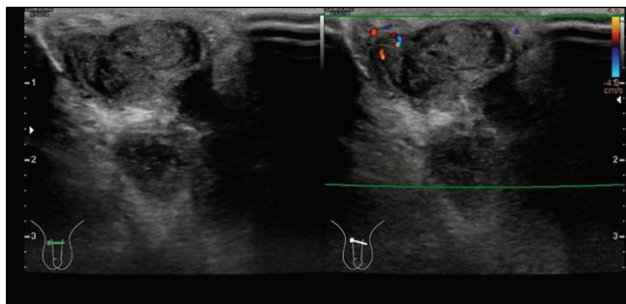


Figure 6: USG shows: Focal discontinuity of proximal tunica albuginea is pointed by the red circle.

Treatment

- Patient catheterized with Foley 16fr and routine investigations were done.
- Patient planned for immediate surgical exploration and repair of the defect. Distal circumferential subcornal-degloving was made and hematoma evacuated also showed a tear of tunica albuginea of right sided corpus cavernosum. Defect was repaired with 4-0 proline and skin with 3-0 proline.
- Dressing and Scrotal support put.

DISCUSSION

- Penile fracture is mostly uncommon because of the well-protected location in the body and a high degree of genital mobility.^{1,2}
- Penile traumas generally occur in the proximal or mid shaft of the erect penis, and Concomitant lesions to the urethra occur in approximately 10-20% of patients.^{3,4}
- Penile fracture is the term used to describe a traumatic rupture of the tunica albuginea of the corpora cavernosa affecting the erect penis.
- A clinical diagnosis can often be easily made with the typical history and physical examination findings.
- Diagnosis of Penile Fracture refers to a rupture of the corpus cavernosum induced by blunt trauma to erect penis.
- Mainly diagnosed clinically from their stereotypical crackling sound from the erect penis at the moment of injury, rapidly followed by acute swelling, pain and penile deformity.⁵
- Conservative management of penile trauma lead to increased rate of complications, such as penile

curvature or erectile dysfunction, compared to immediate surgical intervention.⁶

- Treatment recommendations include immediate exploration and repair with non- absorbable suture material. Surgical repair requires evacuation of hematoma, identification of tear, repair of the tear and ligation of any disrupted vasculature.
- Long term complications after repair include penile deviation, painful intercourse, painful erection and erectile dysfunction.⁷

CONCLUSION

The diagnosis of penile fracture is mostly clinical. Based on physical examination and typical crackling sound at the time of injury. Prompt surgical exploration and repair are advocated in almost all cases. Immediate surgery reduces long term complication which is post-traumatic penile curvature.

Funding: No funding sources

Conflict of interest: None declared

Ethical approval: Not required

REFERENCES

1. Eke N. Fracture of the penis. Br J Surg. 2002;89:555-65.
2. Kamil N, Hisham AN, Abdullah M, Khairullah A. Fracture of the penis. Med J Malaysia. 1993;48:373-6.
3. Nomura JT, Sierzenski PR. Ultrasound diagnosis of penile fracture. J Emerg Med. 2010;38:362-5.
4. Dell'Atti L. The role of ultrasonography in the diagnosis and management of penile trauma. J Ultrasound. 2016;19:161-6.
5. Hassali MA, Nouri AI. Role of penile Doppler as a diagnostic tool in penile fracture. J Med Ultrasound. 2018;26:48-51.
6. Atti LD. Rupture of the cavernous body diagnosed by contrast-enhanced ultrasound: presentation of a clinical case. Italino Archive of Urology and Andrology. 2018;90(2):143-4.
7. Burro R. Penile fracture: a preliminary report. IBJU. 2018;44(4):800-4.

Cite this article as: Yadav AK, Dwivedi S, Bassi S, Singh SK. Fracture penis: rare occurrence. Int Surg J 2018;5:3747-9.