

## Case Report

# Splenic lymphangioma: a rare benign tumor in adults

Mohammed Raza, Preethi S. P., Harish Kumar P., Mir Zeeshan Ali, Pranav Jasuja\*

Department of General Surgery, JSSH, Mysuru, Karnataka, India

**Received:** 11 August 2018

**Accepted:** 24 August 2018

**\*Correspondence:**

Dr. Pranav Jasuja,

E-mail: [pranavjasuja@gmail.com](mailto:pranavjasuja@gmail.com)

**Copyright:** © the author(s), publisher and licensee Medip Academy. This is an open-access article distributed under the terms of the Creative Commons Attribution Non-Commercial License, which permits unrestricted non-commercial use, distribution, and reproduction in any medium, provided the original work is properly cited.

### ABSTRACT

Primary benign tumors of the spleen are extremely rare and account for less than 0.007% of all tumors identified upon surgery and autopsy. Splenic lymphangioma is a rare malformation of the splenic lymphatic channels, mostly seen in children. It is characterized by the presence of cysts, resulting from increases in the size and number of thin-walled lymphatic vessels that are abnormally interconnected and dilated. We report the case of 45-year-old female, came with chief complaint of pain abdomen for 1 month. Radiological imaging showed multiple echogenic non-enhancing lesions with septate cystic changes. Splenectomy was done. HPE was reported as Splenic Lymphangioma. The clinical picture is variable; small lesions are often incidentally detected through imaging studies, while larger lesions can result in compression of organs, causing pain or rupture even after minor trauma. Therefore, splenic lymphangiomas should be considered in the differential diagnosis of splenomegaly or left upper quadrant pain even among adults and should be immediately treated with splenectomy; delay in the therapeutic intervention can lead to life-threatening complications.

**Keywords:** Lymphangioma, Spleen, Splenectomy

### INTRODUCTION

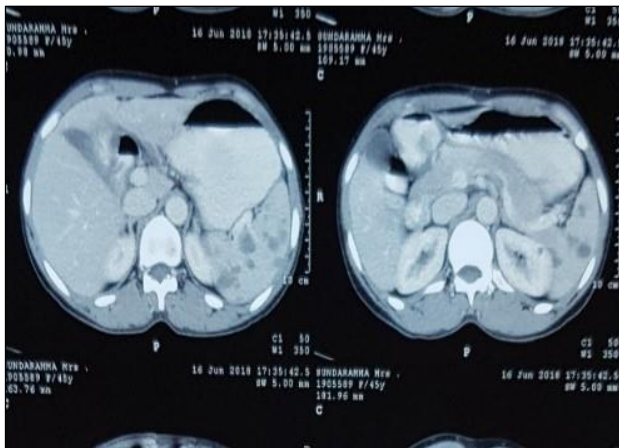
Lymphangiomas are benign malformations of the lymphatic system, usually found in the neck (75%) and axilla (20%) and less commonly encountered in the orbit, mediastinum, adrenal gland, kidney, bone, omentum, gastrointestinal tract, retroperitoneum, liver, and pancreas.<sup>1-3</sup> They were first described by Rodender in 1828; however, the first case involving the spleen was reported in 1885 by Frink.<sup>4,5</sup> Between 1939 and 2017, only 209 cases of splenic lymphangiomas were reported in the literature.<sup>6</sup> Therefore, splenic lymphangiomas are considered uncommon benign tumors, occurring mainly in childhood, with only a few cases reported in adults.<sup>7</sup> In most patients, the lymphangiomatous process involves additional sites in a diffuse or multifocal fashion such as the liver, mediastinum, and lung, the so-called

lymphangiomatosis syndrome.<sup>7</sup> Some cases of splenic lymphangiomas are associated with synchronous or metachronous cystic hygroma of the neck.<sup>8</sup> Isolated splenic lymphangiomas constitute a much rarer form; only 15 cases between 1990 and 2017 were reported.<sup>9,10</sup> Rarely, splenic lymphangiomas can be part of Klippel-Trenaunay syndrome (characterized by varicose veins, bony and soft tissue hypertrophy, cutaneous hemangiomas, and/or malformations of the lymphatic system).<sup>11</sup> Although no consensus has yet been reached on whether splenic lymphangioma is a neoplasm or a hamartoma, most researchers support the latter opinion; its formation is proposed to be due to abnormal congenital development of lymphatic vessels.<sup>5</sup> It can also be attributed to bleeding or inflammation in the lymphatic system, which causes obstruction and consequent lymphangiectasia.<sup>5,8,10</sup>

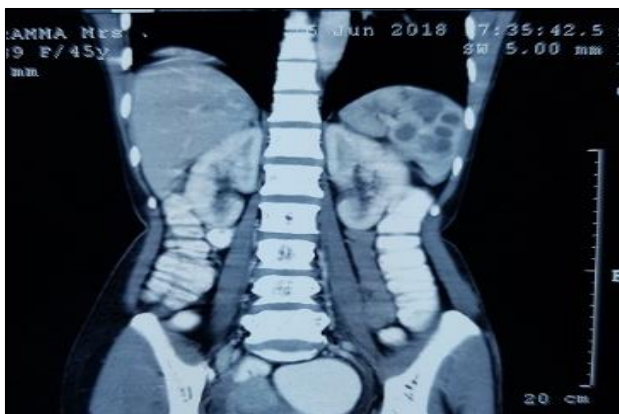## CASE REPORT

A 45-year-old female came to outpatient department of Department of General Surgery, JSSH, Mysore with one-year history of diffuse pain abdomen mainly in the epigastric region and left hypochondrium without any aggravating or relieving factors. There was no history of bowel and bladder disturbances. Patient gave history of Pulmonary Tuberculosis 20 years back, took full course of ATT. No history of weight loss.

Physical examination showed diffuse pain upon superficial and deep palpation of the abdomen, with no organomegaly. The laboratory tests were normal. Abdominal UGD showed multiple echogenic lesions in spleen with septate cystic changes. An abdominal CT with oral and intravenous contrast was done which showed multiple non-enhancing iso to hypodense lesions of varying sizes in the spleen largest measuring 3.7cm x 1.6 cm in the upper pole (Figure 1 and 2). In view of these findings Splenectomy was planned. Surgery was done under general anaesthesia. Intraoperatively spleen was found to be nodular, splenectomy was done, and specimen was sent for histopathological examination.

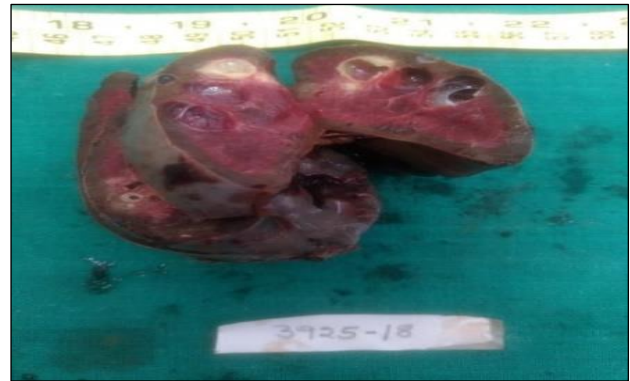

**Figure 1: Horizontal cut section showing non-enhancing iso to hypodense lesions in spleen.**



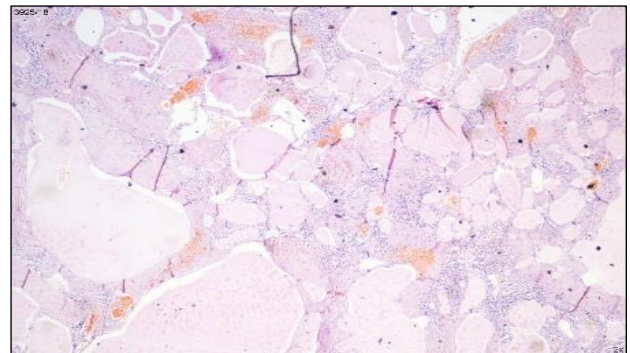
**Figure 2: Coronal cut section showing non-enhancing iso to hypodense lesions in spleen.**

Macroscopic cross-sections revealed multiple cystic spaces of various diameter filled with serous fluid (Figure 3).



**Figure 3: Macroscopic cut section of spleen showing multiple cysts.**

Microscopic multiple cut sections show splenic tissue with numerous cystic spaces lined by discontinuous flat endothelial cells filled with proteinaceous material, occasional spaces show RBC's. Also seen is the large cystic space lined by a fibrotic wall. Features suggestive of Lymphangioma Spleen (Figure 4).



**Figure 4: Microscopic cut section of spleen showing lymphoid follicles.**

Post operatively after 1-month patient is doing well with completely healed scar.

## DISCUSSION

The clinical manifestations of splenic lymphangiomas are usually related to the size of the spleen.<sup>8</sup> In most cases, isolated splenic lymphangiomas are asymptomatic and incidentally detected through abdominal ultrasonography or abdominal computed tomography. Large cystic lesions can attain sufficient size to cause significant symptoms and signs.<sup>8,12</sup> The symptoms may include left upper quadrant pain, loss of appetite, nausea, vomiting, and signs of abdominal distension or a palpable mass. Most are usually nonspecific and are due to compression of adjacent organs such as the stomach, diaphragm, or kidney.<sup>8</sup> Infection or rupture of a lymphangioma can

present as an acute abdomen.<sup>8,13</sup> Cases have been reported of larger lymphangiomas complicated by consumptive coagulopathy, bleeding, hypersplenism, and portal hypertension.<sup>8,14</sup> The pathophysiological consequences of a lymphangioma exceeding 3 to 4 kg can be diaphragmatic immobility and lung atelectasis or pneumonia.<sup>8,13</sup> Rarely, hypertension due to compression of the renal artery by the splenic mass can be seen.<sup>8,15</sup>

### **Treatment and prognosis**

The treatment of choice for splenic lymphangiomas is complete surgical resection because other therapeutic modalities (aspiration, drainage, and irradiation) have shown unsatisfactory results.<sup>16,17</sup> Some investigators prefer conservative treatment in the case of small asymptomatic lesions detected incidentally, reserving splenectomy for large, multiple, or symptomatic lesions.<sup>16,18</sup> Partial resection techniques have also been applied in cases of limited disease; however, leaving a splenic remnant in cases of diffuse involvement increases the risk of further growth and enlargement, sometimes requiring a second operation. Laparoscopic splenectomy is emerging as the procedure of choice in patients with a normal to moderately enlarged spleen but is considered a contraindication in patients with massive splenomegaly.<sup>19</sup> The most important aspect when considering treatment options is that surgery should be recommended immediately after the diagnosis has been established to avoid complications such as infection, hemorrhage, rupture, intestinal obstruction, and tumor enlargement that may eventually prevent complete removal.<sup>16</sup> The prognosis of splenic lymphangioma after resection is favourable. The main complication is recurrence, which is demonstrated in 9.5% of patients, frequently after incomplete resection.<sup>5</sup>

### **CONCLUSION**

Splenic lymphangioma is a rare malformation of the splenic lymphatic system, mostly seen in children and rarely in adults. Although the etiology is still unclear, it is considered more likely a hamartomatous process rather than a neoplasm. Histologically, splenic lymphangioma is characterized by the presence of cysts lined by attenuated endothelial cells. The condition may involve only the spleen, but in most cases, it is part of a systemic malformation of lymphatic channels that affects multiple organs (systemic lymphangiomatosis).

Most lesions are incidentally detected through imaging studies, while larger lesions can cause compression of adjacent organs, with various symptoms. Therefore, splenic lymphangiomas should be considered in the differential diagnosis of splenomegaly or left upper quadrant pain even among adults because they are amenable to curative treatment. Delay in their surgical intervention may lead to severe complications such as infection, rupture, and hemorrhage.

*Funding: No funding sources*

*Conflict of interest: None declared*

*Ethical approval: Not required*

### **REFERENCES**

1. Kosir MA, Sonnino RE, Gauderer MW. Pediatric abdominal lymphangiomas: a plea for early recognition. *J Pediatr Surg.* 1991;26(11):1309-13.
2. Davidson AJ, Hartman DS. Lymphangioma of the retroperitoneum: CT and sonographic characteristic. *Radiol.* 1990;175(2):507-10.
3. Chang WC, Liou CH, Kao HW, Hsu CC, Chen CY, Yu CY. Solitary lymphangioma of the spleen: dynamic MR findings with pathological correlation. *Br J Radiol.* 2007;80(949):e4-e6.
4. Avigad S, Jaffe R, Frand M, Izhak Y, Rotem Y. Lymphangiomatosis with splenic involvement. *JAMA.* 1976;236(20):2315-7.
5. Chung SH, Park YS, Jo YJ. Asymptomatic lymphangioma involving the spleen and retroperitoneum in adults. *World J Gastroenterol.* 2009;15(44):5620-3.
6. Asch MJ, Cohen AH, Moore TC. Hepatic and splenic lymphangiomatosis with skeletal involvement: report of a case and review of the literature. *Surg.* 1974;76(2):334-9.
7. Solomou EG, Patriarheas GV, Mpadra FA, Karamouzis MV, Dimopoulos I. Asymptomatic adult cystic lymphangioma of the spleen: case report and review of the literature. *Magn Reson Imaging.* 2003;21(1):81-4.
8. Abbott RM, Levy AD, Aguilera NS, Gorospe L, Thompson WM. From the archives of the AFIP: primary vascular neoplasms of the spleen: radiologic-pathologic correlation. *Radiograph.* 2004;24(4):1137-63.
9. Wadsworth DT, Newman B, Abramson SJ, Carpenter BL, Lorenzo RL. Splenic lymphangiomatosis in children. *Radiol.* 1997;202(1):173-6.
10. Patti R, Iannitto E, Di Vita G. Splenic lymphangiomatosis showing rapid growth during lactation: a case report. *World J Gastroenterol.* 2010;16(9):1155-7.
11. Jindal R, Sullivan R, Rodda B. Splenic malformation in a patient with Klippel-Trenaunay syndrome: a case report. *J Vasc Surg.* 2006;43(4):848-50.
12. Komatsuda T, Ishida H, Konno K. Splenic lymphangioma: US and CT diagnosis and clinical manifestations. *Abdom Imaging.* 1999;24(4):414-7.
13. Moir C, Guttman F, Jequier S, Sonnino R, Youssef S. Splenic cysts: aspiration, sclerosis, or resection. *J Pediatr Surg.* 1989;24(7):646-8.
14. Dietz WH Jr, Stuart MJ. Splenic consumptive coagulopathy in a patient with disseminated lymphangiomatosis. *J Pediatr.* 1977;90(3):421-3.
15. Economides NG, Benton BF, Fortner TM, Miles RM. Splenic pseudocysts: report of two cases and

- review of the literature. *Am Surg*. 1980;46(11):644-8.
16. Yu X, Yu J, Liang P, Liu F. Real-time contrast-enhanced ultrasound in diagnosing of focal spleen lesions. *Eur J Radiol*. 2012;81(3):430-6.
  17. Makrin V, Avital S, White I, Sagie B, Szold A. Laparoscopic splenectomy for solitary splenic tumors. *Surg Endosc*. 2008;22(9):2009-12.
  18. Lam KY, Tang V. Metastatic tumors to the spleen: a 25-year clinicopathologic study. *Arch Pathol Lab Med*. 2000;124(4):526-30.
  19. Maurus CF, Schäfer M, Müller MK, Clavien PA, Weber M. Laparoscopic versus open splenectomy for nontraumatic diseases. *World J Surg*. 2008;32(11):2444-9.

**Cite this article as:** Raza M, Preethi SP, Kumar HP, Ali MZ, Jasuja P. Splenic lymphangioma: a rare benign tumor in adults. *Int Surg J* 2018;5:3403-6.