

Case Report

Mesenteric lipomatosis presenting as abdominal mass with concurrent ileal gastrointestinal stromal tumour (GIST): an unusual presentation

Suma S., Shashirekha C. A.*, Ravikiran H. R., Vikranth S. N.

Department of Surgery, Sri Devaraj Urs Medical College, Tamaka, Kolar, Karnataka, India

Received: 28 April 2018

Accepted: 28 May 2018

*Correspondence:

Dr. Shashirekha C. A.,

E-mail: dr.ca_shashirekha@yahoo.co.in

Copyright: © the author(s), publisher and licensee Medip Academy. This is an open-access article distributed under the terms of the Creative Commons Attribution Non-Commercial License, which permits unrestricted non-commercial use, distribution, and reproduction in any medium, provided the original work is properly cited.

ABSTRACT

Lipomas are benign tumours consisting of mature fat cells and are perhaps the most common neoplasm. It can be solitary or multiple occurring throughout the whole body, but it can rarely originate in the intestinal mesentery. These tumours have very little potential for malignancy with the incidence of sarcomatous change in less than 1% of cases. Concurrent occurrence of gastrointestinal stromal tumour which arises from the mesenchymal components of the gastric and small bowel mucosa is a rarity. Here we present a rare case of mesenteric lipomatosis presenting as mass per abdomen which on evaluation and exploration of abdomen turned out to be multiple mesenteric lipomas with another hard mass arising from the antimesenteric border of the small intestine (ileum), for which mesenteric lipoma excision and resection of hard mass along with the segment of ileum and end to end anastomosis was done.

Keywords: Abdominal mass, Computed tomography, Gastrointestinal stromal tumor, Mesentery, Multiple lipoma

INTRODUCTION

Lipoma is a benign soft tissue tumor, composed of mature fat tissue. Solitary or multiple lipoma can occur almost anywhere in the body like the extremities, trunk, mediastinum, pelvis and retroperitoneum. They are generally slow growing, lobulated, soft mobile mass which doesn't penetrate into the surrounding structures.^{1,2} Presence of mesenteric lipoma is a rarity.

From the literature review, the mesenteric lipomas don't cause any intestinal symptoms as they allow easy passage of the intestinal contents. Less than 30 documented cases of mesenteric lipomatosis has been revealed. Mesenteric lipomas may cause pain by complete obstruction as result of torsion or volvulus^{3,4,5} or partial intestinal obstruction.

In the present report, we describe a case of mesenteric lipomatosis with associated ileal gastrointestinal stromal tumour presenting as multiple mass per abdomen.

CASE REPORT

A 65 years old male presented with mobile mass in the upper abdomen which the patient noticed 6 months ago. Patient also had pain in the upper abdomen of vague aching nature without aggravating or relieving factors. History of decreased appetite noted.

Bowel and bladder habits were normal. No history of vomiting, abdominal distension, constipation, hematemesis, melena. His personal, past, medical and family history were insignificant.

Examination of Patient revealed slightly distended abdomen with fullness over the epigastric and part of umbilical region.

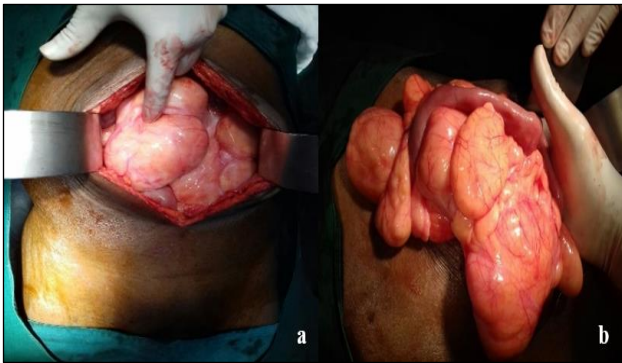


Figure 1: Exploratory laparotomy and multiple mesenteric lipoma noted with mass effect on the intestines.

On Palpation there was a mass in the epigastric region measuring about 7x5cm, with well-defined borders, firm in consistency, freely mobile in the horizontal axis than in the vertical axis, surface was smooth.

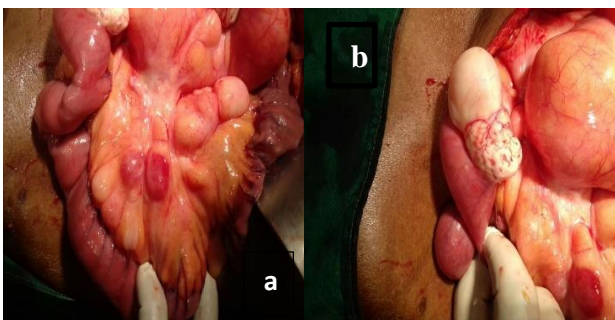


Figure 2: GIST arising from the distal end of the ileum which presented as mass in the right iliac fossa with areas of calcification has an extraluminal growth.

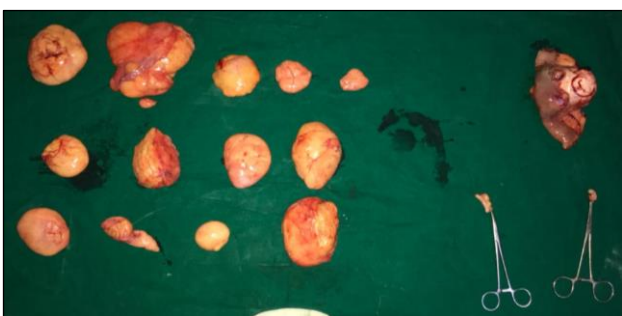


Figure 3: Multiple excised mesenteric lipoma with excised portion of the GIST along with the adjacent jejunum.

Another separate mass in the right iliac fossa was palpable measuring 10x7cm with irregular borders and nodular surface, hard in consistency and with restricted

mobility. Remaining examination of the abdomen was unremarkable. No hepatosplenomegaly, no evidence of free fluid in the abdomen. All the blood investigations were normal.

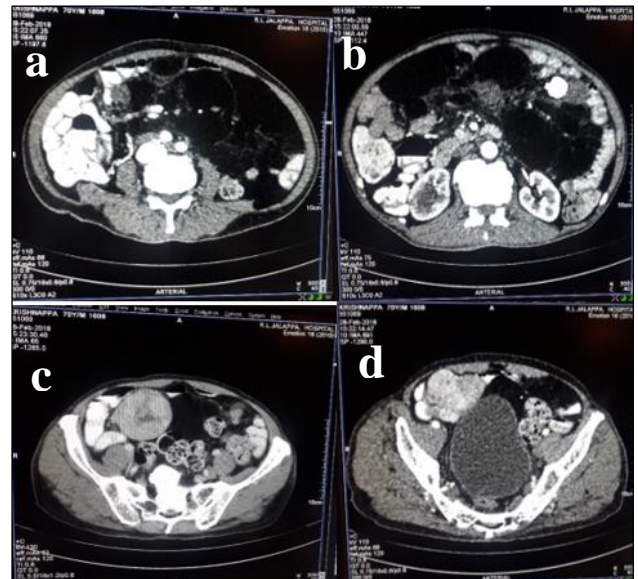


Figure 4: Large predominant fat attenuation lesion epic entered in left abdomen, probably originating from peritoneum with multiple septations causing mass effect on the small bowel, pancreas, descending colon and transverse colon, which are pushed to the peripheries: suggestive of peritoneal/ retroperitoneal liposarcoma.

Computed tomography revealed large predominant fat attenuation lesion epic entered in left abdomen, probably originating from peritoneum with multiple septations causing mass effect on the small bowel, descending colon and transverse colon, which are pushed to the peripheries, suggestive of peritoneal/ retroperitoneal liposarcoma.

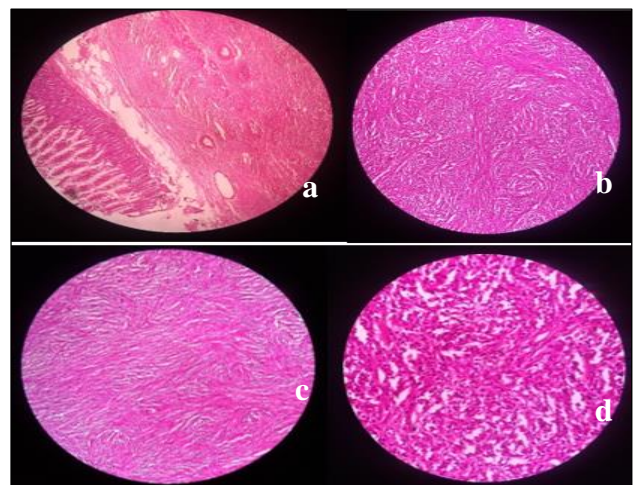


Figure 5: Histopathology of resected right iliac fossa mass: Gastrointestinal stromal tumour from the resected ileal segment.

USG guided FNAC from upper abdominal mass consists of mature fat cells, and FNAC from the mass in the right iliac fossa suggestive of gastrointestinal stromal tumour. Patient underwent exploratory laparotomy with excision of multiple mesenteric lipomas. The gastrointestinal stromal tumour causing the mass effect in the right iliac fossa was arising from the distal ileum.

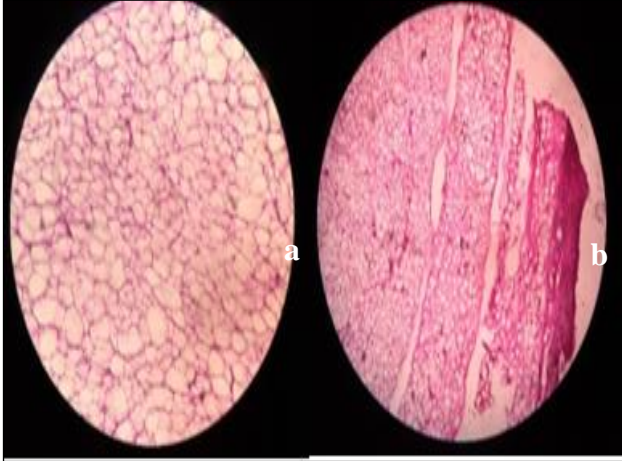


Figure 6: Histopathology of lipoma: Mature adipocytes arranged in clusters, capsule of the lipoma.

The tumour along with the involved segments were resected and end to end anastomosis done. There was no evidence of mesenteric lymphadenopathy or free fluid. Post-operative period was uneventful. Patient recovered well and was discharged after 3 weeks. Patient was started on Tablet Imatinib mesylate 400mg Once Daily and followed up regularly every month.

DISCUSSION

The incidence of lipoma is unknown; however, it is far higher than reported due to their salient features. Lipomas may show familial tendency and an increased incidence in people who are obese, having diabetes mellitus or hypercholesterolemia, however these are not applicable to other patients.¹

They are generally slow growing, lobulated, soft mobile mass which doesn't penetrate into the surrounding structures.^{1,2} Concurrent occurrence of gastrointestinal stromal tumour which arises from the mesenchymal components of the gastric and small bowel mucosa is a rarity. Their presentation can vary from anorexia, abdominal distension, weight loss, abdominal pain, constipation and a sensation of fullness after meal or as an abdominal mass as in our case. Initial Routine blood investigations were normal. Computed tomography revealed large predominant fat attenuation lesion entered in left abdomen, probably originating from peritoneum with multiple septations causing mass effect on the small bowel, pancreas, descending colon and transverse colon which were pushed to the peripheries, suggestive of peritoneal/ retroperitoneal liposarcoma.

Mesenteric lipomas may pose diagnostic difficulties due to unavailability of abnormal laboratory findings. Deep lipomas are usually diagnosed only when the tumour grows very big or becomes symptomatic of its anatomical localization.⁶ and thus it is very essential to have a high index of suspicion considering the various manifestations of mesenteric lipoma and thus inappropriate management can be prevented.

By review of literature it can be noted that the incidence is equal in both the sexes and majority of the mesenteric lipomas arise from the mesentery of the ileum. The sequel of these lipomas can be complete intestinal obstruction due to intussusception. Malignant change of mesenteric lipoma to liposarcoma is virtually unknown. These benign lesions may grow to large proportions and numbers but have no propensity to mutate.^{7,8}

When indicating excision, the possibility of liposarcoma always needs to be considered. If possible complete surgical excision of the lesion should be performed. Thus, reducing the possibility of relapse. The recurrence rate of lipomas is less than 5% and is usually due to incomplete excision.^{9,10}

The radiological examination helps in the diagnosis and the definitive diagnostic procedure is a computer tomography, ultrasonography can detect the mesenteric lipoma as homogenous echogenic mass.

The definitive treatment of the mesenteric lipoma is not established. Resection of the lipoma with or without resection of the intestinal loop is the treatment of choice due to the risk of partial or complete intestinal obstruction.

Gastrointestinal stromal tumour can occur anywhere in the GI tract. They are sub mucosal lesions. About 50% to 75% of these originate in the stomach and about 20% in the small bowel, while unusual sites include the colon and Rectum. GIST occurs marginally frequent in males as compared to females, both in the fifth and sixth decades of life. There is no racial or geographical preponderance. Clinical presentation varies from an incidental radiological finding when a patient is investigated for other symptoms to cases of intestinal obstruction, upper or lower GI bleeding or melena, and also as an emergent idiopathic spontaneous intra-abdominal hemorrhage.

GIST can develop into a huge size before diagnosis and demonstrate considerable cystic change usually associated with a surrounding rim of the viable enhancing tumour. As reported in our case, some may present with a palpable abdominal mass.

The consensus guidelines for management of GIST by the ESMO (European Society of Medical Oncology) and ASCO (American Society of Clinical Oncology) groups are outlined as follows:

Small esophagogastric or duodenal nodules <2 cm are deemed as low risk and these patients need only follow-up, reserving excision for patients whose tumor increase in size or become symptomatic.

Standard approach for nodules >2 cm is excision biopsy. If larger and surgery is expected to involve multivisceral resection, multiple core needle biopsies are performed guided by ultrasonography or CT.

Guidelines indicate that radical surgical resection is the gold standard for localized primary GIST. Increasing cure rates, overall survival and progression-free survival should be the aim of all adjuvant therapy which should be reserved only for patients having significant prognostic indicators for disease recurrence.¹¹

CONCLUSION

Mesenteric lipoma is rare but should be considered as a differential. It has the tendency to grow to large proportions and numbers. They should be considered in the differential diagnosis of unusual abdominal pain and mass, the diagnosis is often missed due to their silent nature of presentation and absence of abnormal laboratory findings and its vague non-specific symptoms, excision of the lipoma with or without resection of the intestinal loop may be considered if intestinal symptoms are present. Surgical procedure and imatinib shape the primary-line remedy and their effectiveness for the majority of sufferers has been progressive.

Personalizing the treatment of GISTs and tailoring remedies to tumour genotype will prevent emergence of resistance and is essential to optimize patient consequences.

Funding: No funding sources

Conflict of interest: None declared

Ethical approval: Not required

REFERENCES

1. Ilhan H, Tokar B, İşiksoy S, Koku N, Pasaoglu O. Giant mesenteric lipoma. J Pediatr Surg. 1999;34:639-40.

2. Prando A, Wallace S, Marins JL, Pereira RM, de Oliveira ER, Alvarenga M. Sonographic features of benign intraperitoneal lipomatous tumor in children: report of 4 cases. Pediatr Radiol. 1990;20:571-4.
3. Takagi Y, Yasuda K, Nakada T, Abe T, Saji S. Small bowel volvulus caused by a lipoma of the mesentery showing a distinct pattern on preoperative computed tomography. Dis Colon Rectum. 1998;41:122-3.
4. Sheen AJ, Drake I, George PP. A small bowel volvulus caused by a mesenteric lipoma: report of a case. Surg Today. 2003;33:617-9.
5. Wong HI, Chen CY, Liu GC. Primary mesenteric lipoma causing closed loop bowel obstruction: a case report. Kaohsiung J Med Sci. 2005;21:138-41.
6. Ilhan H, Tokar B, İşiksoy S, Koku N, Pasaoglu O. Giant mesenteric lipoma. J Pediatr Surg. 1999;34:639-40.
7. Lucas DR, Nascimento AG, Sanjay BK, Rock MG. Well-differentiated liposarcoma. The Mayo Clinic experience with 58 cases. Am J Clin Pathol. 1994;102:677-83.
8. Munk PL, Lee MJ, Janzen DL. Lipoma and liposarcoma: evaluation using CT and MR imaging. AJR Am J Roentgenol. 1997;169:589-94.
9. Livne PM, Zer M, Shmutter Z, Dintsman M. Acute intestinal obstruction caused by necrotic mesenteric lipoma: a case report. Am J Proctol Gastroenterol Colon Rectal Surg. 1981;32:19-22.
10. Tani T, Abe H, Tsukada H, Kodama M. Lipomatosis of the ileum with volvulus: report of a case. Surg Today. 1998;28:640-2.
11. Casali PG, Blay JY; ESMO/CONTICANET/EUROBONET Consensus Panel of Experts. Gastrointestinal stromal tumours: ESMO Clinical Practice Guidelines for diagnosis, treatment and follow-up. Ann Oncol 2010;21(5):98-102.

Cite this article as: Suma S, Shashirekha CA, Ravikiran HR, Vikranth SN. Mesenteric lipomatosis presenting as abdominal mass with concurrent ileal gastrointestinal stromal tumour (GIST): an unusual presentation. Int Surg J 2018;5:3414-7.