

Original Research Article

A prospective and retrospective study of Stoppa procedure (giant prosthetic reinforcement of visceral sac) for recurrent, complex and bilateral inguinal hernias

Mahim Koshariya*, Rakesh Pandey

Department of Surgery, Gandhi Medical College and Hamidia Hospital, Bhopal, Madhya Pradesh, India

Received: 23 July 2018

Accepted: 26 July 2018

***Correspondence:**

Dr. Mahim Koshariya,

E-mail: mahimk2000@yahoo.co.uk

Copyright: © the author(s), publisher and licensee Medip Academy. This is an open-access article distributed under the terms of the Creative Commons Attribution Non-Commercial License, which permits unrestricted non-commercial use, distribution, and reproduction in any medium, provided the original work is properly cited.

ABSTRACT

Background: Managing complex inguinal hernia is always a challenge for surgeons. When recurrent or complex hernia is present it is mandatory to adopt an alternative and different approach for the repair of inguinal hernia to avoid any further complication and recurrence. Primary aim of this study is to assess the usefulness of Stoppa procedure in current situation for treatment of bilateral, complex and recurrent hernias.

Methods: A prospective and retrospective study of Stoppa procedure (giant prosthetic reinforcement of visceral sac [GPRVS]) for recurrent, complex and bilateral inguinal hernias was conducted in Department of General Surgery Hamidia Hospital from January 2016 to October 2017, 30 patients with 27 bilateral and 3 unilateral hernias making total 57 hernial sites including five recurrent hernias (after Lichtenstein repair) were operated by GPRVS for bilateral, recurrent and complex inguinal hernias, were included in study.

Results: Four complications were seen. One patient developed seroma which resolved spontaneously, one patient developed superficial wound infection. One patient developed right testicular pain which was relieved after medication. One patient developed pain in groin and right thigh which was present preoperatively also but increased after surgery and was relieved on medication. Risk for recurrence present in 18 patients. No recurrence was observed.

Conclusions: Because of the excellent results, ease of the procedure and low complication rate, GPRVS is an effective and good option for bilateral, complex and recurrent inguinal hernias.

Keywords: Complex inguinal hernia, Stoppa's procedure (GPRVS)

INTRODUCTION

Hernias of the abdominal wall constitute an important public health problem and often pose a surgical dilemma even for the most skilled surgeons. High incidence of the disease makes inguinal hernia repair the most frequent procedure in general surgery, accounting for 10-15% of all operations.¹ Traditional suture repair techniques has been taken over by tension free mesh repair making mesh repair more common than suture repair now a days. Common tension free surgical techniques currently used in open inguinal hernia repair fall into two categories

with regard to placement of mesh in relation to the transversalis fascia: anterior (e.g. Lichtenstien technique) and posterior with mesh placed behind the transverse fascia utilizing Nyhus, Stoppa, Rives and Read procedures.

Complex and recurrent inguinal hernia have a high risk of recurrence. Managing complex inguinal hernia is always a challenge for treating surgeon. When recurrent or complex hernia is present it is mandatory to adopt or choose an alternative and different approach for the repair of inguinal hernia to avoid any further complication and

recurrence in future thereby avoiding any further hampering quality of life of the patient. If anterior repair is used for recurrences, it requires extensive dissection, uses scarred and devascularized tissue under tension for the repair and often enlarges already large defect. The basic reason for poor results of primary and recurrent hernias is the approximation of tissues under tension.^{2,3}

Stoppa et al described a technique aimed at eliminating hernias of the groin by reinforcement of peritoneum with a giant polyester mesh. With this giant prosthetic reinforcement of the visceral sac (GPRVS), mesh acts as an artificial endoabdominal fascia and Stoppa groin hernia repair prevents visceral sac extension through the myopectineal orifice where all groin hernias begin.

Adequate space and visibility for safe performance of surgical maneuvers and access to neighboring spaces of Retzius and Bogros, which are excellent sites for placement of large mesh prosthesis between the peritoneum and the abdominal wall. Especially in complex recurrent hernias previously operated by an anterior approach, the preperitoneal route is most convenient for surgical procedure and much easier than the anterior approach for placement of preperitoneal mesh. There are various preperitoneal approaches described and practiced like open approach: Nyhus and Stoppa, Laparoscopic approach: TAPP and TEP.

Keeping this in mind present study was undertaken for treating recurrent, complex and bilateral hernia by GPRVS as described by Rene Stoppa with little modification to treat and evaluate the usefulness, safety and outcome of this procedure. The focus of our study is to do outcome analysis of GPRVS in recurrent, complex and bilateral hernias.

METHODS

This was observational study. Total 30 patients (27 bilateral and 3 unilateral hernias) with 57 hernial sites repaired with Stoppa procedure were included in study. Postoperatively patients were observed for any complications and were followed up in OPD after discharge. Thorough examination was done on follow-up to detect any complication. Retrospective patients were traced through Hospital records and patients who came for follow-up in OPD were included in study. Visual analogue scale was used for assessment of severity of pain.

Inclusion criteria

- Clinical diagnosis of bilateral, recurrent or complex hernia willing for admission
- Age > 20 years.

Exclusion criteria

- Strangulated hernias/obstructed hernias

- Patients unfit for surgery
- Patients with previous midline scar for any other abdominal surgeries
- Patients with retroperitoneal malignancy or carcinoma of prostate.

Procedure

Anaesthesia

29 patients were operated under spinal anesthesia, and 1 patient was operated under general anesthesia.

Preoperative preparation

All the patients were catheterised prior to surgery.

Steps of surgery

IV antibiotic (1-gram ceftriaxone) was given to all patients before incision, which was continued post operatively. Painting and draping were done. In the present study, Stoppa procedure was used with slight modifications.

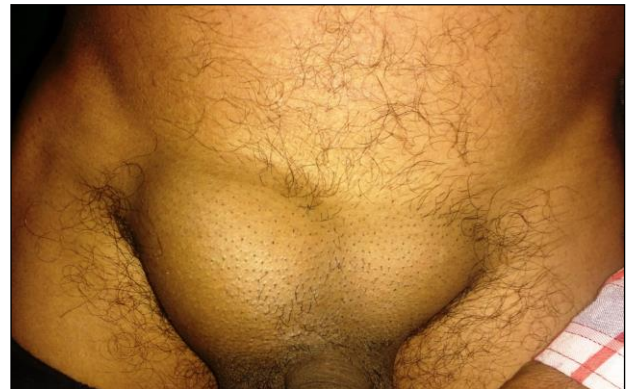

Figure 1: Preoperative pictures of bilateral inguinal hernia.

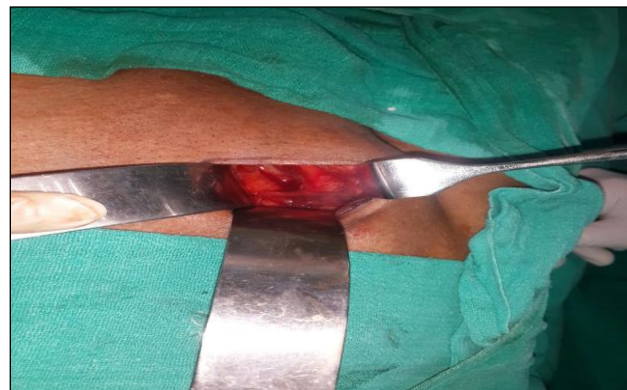

Figure 2: Entry into space of retzius.

A lower midline or Pfannenstiel incision was used in all cases, which extend from the midline 2.5-3.5 cm in each

direction laterally in midline infraumbilical incision of approximately 8 cm was used. The anterior rectus sheath and the oblique muscles were incised for the length of the skin incision. The lower flap of these structures was retracted inferiorly toward the pubis. The preperitoneal space was entered by incising the fascia transversalis along the lateral edge of the rectus muscle or by incising the fascia overlying the space of Retzius (Figure 2).

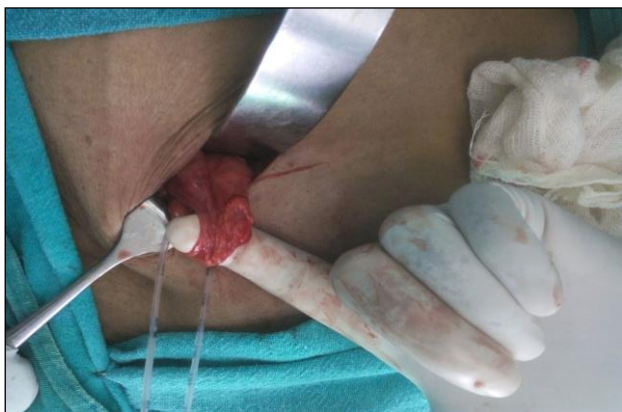

Figure 3: Picture showing cord structures with hernial sac.

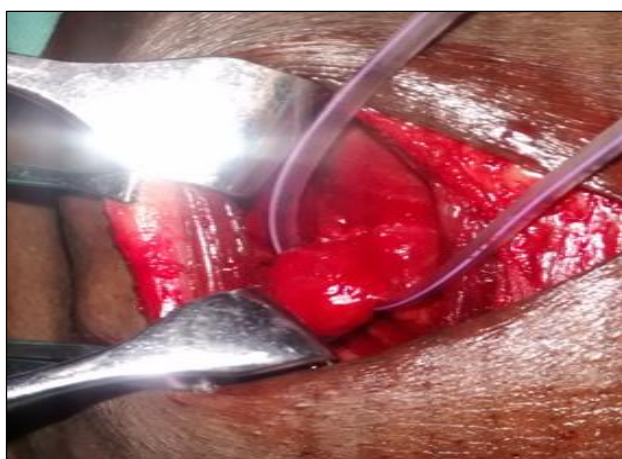

Figure 4: Picture showing indirect hernial sac.

The preperitoneal space was completely dissected to a point lateral to the anterior superior iliac spine. The symphysis pubis, Cooper's ligament, and iliopubic tract were identified. The spermatic cord was "parietalized" (completely dissected) at least 4 cm to provide adequate length to displace it laterally. Direct sacs were reduced in the course of this dissection. Indirect sacs were mobilized from the cord structures and reduced back into the peritoneal cavity (Figure 4). Large sacs which were difficult to mobilize were divided so that the distal part of the sac was left in situ and the proximal portion of the sac was dissected away from the cord structures carefully to avoid damage to the testicular vessels. Any accidental opening of peritoneum was closed with vicryl 3-0 RB.

Dissection was preceded in the relatively avascular plane between the fascia transversalis and the peritoneum to avoid a bloody procedure.

Abdominal wall defect, if small was left alone, but if large, was closed plicating the fascia transversalis in the defect by suturing it to Cooper's ligament to prevent a bulge caused by a seroma in the undisturbed sac.

In the present study 15 × 15 cm ULTRAPRO partially absorbable light weight mesh was used in all cases without splitting. Minimizing fixation in this area is important because of the numerous anatomic elements in the preperitoneal space that could be inadvertently damaged during suture or tack placement. Two to three non-absorbable sutures (prolene 2-0 RB) were used to attach the prosthesis to the anterior abdominal wall on 2 or 3 points that is transverse aponeurotic arch, coopers ligament and medial fibrous tissues of rectus.

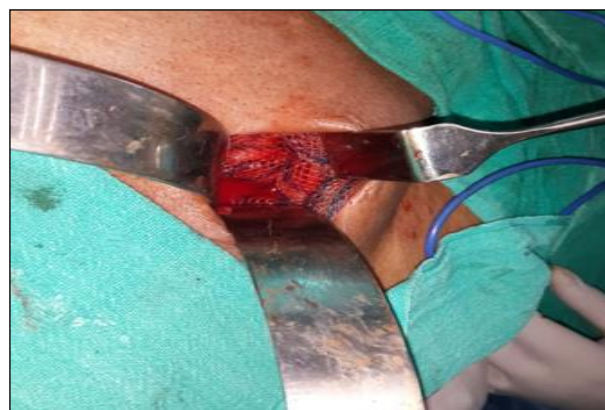

Figure 5: Picture showing mesh after spread

The mesh is positioned to cover the iliac fossa and the parietalized cord structures and iliopsoas muscle laterally; the pubic ramus, obturator fossa, and iliac vessels medially; and the space of Retzius in the middle. The size of the mesh for the Stoppa technique to repair bilateral hernias is the distance between the two anterior superior iliac spines minus 2 cm for the width, and the height is equal to the distance between the umbilicus and the pubis. In our study we used two mesh of 15×15 cm one on each side with overlapping at centre in bilateral hernias (Figure 5) and 15×15 cm single mesh in unilateral hernia. Now surgeon and assistant changed their position and opposite side hernia repaired in similar way. Drain was kept if required. The wound is closed in layers.

RESULTS

The present study was carried out in the Department of General Surgery and Hamidia Hospital and following observations were made: Age group in this study was from 24 to 70 years with most of the patients being 60-69 years in age and mean age 55.3 years (Table 1).

Table 1: Age wise distribution of direct and indirect hernias.

Age group (years)	Total no. of patients	No. of patients with bilateral hernias	Both direct	Both indirect	Right direct left indirect	Right indirect left direct	Unilateral hernia	No. of hernias
20-29	01	01	00	00	00	01	00	02
30-39	02	02	00	02	00	00	00	04
40-49	05	05	03	00	01	01	00	10
50-59	08	07	01	01	03	02	01 (direct)	15
60-69	10	08	04	02	01	01	02 (1 direct, 1 indirect)	18
70-79	04	04	01	01	00	02	00	08
Total	30	27	09	06	05	07	03	57

Table 2: Frequency of different types of hernias.

	Both direct	Both indirect	Right direct left indirect	Left direct right indirect	Right direct	Right indirect	Total left	Total right
Number	09	06	05	07	02	01	27	30

There were 30 patients operated with 27 bilateral inguinal hernias and three unilateral hernias (Table 1). There were two recurrent hernias of one side with primary hernia on opposite site amongst bilateral hernias and three recurrent unilateral hernias.

Total no of hernia repaired was 57 (27 patients with bilateral hernias making 54 hernia repairs and 3 patients of unilateral recurrent hernias) as shown in Table 1. There were total 5 recurrent hernias, 2 were bilateral hernias with recurrent inguinal hernia on one side with primary hernia on opposite side, and three were unilateral recurrent inguinal hernias. Out of 57 hernial sites total right sided hernia were 30 and 27 were left sided (Table 2). There were total 25 indirect hernias (43.8%) and 32 direct hernias (56.1%) (Table 3).

Table 3: Frequency of total direct and indirect hernias.

	Total direct inguinal hernia	Total indirect inguinal hernia
Number	32	25

Post-operative pain was maximum in 3rd post-operative day as measured by Visual Analogue Scale, which was decreasing after 3rd day (Table 4).

Table 4: Post-operative pain in initial 5 days after Stoppa procedure.

Post op day	1st	2nd	3rd	4th	5th
Average Pain score (as per VAS)	2.2	2.6	3.2	3	2

Operating time was from 45 minutes to 120 minutes with mean operating time 70 minutes as shown in Table 5.

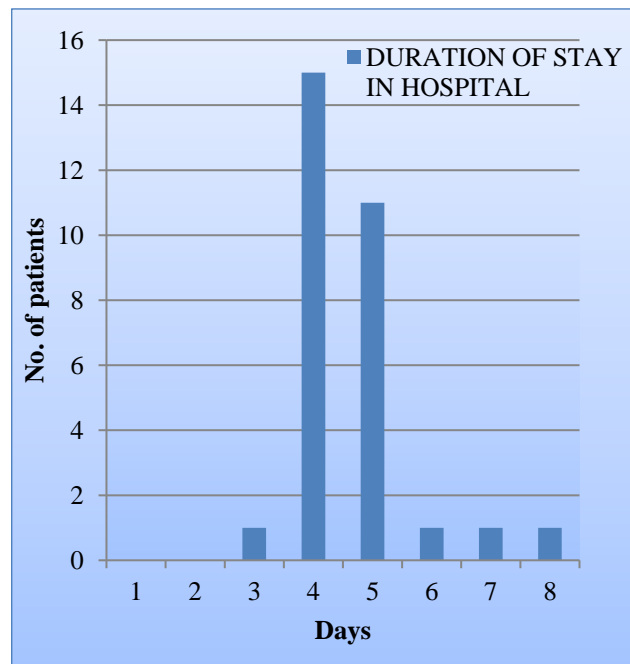


Figure 6: Postoperative hospital stay after Stoppa procedure.

Risk factor for recurrence was present in 18 patients three patients had BPH, three had history of pulmonary disease, 12 patients had size of defect more than 5 cm.

Table 5: Operative time in patients.

Operative time (in minutes)	No. of patients
45-59	11
60-74	07
75-99	09
100-120	04

Five patients had recurrent hernia. Average duration of stay in hospital postoperatively was 4.63 days.

Table 6: Post-operative complications seen after surgery.

Post operative complications	No. of patients
Seroma	1
Superficial wound infection	1
Testicular pain	1
Pain in groin and thigh	1

Complications

- Seroma formation occurred in one patient post operatively which resolved by itself.
- Testicular pain was noted in one patient which was mild (VAS score 2.5), relieved on medication.
- Wound infection was noted in one patient who

required readmission and then infection resolved.

- Pain in groin and thigh was noted in one patient which was present preoperatively too but increased after surgery (VAS Score 2) and was relieved by medication.
- No recurrence was seen.

DISCUSSION

The Stoppa repair is a tension free of hernia repair, also known as Giant prosthetic reinforcement of the visceral sac (GPRVS) was first described in 1975 by Rene Stoppa.⁴ His technique has met particular success in the repair of bilateral, large scrotal hernias and recurrent or rerecurrent hernias in which conventional repair is difficult and carries high morbidity and failure rate.⁵ The totally extraperitoneal repair (TEP) uses exactly the same principles as the Stoppa repair.⁶

Table 7: Comparison of the present study to other similar studies.

	Present study (Koshariya M, Pandey R)	Thapar VV, Rao PP, Prabhu RR ¹⁷	Hemmat Maghsoudi, Ali pourzand ¹⁸
No. of subjects	30 (27 bilateral hernias, 3 unilateral hernias)	31 (All bilateral hernias)	234 (186 bilateral, 48 unilateral hernias)
Duration of study	1 year (January 2016 to October 2017)	1 year (December 97 to December 98)	8 years (March 93 to March 2003)
Study centre	G.M.C. Bhopal	Seth G. S. Medical College, Mumbai	Tabriz University of Medical Sciences, Iran
No of hernias repaired	57	62	420
Mean age	55.03 years	58 years	60 years
Range	24-70 years	49-95 years	25-88 years
General anesthesia	1	5	51
Spinal anesthesia	29	26	183
Recurrent hernias	5	14	177
Medical Problems:			
BPH	3		20
Pulmonary	3	8	20
>5Cm size	12	10	80
Mean operative time	70 minutes (45-120 minutes)	65±11 min (45-115 min)	45 min (30-75 min)
Mesh used	Polypropylene	polypropylene	Polyester
Mean hospital stay postoperatively	4.63 days (3-8 days)	3.5±0.7 days (2-5 days)	2.2 days (1-13 days)
Seroma formation	1	0	3
Superficial wound infection	1	2	0
Mesh infection	0	0	0
Urinary retention	0	1	0
Thrombophlebitis	0	1	0
Testicular pain	1	0	0
Groin pain	1	0	0
Recurrence	0	0	3

Stoppa procedure provides good results in hernia repairs as there is minimum chance of recurrence as compared to any other procedure and it does not require long training time unlike laparoscopic hernia repair. It is much cost effective and can be done in patients who can't tolerate general anaesthesia. Preperitoneal approach is especially useful in complex recurrent hernia, previously operated by anterior approach.

Large size mesh is kept which covers all the potential abdominal wall hernia sites. It is estimated that 10 and 30% of primary inguinal hernias repaired do recur, yet specialized hernia centers report recurrence rate of less than 1% in primary inguinal hernia repairs.

This is because of short duration of follow-up. The longer and more complete the follow-up, the higher the recurrence rate. Most of the recurrences occur in first 3 years also called early recurrence is thought to be mainly due to failure on part of surgeon and to infection. The smaller late group failure occurs due to tissue failure. Recurrence rate in our study was found to be 0% which is consistent with previous studies. In most of studies recurrence rate is <2% in short term. Mean follow-up in the present study was 16.23 months with range 2 months to 4 years. Table 8 shows comparison between studies done in past regarding the recurrence rate in GPRVS.

Table 8: Comparison between studies done in past regarding the recurrence rate in GPRVS.

Author	No. of hernias operated on	Follow-up duration (years)	Recurrence rate (%)
Blondiaux (in stoppa) ⁷	91	0.5-3.5	0
Detrie (in stoppa) ⁸	50	0.5-4	0
Stoppa ⁹	529	1-12	1.1
Stoppa ¹⁰	285	1-10	1.2
Mathonnet ¹¹	198	2-6	1.6
Champault ¹²	49	3	2
De st julien (in Salinier) ¹³	309	0.5-6	2.9
Stoppa ¹⁴	168	1-7	3.3
Wantz ¹⁵	358		4.5
Rignault ¹⁶	658	4	4.6

In the present study, no major complications were noted, only 4 minor complications were noted one patient had seroma formation which resolved by self, one had right testicular pain which was persistent till 2 months after surgery, relieved on simple medication (NSAID), one patient had pain in groin and thigh region which was present preoperatively also but increased after surgery and was relieved on medication. One patient developed superficial wound infection, for which readmission and antibiotics were given and then patient was discharged successfully without any deep infection after 8 days.

In study done by Thapar et al, 4 minor complications were noted (2 wound infection, 1 urinary retention and 1 seroma formation).¹⁷ In study done by Maghsoudi H and Pourzand there was GI bleeding in one patient, ileus in one patient and atelectasis in one patient, which were not related to hernia surgery, there was seroma formation in 3 patients and recurrence developed in 3 patients (0.71%).¹⁸

From above comparison it is clear that in the present study also there were only minor complications, no major complications. With increasing use of laparoscopy use of stoppa procedure is decreasing but it is easier technique especially in patients with large complex hernias where adhesions and large size are present.

Due to its simplicity and good results in recurrent, complex and bilateral hernias this technique can't be replaced but its indications are limited.

CONCLUSION

In the era of laparoscopy, laparoscopic hernia repair is gaining popularity with its proven evidence. Laparoscopic approach is difficult to learn, costly and has longer learning curve, whereas Stoppa preperitoneal mesh repair meets the criteria of tension free anatomical repair, is simple, easy to perform, smaller learning curve with lesser complications. It is also cost effective with good results. With our short experience and available data it can be concluded that Stoppa procedure is effective solution for the difficult, complex, unilateral and bilateral hernias.

Funding: No funding sources

Conflict of interest: None declared

Ethical approval: The study was approved by the Institutional Ethics Committee

REFERENCES

1. Rutkow I. Epidemiologic, economic and sociologic aspects of hernia surgery in the united states in the 1990s. *Surg Clin North Am.* 1998;78:941-51.
2. Shulman AG, Amid PK, Lichenstein IL. The plug repair of 1402 recurrent inguinal hernias 20-year experience. *Arch Surg.* 1990;125:265-7.
3. Abrahamson J. Hernias. In: Zinner MJ, ed. *Manningot's abdominal operations.* 10th edition. Stamford: Appleton and Lange; 1997:479-580.
4. Stoppa R, Petit J, Henry X. Unsutured Dacron prosthesis in groin hernias. *Int Surg.* 1975;60(8):411-2.
5. Lowham A, Filipi C, Fitzgibbons R, Stoppa R, Wantz G, Felix E, et al. Mechanisms of hernia recurrence after preperitoneal mesh repair. Traditional and laparoscopic. *Ann Surg.* 1997;225(4):422-31.
6. Beets G, Dirksen C, Go P, Geisler F, Baeten C, Kootstra G. Open or laparoscopic preperitoneal mesh repair for recurrent inguinal hernia? A

- randomized controlled trial. *Surg Endosc.* 1999;13(4):323-7.
7. Stoppa R. The giant prosthesis for the reinforcement of visceral sac in the repair of groin and incisional hernias. In: Nyhus LM, Baker RJ, Fischer JE. (Eds). *Mastery of surgery.* 3rd ed. Boston: Little Brown; 1997:1859-1869.
 8. Stoppa R. The preperitoneal approach and prosthetic repair of Groin hernias. In: Nyhus LM, Codon RE (eds): *Hernia,* 4th ed. Philadelphia: JB Lipincott; 1995:188-206.
 9. Stoppa RE, Warloulmont CR. The midline preperitoneal approach and the prosthetic repair of groin hernia. In: Nyhus LM, Baker RJ (eds): *Mastery of surgery.* 2nd ed. Boston: Little brown; 1992.
 10. Stoppa RE, Rives JL, Warlaumont CR. The use of Dacron in repair of hernias in groin. *Surg Clin North Am.* 1984;64:269.
 11. Mathonnet M, Cubertafond P, Gainant A. Bilateral inguinal hernias: giant prosthetic reinforcement of visceral sac. *Hernia.* 1997;1(2):93-6.
 12. Champault G, Rizk N, Catheline JM. Hernias of the year. Preperitoneal laproscopic treatment versus stoppa surgery. *Etude randomisee :100 cases.* *J Chir.* 1966;133(6):274-80.
 13. Salinier L. Comparative study of the treatment of inguinal herne by prosthesis. About 309 observations. *These Med Bordeaux.* 1983;II(233).
 14. Stoppa R, Houdard C. Surgical treatment of heroines of the elderly. *Monograph of the French Association of Surgery.* Paris: Masson; 1984:74.
 15. Wanz GE. Personal experience with Stoppa technique. In: Nyhus LM, Condon RE (eds): *Hernia* 4th ed. Philadelphia J.B. Lippincott; 1995:206-210.
 16. Rignault D, Dubois C, Andre H. Inguinal hernioplasty with prosthetic interposition. *Surg.* 1983;109(10):841.
 17. Thapar VV, Rao PP, Prabhu RR, Desai CC, Singh AS, Supe AN. Giant prosthesis for reinforcement of visceral sac for complex, bilateral and recurrent Hernias: a prospective evaluation. *J Postgrad Med.* 2000;46(2):80.
 18. Maghsoudi H, Pourzand A. Giant prosthetic reinforcement of the visceral sac: the Stoppa groin hernia repair in 234 patients. *Ann Saudi Med.* 2005;25(3):228-32.

Cite this article as: Koshariya M, Pandey R. A prospective and retrospective study of Stoppa procedure (giant prosthetic reinforcement of visceral sac) for recurrent, complex and bilateral inguinal hernias. *Int Surg J* 2018;5:3023-9.